

DOI: <https://doi.org/10.17816/vto159380>

Применение индивидуального вертлужного компонента при дефекте вертлужной впадины: клинический случай

О.А. Алексанян, Г.А. Чрагян, С.В. Каграманов, Р.А. Ханмурадов, Н.В. Загородний

Национальный медицинский исследовательский центр травматологии и ортопедии им. Н.Н. Приорова, Москва, Российская Федерация

АННОТАЦИЯ

Введение. Число тотальных замещений тазобедренного сустава растёт с каждым годом. Чаще встречаются дефекты вертлужной впадины, при этом дефекты типа IIIA по Paprosky и выше становятся всё более распространёнными. В последние годы для реконструкции тяжёлых дефектов применяются индивидуальные конструкции, созданные с помощью 3D-печати. На этом клиническом примере показана возможность лечения пациентки с тяжёлым дефектом вертлужной впадины путём проведения одноэтапного ревизионного эндопротезирования с использованием индивидуальной конструкции.

Описание клинического случая. Пациентке 69 лет по поводу коксартроза в 2010 г. выполнено первичное тотальное эндопротезирование правого тазобедренного сустава эндопротезом компании Biomet. В 2011 г. — слева эндопротезом фирмы Zimmer. В 2013 г. — ревизионное эндопротезирование правого тазобедренного сустава по поводу нестабильности. В послеоперационном периоде отмечались неоднократные вывихи с последующими закрытыми вправлениями. В 2015 г. по поводу рецидивирующего вывиха выполнено ревизионное эндопротезирование с установкой антипрофузионного кольца Бурх–Шнайдера. В ноябре 2017 г. выявлена нестабильность тотального эндопротеза правого тазобедренного сустава, по поводу чего выполнено ревизионное эндопротезирование с применением индивидуального вертлужного компонента.

Показатель NHS до ревизионного эндопротезирования составил 18 баллов, через 1 мес после операции — 75 баллов, через 3 мес — 65, через 6 мес — 82, через 4 года — 74. Качество жизни оценивали по шкале WOMAC: до операции — 92 балла, через 1 мес после операции — 38 баллов, через 3 мес — 31, через 6 мес — 15, через 4 года — 35 баллов. На момент последней консультации пациентка передвигается с тростью, сохраняется хромота, связанная с рубцовой перестройкой и атрофией ягодичных мышц.

Заключение. При выраженных дефектах вертлужной впадины применение индивидуальных компонентов позволяет достичь надёжной фиксации «имплантат–кость», что приводит к улучшению функциональных результатов. Однако при хроническом нарушении целостности тазовой кости применение индивидуального вертлужного компонента не всегда позволяет достичь надёжной стабилизации. Все существующие методы для решения данной проблемы на сегодняшний день являются неоднозначными и требуют дальнейшего совершенствования.

Ключевые слова: тазобедренный сустав; ревизионное эндопротезирование; индивидуальная конструкция.

Как цитировать:

Алексанян О.А., Чрагян Г.А., Каграманов С.В., Ханмурадов Р.А., Загородний Н.В. Применение индивидуального вертлужного компонента при дефекте вертлужной впадины: клинический случай // Вестник травматологии и ортопедии им. Н.Н. Приорова. 2023. Т. 30, № 2. С. 209–217. DOI: <https://doi.org/10.17816/vto159380>

DOI: <https://doi.org/10.17816/vto159380>

The use of an individual acetabular component for acetabular defect: a clinical case

Ovakim A. Aleksanyan, Gamlet A. Chragyan, Sergey V. Kagramanov,
Ruslan A. Khanmuradov, Nikolay V. Zagorodniy

Priorov National Medical Research Center of Traumatology and Orthopedics, Moscow, Russian Federation

ABSTRACT

BACKGROUND: The incidence of total hip replacements is increasing every year. Acetabular defects are becoming more frequent, with Paprosky type IIIA and above becoming more common. Recently, customized 3D-printed constructs have been used to remodel severe defects. We wanted to demonstrate the possibility of treating a patient with a severe acetabular defect by performing a one-stage revision endoprosthesis using a customized design.

CLINICAL CASES DESCRIPTION: A 69-year-old patient underwent primary total hip replacement of the right hip joint with a Biomet endoprosthesis for coxarthrosis in 2010. In 2011 — on the left side with a Zimmer endoprosthesis. In 2013 — revision endoprosthesis of the right hip joint due to instability was performed. In the postoperative period, there were repeated dislocations with subsequent closed repositioning. In 2015, revision endoprosthetic replacement with a Burkh-Schneider antiprotrusion ring was done for recurrent dislocation. In November 2017, she was diagnosed with instability of the right total hip joint, for which she underwent revision hip replacement with a customized acetabular component.

HHS score before revision arthroplasty was 18 points, 1 month after surgery — 75 points, after 3 months — 65, after 6 months — 82, after 4 years — 74. Quality of life was assessed using the WOMAC scale: 92 points before surgery, 38 points 1 month after surgery, 31 points in 3 months, 15 points in 6 months, and 35 points in 4 years. As of the last visit, the patient moves with a cane, and still has a limp due to scar remodeling and gluteal muscles atrophy.

CONCLUSION: In case of severe acetabular defects, the use of individual components allows achieving reliable "implant–bone" fixation, which leads to improved functional results. However, in chronic pelvic bone integrity defects, the use of an individual acetabular component does not always achieve reliable stabilization. All existing methods for solving this problem are currently ambiguous and require further improvement.

Keywords: hip joint; revision arthroplasty; individual design.

To cite this article:

Aleksanyan OA, Chragyan GA, Kagramanov SV, Khanmuradov RA, Zagorodniy NV. The use of an individual acetabular component for acetabular defect: a clinical case. *N.N. Priorov Journal of Traumatology and Orthopedics*. 2023;30(2):209–217. DOI: <https://doi.org/10.17816/vto159380>

BACKGROUND

The number of total hip replacements is increasing annually, and the number of revision hip replacements is expected to nearly double in the next 10 years [1]. In revision hip arthroplasty, the surgeon is more often confronted with acetabular defects, with Paprosky type \geq IIIA defects becoming more common. Thus, according to Christie et al., such defects account for 14% of revision cases [2]. Technologies for creating customized acetabular components have been steadily developing since the late 70s and now include computer-aided design and three-dimensional (3D) printing of implants using additive manufacturing technology [3]. Previously, 3D printing was only used to create models of the pelvis or implant, and the final implant was manufactured from forged titanium by milling.

Through a clinical example, we wanted to demonstrate the possibility of treating a patient with a severe acetabular defect with a one-stage revision endoprosthesis using a customized design.

CLINICAL CASE

A 69-year-old patient underwent primary total hip replacement of the right hip joint with a Biomet endoprosthesis for right-sided coxarthrosis in 2010. In 2011, a similar operation using a Zimmer endoprosthesis was performed for left-sided coxarthrosis. In 2012, pain in the right hip joint region appeared and began to progress. In 2013, a revision hip replacement of the right hip joint was performed for acetabular component instability. Postoperatively, the patient noted repeated dislocations of the head of the right hip joint endoprosthesis with subsequent closed repositioning. In 2015, a revision hip replacement with a Burkh–Schneider antiprotrusion ring was performed for recurrent dislocations of the head of the right hip joint. Eighteen months after surgery, pain in the operated joint recurred. In November 2017, the patient was admitted to the endoprosthesis department of the N.N. Priorov National Medical Research Center of Traumatology and Orthopedics. The assessment of the right hip joint function according to the Harris hip scale (HHS) was 18 points, the severity of pain syndrome according to the visual analog scale (VAS) was 74 points (for a more accurate assessment, the scale was measured in millimeters), and the patient's social adaptation according to the Western Ontario and McMaster Universities Osteoarthritis Index (WOMAC) scale was 92 points. Radiographs of the pelvic bones in a straight projection were obtained (Fig. 1).

For a more detailed visualization of the defect of the bones forming the acetabulum, multislice computed tomography (CT) with 3D reconstruction was performed (Fig. 2).

Given the severity of the acetabular defect and the extreme difficulty of reconstruction using standard components, a customized acetabular component was used. In collaboration with "Endoprint" engineers, a 3D model of the implant was

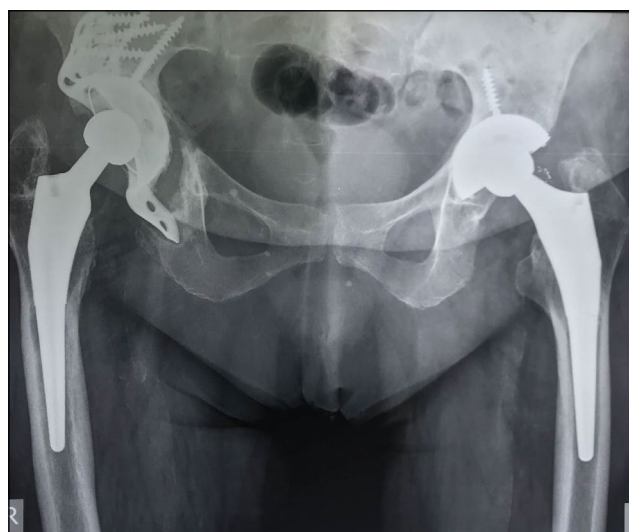


Fig. 1. Preoperative radiograph of a 69-year-old patient: type IIIB acetabular defect according to W.G. Paprosky.

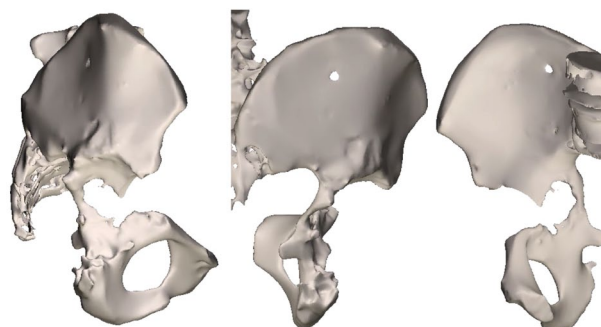


Fig. 2. 3D reconstruction of the right acetabulum by imaging using multislice computed tomography.

created in accordance with the bony defect of the acetabulum (Fig. 3).

The final digital model of the implant was printed on a 3D printer (Fig. 4), sterilized by autoclaving, and inserted (Fig. 5). The implant position was assessed on postoperative radiographs (Fig. 6). Postoperatively, the patient received symptomatic, anticoagulant, antibacterial, and rehabilitation therapy, and the wound healed with primary tension. The patient was discharged on day 7 after surgery.

Three months after surgery, the patient came for a follow-up examination. Radiographs showed migration of the sciatic and brow bones from the flanges of the construct (Fig. 7). The patient still had pain syndrome in the operated joint area, which was 28 (mm) points on the VAS scale. On the HHS scale, the hip joint function was assessed at 75 points. The social adaptation score on the WOMAC scale was 38 points. Considering the clinical and radiological picture, the patient was offered surgery for screw removal from the lower flanges and correction of the sciatic flange of individual design with a high-speed bur. The patient refused the proposed surgery.

Six months after surgery, no negative dynamics on control radiographs were observed. The HHS, WOMAC, and

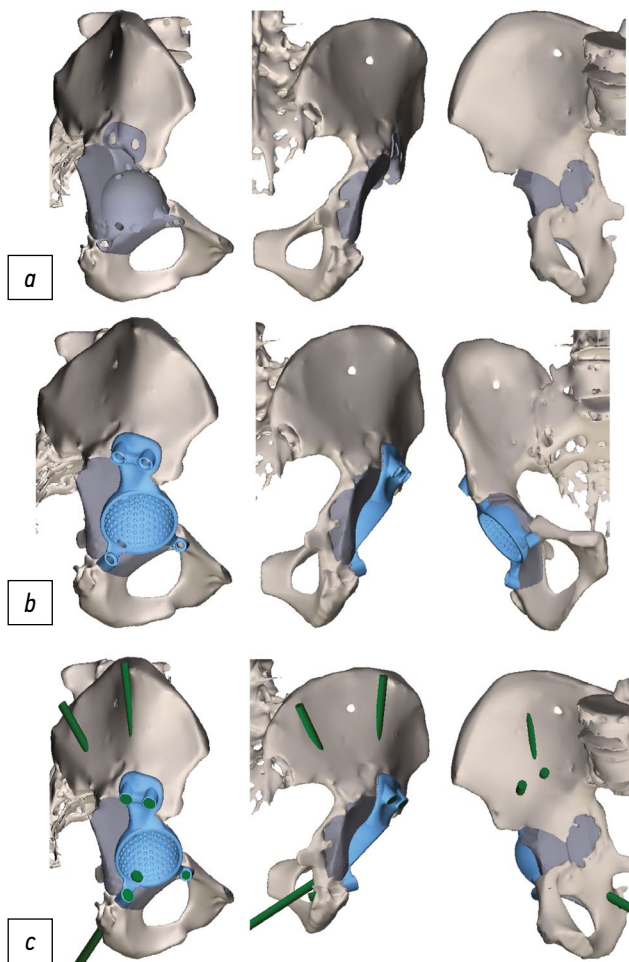


Fig. 3. 3D model of the implant: *a* — the porous part of the implant, which fills the structure of the bone defect; *b* — hemispherical part of the endoprosthesis with holes for screws; *c* — the direction of the screws, taking into account the density of the bone tissue.




Fig. 4. 3D model of the implant: *a* — the porous part of the implant, which fills the structure of the bone defect; *b* — hemispherical part of the endoprosthesis with holes for screws; *c* — the direction of the screws, taking into account the density of the bone tissue.

VAS scores were 82, 15, and 30 (mm) points, respectively. Despite a slight increase in the severity of pain syndrome according to the VAS score, the patient noted improvement in the bearing capacity and functional results of the operated limb. No significant changes in the evaluation scales were

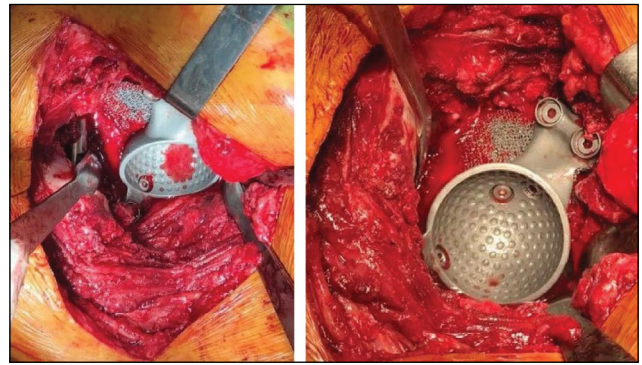


Fig. 5. Stage of implant placement.

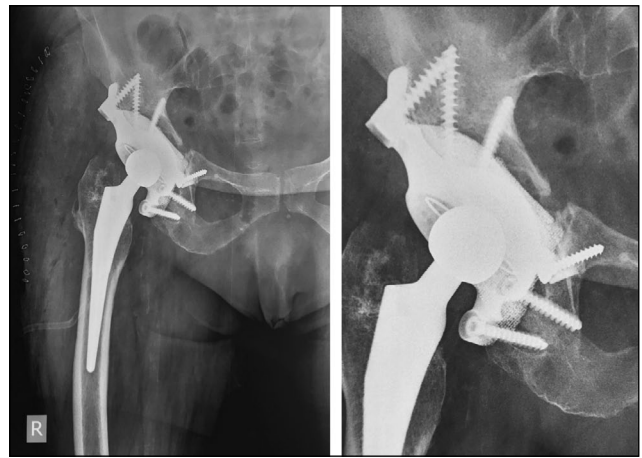


Fig. 6. Postoperative control X-ray.

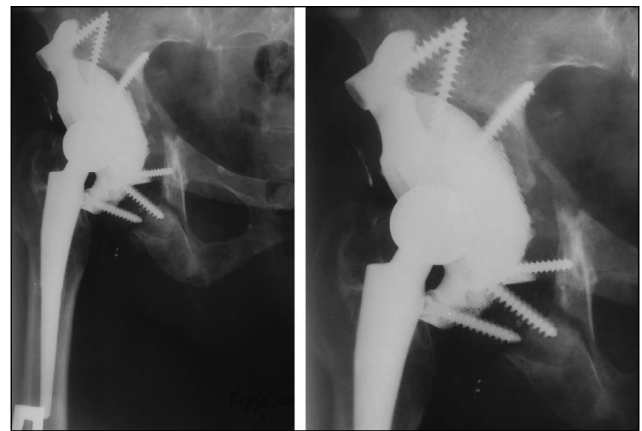


Fig. 7. Postoperative control X-ray after 3 months.

noted at the subsequent follow-up examinations (1 year after surgery and once a year thereafter). At the time of writing, >4 years have elapsed since the operation. Data obtained four years after surgery did not show negative dynamics on control radiographs (Fig. 8). The pain syndrome slightly increased and corresponds to 32 (mm) points on the VAS scale. On the HHS scale, the hip joint function corresponded to 74 points, and social adaptation according to the WOMAC scale corresponded to 35 points. The patient is under dynamic observation.

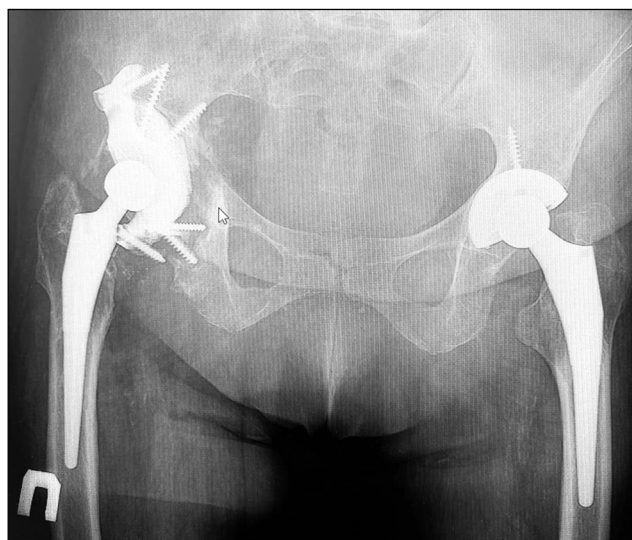

Fig. 8. Postoperative control X-ray 4 years after the operation.

DISCUSSION

The need for revision arthroplasty is increasing annually, and its incidence is expected to nearly double in the next 10 years [1]. According to Christie et al., who reported their centers' 6-year data (1922–1998), Paprosky type IIIA and IIIB defects accounted for 14% (78 hips) of the total number of revision hip replacements [2].

Different reconstruction options have been previously used to repair severe acetabular bone defects; however, unsatisfactory results reported in the published literature. Hip arthroplasty with one-staged restoration of acetabular integrity using plate and screw metallosteosynthesis resulted in revision in 47% of cases within 3 weeks to 124 months after the surgery [4].

In other studies using the antiprotrusion ring, the net reoperation rate was 29%–66% of cases [5–7].

The cup-cage technique is another option for the reconstruction of severe bone defects, including acetabular disruption. In the mid-term follow-up period, satisfactory results were obtained in 89% of cases [8, 9]. Complications included the dislocation of the endoprosthesis head, periprosthetic infection, and paresis of the peroneal portion of the sciatic nerve [8].

When porous tantalum augments were used during the 5-year follow-up period, only 2 out of 58 cases required revision because of aseptic loosening. In six cases, radiographic signs of progressive osteolysis of the bone in the third DeLee–Charnley zone were observed. A significant improvement in function after the 5-year follow-up was evidenced by the Mayo hip scores [10].

Another option for the reconstruction of large acetabular bone defects is the use of structural allografts combined with a tantalum-coated acetabular component. In one study, 1 of 20 patients had asymptomatic migration of the acetabular component that did not require revision [11]. The other

group included 58 patients (59 hips) with Paprosky type II–III acetabular defects in whom bone alloplasty combined with a cementless cup was used for reconstruction. In this group, revision was required in three cases: two with type IIIB defects and one with a type IIIA defect. Reoperations were performed after 4, 7, and 9 years for aseptic loosening of the acetabular component [12]. In 20 patients in whom a two-cup design was used for acetabular reconstruction, no cases of aseptic loosening occurred during the follow-up period (2.4 years). Complications included dislocation of the endoprosthesis head in six cases, deep infection in four cases, and delayed wound healing in three cases [13].

In the early stages of development, 3D-printing technology allowed for the creation of plastic models of the affected side of the pelvis, which were used to produce a clay prototype of the implant. The resulting prototype was then subjected to final modeling, from which a custom-made implant was fabricated from the forged titanium with the option of applying hydroxyapatite plasma spraying or porous coatings to the contact surface to stimulate osseointegration. The results improved but were still far from ideal. The failure rates ranged from 7.4% to 35% in 16 months to 7 years [2, 14–21].

The fabrication process of modern custom designs includes the creation of digital models that the surgeon can adjust online without viewing the physical model. This allows for wider dissemination of the technology and shortens the design time. Previously, the interval from CT scan to implant placement was 2–3 months [14]. In our experience, this interval is 3–4 weeks. In addition, the entire acetabular implant, including the porous base, is now printed using additive manufacturing technology, in which each titanium layer is fused using electron beam melting to ensure the strength of the implant.

Only a few published studies have demonstrated the results of current customized designs. At a conference in 2016, Hooper showed promising results with fewer revisions after 2 years than previous customized implants. Similar results were demonstrated in a study of nine patients. In this group, the median follow-up period was 28.8 months, the implant survival rate was 88.8%, and revision was required in one patient with bilateral pelvic bone integrity failure, which the authors believe led to unsatisfactory outcomes [22]. In a 2018 retrospective study with a mean follow-up period of 38 months of 36 patients, 1 had recurrent dislocations, 1 had revision for deep infection, 1 had early implant migration requiring stabilization, and 2 had radiological signs indicating lack of osseointegration. No cases of aseptic loosening were reported in this group at the time of publication [23].

With the improvement in the technological process abroad, the cost of customized implants has improved. In 2001, Joshi et al. reported that the cost of making an implant using clay models was \$5,000, whereas in 2012, Taunton et al. used computer models and made implants from forged titanium, which cost \$12,500. In 2021, Angela Yao

et al. reported that the cost of a customized implant using 3D-printing technology was AU\$19,000 [24]. Our experience with customized designs has demonstrated that with the improvement and adoption of 3D-printing technology, the cost of these implants has significantly decreased.

CONCLUSION

In severe acetabular defects, the use of customized components can achieve reliable “implant–bone” fixation, which leads to improved functional results. In chronic pelvic bone integrity defects, the use of an individual acetabular component does not always achieve reliable stabilization. All existing methods for solving this problem are currently ambiguous and require further improvement.

ДОПОЛНИТЕЛЬНО

Вклад авторов. Все авторы подтверждают соответствие своего авторства международным критериям ICMJE (все авторы внесли существенный вклад в разработку концепции, проведение исследования и подготовку статьи, прочли и одобрили финальную версию перед публикацией).

СПИСОК ЛИТЕРАТУРЫ

1. Kurtz S., Ong K., Lau E., Mowat F., Halpern M. Projections of primary and revision hip and knee arthroplasty in the United States from 2005 to 2030 // *Journal of Bone and Joint Surgery American*. 2007. Vol. 89, № 4. P. 780–785. doi: 10.2106/JBJS.F.00222
2. Christie M.J., Barrington S.A., Brinson M.R., Ruhling M.E., DeBoer D.K. Bridging massive acetabular defects with the triflange cup: 2- to 9-year results // *Clinical Orthopaedics and Related Research*. 2001. № 393. P. 216–227. doi: 10.1097/00003086-200112000-00024
3. Wyatt M.C. Custom 3D-printed acetabular implants in hip surgery — innovative breakthrough or expensive bespoke upgrade? // *HIP International*. 2015. Vol. 25, № 4. P. 375–379. doi: 10.5301/hipint.5000294
4. Stiehl J.B., Saluja R., Diener T. Reconstruction of major column defects and pelvic discontinuity in revision total hip arthroplasty // *Journal of Arthroplasty*. 2000. Vol. 17, № 7. P. 849–857. doi: 10.1054/arth.2000.9320
5. Berry D.J., Lewallen D.G., Hanssen A.D., Cabanela M.E. Pelvic discontinuity in revision total hip arthroplasty // *The Journal of Bone and Joint Surgery*. 1999. Vol. 81, № 12. P. 1692–1702. doi: 10.2106/00004623-199912000-00006
6. Berry D.J., Müller M.E. Revision arthroplasty using an anti-protrusion cage for massive acetabular bone deficiency // *Journal of Bone and Joint Surgery British*. 1992. Vol. 74, № 5. P. 711–715. doi: 10.1302/0301-620X.74B5.1527119
7. Paprosky W.B., O'Rourke M., Sporer S.M. The treatment of acetabular bone defects with an associated pelvic discontinuity // *Clinical Orthopaedics and Related Research*. 2005. Vol. 441. P. 216–220. doi: 10.1097/01.blo.0000194311.20901.f9
8. Hipfl C., Janz V., Löchel J., Perka C., Wassilew G.I. Cup-cage reconstruction for severe acetabular bone loss and pelvic

Источник финансирования. Авторы заявляют об отсутствии внешнего финансирования при проведении исследования и подготовке публикации.

Конфликт интересов. Авторы декларируют отсутствие явных и потенциальных конфликтов интересов, связанных с проведённым исследованием и публикацией настоящей статьи.

Информированное согласие на публикацию. Авторы получили письменное согласие пациентов на публикацию их медицинских данных и фотографий (24.11.2017 г.).

ADDITIONAL INFO

Author contribution. All authors made a substantial contribution to the conception of the work, acquisition, analysis, interpretation of data for the work, drafting and revising the work, final approval of the version to be published and agree to be accountable for all aspects of the work.

Funding source. This study was not supported by any external sources of funding.

Competing interests. The authors declare that they have no competing interests.

Consent for publication. The patients gave their written consent (24.11.2017) for publication of their medical data and images.

discontinuity // *The Bone & Joint Journal*. 2018. Vol. 100B, № 11. P. 1442–1448. doi: 10.1302/0301-620X.100B11.BJJ-2018-0481.R1

9. Sculco P.K., Ledford C.K., Hanssen A.D., Abdel M.P., Lewallen D.G. The evolution of the cup-cage technique for major acetabular defects: Full and half cup-cage reconstruction // *Journal of Bone and Joint Surgery American*. 2017. Vol. 99, № 13. P. 1104–1110. doi: 10.2106/JBJS.16.00821

10. Jenkins D.R., Odland A.N., Sierra R.J., Hanssen A.D., Lewallen D.G. Minimum five-year outcomes with porous tantalum acetabular cup and augment construct in complex revision total hip arthroplasty // *Journal of Bone and Joint Surgery American*. 2017. Vol. 99, № 10. P. e49. doi: 10.2106/JBJS.16.00125

11. Chang C.H., Hu C.C., Chen C.C., Mahajan J., Chang Y., Shih H.N., et al. Revision total hip arthroplasty for paprosky type iii acetabular defect with structural allograft and tantalum trabecular metal acetabular cup // *Orthopedics*. 2018. Vol. 41, № 6. P. e861–e867. doi: 10.3928/01477447-20181023-02

12. Chen H.T., Wu C.T., Huang T.W., Shih H.N., Wang J.W., Lee M.S. Structural and morselized allografting combined with a cementless cup for acetabular defects in revision total hip arthroplasty: A 4- to 14-year follow-up // *BioMed Research International*. 2018. Vol. 2364269. doi: 10.1155/2018/2364269

13. Webb J.E., McGill R.J., Palumbo B.T., Moschetti W.E., Estok D.M. The double-cup construct: A novel treatment strategy for the management of Paprosky IIIA and IIIB acetabular defects // *The Journal of Arthroplasty*. 2017. Vol. 32, № 9. P. S225–S231. doi: 10.1016/j.arth.2017.04.017

14. Barlow B.T., Oi K.K., Lee Y., Carli A.V., Choi D.S., Bostrom M.P. Outcomes of custom flange acetabular components in revision total hip arthroplasty and predictors of failure // *The Journal of Arthroplasty*. 2016. Vol. 31, № 5. P. 1057–1064. doi: 10.1016/j.arth.2015.11.016

15. Berasi C.C., Berend K.R., Adams J.B., Ruh E.L., Lombardi A.V. Jr. Are custom triflange acetabular components effective for reconstruction of catastrophic bone loss? // *Clinical Orthopaedics and Related Research*. 2015. Vol. 473, № 2. P. 528–535. doi: 10.1007/s11999-014-3969-z
16. DeBoer D.K., Christie M.J., Brinson M.F., Morrison J.C. Revision total hip arthroplasty for pelvic discontinuity // *Journal of Bone and Joint Surgery American*. 2007. Vol. 89, № 4. P. 835–840. doi: 10.2106/JBJS.F.00313
17. Holt G.E., Dennis D.A. Use of custom triflanged acetabular components in revision total hip arthroplasty // *Clinical Orthopaedics and Related Research*. 2004. № 429. P. 209–214. doi: 10.1097/01.blo.0000150252.19780.74
18. Joshi A.B., Lee J., Christensen C. Results for a custom acetabular component for acetabular deficiency // *Journal of Arthroplasty*. 2002. Vol. 17, № 5. P. 643–648. doi: 10.1054/arth.2002.32106
19. Mao Y., Xu C., Xu J., et al. The use of customized cages in revision total hip arthroplasty for Paprosky type III acetabular bone defects // *International Orthopaedics*. 2015. Vol. 39, № 10. P. 2023–2030. doi: 10.1007/s00264-015-2965-6
20. Taunton M.J., Fehring T.K., Edwards P., Bernasek T., Holt G.E., Christie M.J. Pelvic discontinuity treated with custom triflange component: A reliable option // *Clinical Orthopaedics and Related Research*. 2012. Vol. 470, № 2. P. 428–434. doi: 10.1007/s11999-011-2126-1
21. Wind M.A. Jr., Swank M.I., Sorger J.I. Shortterm results of a custom triflange acetabular component for massive acetabular bone loss in revision THA // *Orthopedics*. 2013. Vol. 36, № 3. P. e260–e265. doi: 10.3928/01477447-20130222-11
22. Citak M., Kochsiek L., Gehrke T., Haasper C., Suero E.M., Mau H. Preliminary results of a 3D-printed acetabular component in the management of extensive defects // *HIP International*. 2018. Vol. 28, № 3. P. 266–271. doi: 10.5301/hipint.5000561
23. Kieser D.C., Ailabouni R., Kieser S.C.J., Wyatt M.C., Armour P.C., Coates M.H., et al. The use of an Ossis custom 3D-printed triflanged acetabular implant for major bone loss: Minimum 2-year follow-up // *HIP International*. 2018. Vol. 28, № 6. P. 668–674. doi: 10.1177/1120700018760817
24. Yao A., George D.M., Ranawat V., Wilson C.J. 3D Printed Acetabular Components for Complex Revision Arthroplasty // *Indian J Orthop*. 2021. Vol. 55, № 3. P. 786–792. doi: 10.1007/s43465-020-00317-x

REFERENCES

1. Kurtz S, Ong K, Lau E, Mowat F, Halpern M. Projections of primary and revision hip and knee arthroplasty in the United States from 2005 to 2030. *Journal of Bone and Joint Surgery American*. 2007;89(4):780–785. doi: 10.2106/JBJS.F.00222
2. Christie MJ, Barrington SA, Brinson MR, Ruhling ME, DeBoer DK. Bridging massive acetabular defects with the triflange cup: 2- to 9-year results. *Clinical Orthopaedics and Related Research*. 2001;(393):216–227. doi: 10.1097/00003086-200112000-00024
3. Wyatt MC. Custom 3D-printed acetabular implants in hip surgery — innovative breakthrough or expensive bespoke upgrade? *HIP International*. 2015;25(4):375–379. doi: 10.5301/hipint.5000294
4. Stiehl JB, Saluja R, Diener T. Reconstruction of major column defects and pelvic discontinuity in revision total hip arthroplasty. *Journal of Arthroplasty*. 2000;17(7):849–857. doi: 10.1054/arth.2000.9320
5. Berry DJ, Lewallen DG, Hanssen AD, Cabanela ME. Pelvic discontinuity in revision total hip arthroplasty. *The Journal of Bone and Joint Surgery*. 1999;81(12):1692–1702. doi: 10.2106/00004623-199912000-00006
6. Berry DJ, Müller ME. Revision arthroplasty using an anti-protrusion cage for massive acetabular bone deficiency. *Journal of Bone and Joint Surgery British*. 1992;74(5):711–715. doi: 10.1302/0301-620X.74B5.1527119
7. Paprosky WB, O'Rourke M, Sporer SM. The treatment of acetabular bone defects with an associated pelvic discontinuity. *Clinical Orthopaedics and Related Research*. 2005;441:216–220. doi: 10.1097/01.blo.0000194311.20901.f9
8. Hipfl C, Janz V, Löchel J, Perka C, Wassilew G. Cup-cage reconstruction for severe acetabular bone loss and pelvic discontinuity. *The Bone & Joint Journal*. 2018;100B(11):1442–1448. doi: 10.1302/0301-620X.100B11.BJJ-2018-0481.R1
9. Sculco PK, Ledford CK, Hanssen AD, Abdel MP, Lewallen DG. The evolution of the cup-cage technique for major acetabular defects: Full and half cup-cage reconstruction. *Journal of Bone and Joint Surgery American*. 2017;99(13):1104–1110. doi: 10.2106/JBJS.16.00821
10. Jenkins DR, Odland AN, Sierra RJ, Hanssen AD, Lewallen DG. Minimum five-year outcomes with porous tantalum acetabular cup and augment construct in complex revision total hip arthroplasty. *Journal of Bone and Joint Surgery American*. 2017;99(10):e49. doi: 10.2106/JBJS.16.00125
11. Chang CH, Hu CC, Chen CC, Mahajan J, Chang Y, Shih HN, et al. Revision total hip arthroplasty for paprosky type iii acetabular defect with structural allograft and tantalum trabecular metal acetabular cup. *Orthopedics*. 2018;41(6):e861–e867. doi: 10.3928/01477447-20181023-02
12. Chen HT, Wu CT, Huang TW, Shih HN, Wang JW, Lee MS. Structural and morselized allografting combined with a cementless cup for acetabular defects in revision total hip arthroplasty: A 4- to 14-year follow-up. *BioMed Research International*. 2018;2364269. doi: 10.1155/2018/2364269
13. Webb JE, McGill RJ, Palumbo BT, Moschetti WE, Estok DM. The double-cup construct: A novel treatment strategy for the management of Paprosky IIIA and IIIB acetabular defects. *The Journal of Arthroplasty*. 2017;32(9):S225–S231. doi: 10.1016/j.arth.2017.04.017
14. Barlow BT, Oi KK, Lee Y, Carli AV, Choi DS, Bostrom MP. Outcomes of custom flange acetabular components in revision total hip arthroplasty and predictors of failure. *The Journal of Arthroplasty*. 2016;31(5):1057–1064. doi: 10.1016/j.arth.2015.11.016
15. Berasi CC, Berend KR, Adams JB, Ruh EL, Lombardi AV Jr. Are custom triflange acetabular components effective for reconstruction of catastrophic bone loss? *Clinical Orthopaedics and Related Research*. 2015;473(2):528–535. doi: 10.1007/s11999-014-3969-z
16. DeBoer DK, Christie MJ, Brinson MF, Morrison JC. Revision total hip arthroplasty for pelvic discontinuity. *Journal of Bone and Joint Surgery American*. 2007;89(4):835–840. doi: 10.2106/JBJS.F.00313
17. Holt GE, Dennis DA. Use of custom triflanged acetabular components in revision total hip arthroplasty. *Clinical Orthopaedics and Related Research*. 2004;(429):209–214. doi: 10.1097/01.blo.0000150252.19780.74
18. Joshi AB, Lee J, Christensen C. Results for a custom acetabular component for acetabular deficiency. *Journal of Arthroplasty*. 2002;17(5):643–648. doi: 10.1054/arth.2002.32106
19. Mao Y, Xu C, Xu J, et al. The use of customized cages in revision total hip arthroplasty for Paprosky type III acetabular

bone defects. *International Orthopaedics*. 2015;39(10):2023–2030. doi: 10.1007/s00264-015-2965-6

20. Taunton MJ, Fehring TK, Edwards P, Bernasek T, Holt GE, Christie MJ. Pelvic discontinuity treated with custom triflange component: A reliable option. *Clinical Orthopaedics and Related Research*. 2012;470(2):428–434. doi: 10.1007/s11999-011-2126-1

21. Wind MA Jr, Swank MI, Sorger JI. Shortterm results of a custom triflange acetabular component for massive acetabular bone loss in revision THA. *Orthopedics*. 2013;36(3):e260–e265. doi: 10.3928/01477447-20130222-11

22. Citak M, Kochsiek L, Gehrke T, Haasper C, Suero EM, Mau H. Preliminary results of a 3D-printed acetabular component in the management of extensive defects. *HIP International*. 2018;28(3):266–271. doi: 10.5301/hipint.5000561

23. Kieser DC, Ailabouni R, Kieser SCJ, Wyatt MC, Armour PC, Coates MH, et al. The use of an Ossis custom 3D-printed tri-flanged acetabular implant for major bone loss: Minimum 2-year follow-up. *HIP International*. 2018;28(6):668–674. doi: 10.1177/1120700018760817

24. Yao A, George DM, Ranawat V, Wilson CJ. 3D Printed Acetabular Components for Complex Revision Arthroplasty. *Indian J Orthop*. 2021;55(3):786–792. doi: 10.1007/s43465-020-00317-x

ОБ АВТОРАХ

* **Алексанян Оваким Аргамович**, к.м.н.,

врач травматолог-ортопед;

адрес: Россия, 127299, Москва, ул. Приорова, д. 10;

ORCID: 0000-0002-6909-6624;

e-mail: Hovakim1992@mail.ru

Чрагян Гамлет Ашотович, к.м.н.,

врач травматолог-ортопед;

ORCID: 0000-0001-6457-3156;

eLibrary SPIN: 5580-8152;

e-mail: chragyan@gmail.com

Каграманов Сергей Владимирович, д.м.н.,

врач травматолог-ортопед;

ORCID: 0000-0002-8434-1915;

eLibrary SPIN: 4670-7747;

e-mail: kagramanov2001@mail.ru

Ханмуратов Руслан Агамуратович,

врач травматолог-ортопед;

ORCID: 0009-0005-6963-2027;

e-mail: ottogross@bk.ru

Загородний Николай Васильевич, д.м.н., профессор,

член-корреспондент РАН, врач травматолог-ортопед;

ORCID: 0000-0002-6736-9772;

eLibrary SPIN: 6889-8166;

e-mail: zagorodniy51@mail.ru

AUTHORS' INFO

* **Ovakim A. Aleksanyan**, MD, Cand. Sci. (Med.),

traumatologist-orthopedist;

address: 10 Priorova street, 127299, Moscow, Russia;

ORCID: 0000-0002-6909-6624;

e-mail: Hovakim1992@mail.ru

Gamlet A. Chragyan, MD, Cand. Sci. (Med.),

traumatologist-orthopedist;

ORCID: 0000-0001-6457-3156;

eLibrary SPIN: 5580-8152;

e-mail: chragyan@gmail.com

Sergey V. Kagramanov, MD, Dr. Sci. (Med.),

traumatologist-orthopedist;

ORCID: 0000-0002-8434-1915;

eLibrary SPIN: 4670-7747;

e-mail: kagramanov2001@mail.ru

Ruslan A. Khanmuradov,

traumatologist-orthopedist;

ORCID: 0009-0005-6963-2027;

e-mail: ottogross@bk.ru

Nikolay V. Zagorodniy, MD, Dr. Sci. (Med.), Professor,

Corresponding member of RAS, traumatologist-orthopedist;

ORCID: 0000-0002-6736-9772;

eLibrary SPIN: 6889-8166;

e-mail: zagorodniy51@mail.ru

* Автор, ответственный за переписку / Corresponding author