

DOI: <https://doi.org/10.17816/vto617680>

# Can anterior dynamic correction be considered a new standard of surgical treatment for idiopathic scoliosis in patients with completed and terminating growth? Retrospective single-center analysis of long-term results

Sergei V. Kolesov, Vladimir S. Pereverzev, Arkadii I. Kazmin, Nataliya S. Morozova, Vladimir V. Shvec, Michail S. Raspopov, Samir B. Bagirov

Priorov Central Institute of Traumatology and Orthopedic, Moscow, Russia

## ABSTRACT

**BACKGROUND:** Currently, the gold standard of surgical treatment of idiopathic scoliosis is dorsal or anterior correction using rigid instrumentation. However, anterior dynamic scoliosis correction has recently become a popular method for treating idiopathic scoliosis. It is recommended for patients with a certain growth potential. We present the long-term treatment results of patients with idiopathic scoliosis and the use of a dynamic correction system during completed and ending growth.

**AIM:** To evaluate radiological and clinical data on the results of surgical treatment of idiopathic scoliosis in patients with completed and terminating growth and a FU period of >2 years.

**MATERIALS AND METHODS:** A retrospective study of demographic data, X-ray (Cobb angle before and after surgery and  $\geq 2$  years, Lenke type, Risser test), number of fixation levels, nucleotomy, blood loss, surgery time, and complications, was conducted. The functional result was evaluated using the SRS-22.

**RESULTS:** Eighty-seven patients (men, 4; women, 83) were included. ASC (thoracic) was performed in 30 patients; lumbar/thoracolumbar, 32; 2 sides, 13; and hybrid system, 12. Lenke: Lenke 1 (right-sided, 18; left-sided, 7); Lenke 2, 5; Lenke 3, 19; Lenke 4, 2; Lenke 5 (left-sided, 26; right-sided, 8); and Lenke 6, 2. The average blood loss was  $281.2 \pm 173$  ml; operation time,  $174.8 \pm 42.3$  min; FU, 2.2 years; age, 23.3 years; Risser, 4.42 (3–5); number of fixed levels  $7.25 \pm 1.6^\circ$ ; and Cobb angle in the thoracic group during the first post-op study,  $27.9 \pm 5.3^\circ$ , and the last at  $25.2 \pm 6.9^\circ$  compared with the pre-op at  $62.4 \pm 10.9^\circ$  ( $p < 0.05$ ). No significant loss of correction was found in patients with Lenke 5,  $52.5 \pm 8.4^\circ$  before surgery,  $24.2 \pm 12.4^\circ$  after, and a long-term FU of  $27.2 \pm 11.6^\circ$  ( $p < 0.05$ ).

**CONCLUSION:** Dynamic scoliosis correction in adults is a new direction in spine surgery and provides a satisfactory radiological and functional result that persists for 2 years.

**Keywords:** idiopathic scoliosis; dynamic correction; ASC.

## To cite this article:

Kolesov SV, Pereverzev VS, Kazmin AI, Morozova NS, Shvec VV, Raspopov MS, Bagirov SB. Can anterior dynamic correction be considered a new standard of surgical treatment of idiopathic scoliosis in patients with completed and terminating growth? Retrospective single-center analysis of long-term results. *N.N. Priorov Journal of Traumatology and Orthopedics*. 2024;31(2):147–157. DOI: <https://doi.org/10.17816/vto617680>

Received: 08.11.2023

Accepted: 22.01.2024

Published online: 24.04.2024

DOI: <https://doi.org/10.17816/vto617680>

# Можно ли считать вентральную динамическую коррекцию новым стандартом хирургического лечения идиопатического сколиоза у пациентов с завершённым и завершающимся ростом? Ретроспективный моноцентровой анализ отдалённых результатов

С.В. Колесов, В.С. Переверзев, А.И. Казьмин, Н.С. Морозова, В.В. Швец, М.С. Распопов, С.Б. Багиров

Национальный медицинский исследовательский центр травматологии и ортопедии им. Н.Н. Приорова, Москва, Россия

## АННОТАЦИЯ

**Обоснование.** Золотым стандартом хирургического лечения идиопатического сколиоза является дорсальная или вентральная коррекция с использованием ригидных металлоконструкций. В последнее время вентральная динамическая коррекция стала популярным методом лечения идиопатического сколиоза. Мы представляем результаты лечения пациентов с идиопатическим сколиозом и использованием динамической системы коррекции в период завершённого и завершающегося роста.

**Цель.** Оценка рентгенологических и клинических данных результатов хирургического лечения идиопатического сколиоза у пациентов с завершённым и завершающимся ростом и периодом наблюдения более 2 лет.

**Материалы и методы.** Проведено ретроспективное исследование пациентов, которым была выполнена вентральная динамическая коррекция сколиоза. Учитывали демографические данные (пол, возраст), Rg данные (угол Кобба до, после операции и  $\geq 2$  лет, тип деформации по Lenke, тест Риссера), характер хирургического вмешательства, количество уровней фиксации, нуклеотомию, кровопотерю, время операции, осложнения. Функциональный результат оценивали по анкете SRS-22.

**Результаты.** Из 87 пациентов 4 (4,6%) были мужского и 83 (95,4%) — женского пола. ASC грудного отдела выполнена у 30 пациентов, поясничного/грудопоясничного — у 32, с двух сторон — у 13, гибридная система — в 12 случаях. Разделение по Lenke: Lenke 1 — 18 (правосторонний), 7 (левосторонний), Lenke 2 — 5, Lenke 3 — 19, Lenke 4 — 2, Lenke 5 — 26 (левосторонний), 8 (правосторонний), Lenke 6 — 2. Средняя кровопотеря составила  $281,2 \pm 173$  мл, время операции —  $174,8 \pm 42,3$  мин. Средний период наблюдения составил 2,2 года, возраст — 23,3 года, тест Риссера — 4,42 (3–5). Среднее количество фиксированных уровней динамической системы —  $7,25 \pm 1,6$ . Средний угол Кобба в группе грудного отдела —  $27,9 \pm 5,3^\circ$  при первом послеоперационном исследовании и  $25,2 \pm 6,9^\circ$  при последнем, до операции —  $62,4 \pm 10,9^\circ$  ( $p < 0,05$ ). При операции по поводу поясничного/грудопоясничного сколиоза значимой потери коррекции не выявлено (до операции —  $52,5 \pm 8,4^\circ$ , после —  $24,2 \pm 12,4^\circ$ , при отдалённом наблюдении —  $27,2 \pm 11,6^\circ$  ( $p < 0,05$ )).

**Заключение.** Динамическая коррекция позвоночника у взрослых является новым направлением в хирургии сколиоза и позволяет достигнуть удовлетворительного рентгенологического и функционального результата, сохраняющегося при наблюдении  $\geq 2$  лет. Дальнейшее использование, накопление материала, исследования с более высоким уровнем доказательности и более продолжительным периодом наблюдения позволят сделать окончательные выводы.

**Ключевые слова:** идиопатический сколиоз; динамическая коррекция; ASC.

## Как цитировать:

Колесов С.В., Переверзев В.С., Казьмин А.И., Морозова Н.С., Швец В.В., Распопов М.С., Багиров С.Б. Можно ли считать вентральную динамическую коррекцию новым стандартом хирургического лечения идиопатического сколиоза у пациентов с завершённым и завершающимся ростом? Ретроспективный моноцентровой анализ отдалённых результатов // Вестник травматологии и ортопедии им. Н.Н. Приорова. 2024. Т. 31, № 2. С. 147–157. DOI: <https://doi.org/10.17816/vto617680>

## BACKGROUND

Posterior spondylosis using stiff metal structures is the gold standard for the surgical treatment of idiopathic scoliosis (IS). This procedure allows for the effective correction of the deformity and prevention of its progression [1]. However, recently, ventral dynamic correction of scoliosis has become a new and popular method for IS treatment [2–7]. The main advantages include the use of a minimally traumatic intermuscular approach, minimal blood loss, and likely prevention of vertebral fusion, resulting in a lower risk of adjacent disc degeneration. With a ventral approach, the preservation of the posterior spinal muscles results in early recovery [8].

Ventral dynamic correction of scoliosis [9–11] has two main routes of use. The first is vertebral body tethering (VBT), which is a dynamic correction of the growing spine. It is used to modulate IS when significant growth and, therefore, gradual correction of the deformity is expected without performing spondylosis. The term was first coined by C.H. Crawford and L.G. Lenke [9]. The second approach is anterior scoliosis correction (ASC), which employs the same instrumentation but modifies the technique to preserve spinal mobility in the fixation zone [3, 4, 12]. ASC is indicated for older patients with a high Risser and Sanders stage and those with severe scoliosis and limited curvature mobility [3, 12]. Recent publications have reported successful outcomes and few mechanical complications when ventral dynamic scoliosis correction was performed near the end of skeletal maturation [13]. However, most of these publications focus on pediatric groups [2, 13–16]. Initially, we used ASC because of the high risk of complications, such as cord rupture and hypercorrection, in patients without pronounced growth potential [13, 17, 18]. Furthermore, evidence shows that individuals with a Sanders test score of  $\leq 2$  have a high risk of overcorrection, those with a score of three have more predictable outcomes, and those with a score of 4–5 have even fewer mechanical complications [13]. The incidence of cord ruptures was significantly lower in patients who did not undergo the growth-modulated dynamic correction approach. Available evidence from the use of ventral dynamic scoliosis correction in skeletally mature individuals indicates that this approach is an effective method for correcting scoliosis, with fewer complications and earlier return to physical activity [8, 19].

This study aimed to assess the radiological and clinical outcomes of surgical treatment of IS in patients with complete and incomplete growth, with a minimum followup period of 2 years.

## MATERIALS AND METHODS

### Study design

A single-center retrospective cohort study was conducted.

### Eligibility criteria

This retrospective study enrolled 87 patients who underwent ventral dynamic scoliosis correction. All ASC

procedures were performed by an experienced orthopedic surgeon in collaboration with one or two assistant surgeons and a well-coordinated surgical team.

*Inclusion criteria:* Dynamic scoliosis correction in individuals with complete or incomplete growth (ASC), followup period of  $\geq 2$  years, and age 14–42 years without preserved growth potential. Skeletal maturity was assessed by the Risser test, which had to be  $\geq 3$ .

*Exclusion criteria:* Congenital, neuromuscular, or syndromal scoliosis, rigid deformities ( $>50\%$  deformity corrected in the bending or traction test), thoracic kyphosis  $<40^\circ$ , and previous spinal surgery.

### Settings

The study included patients treated at the Traumatology and Orthopedics Department of Spine Pathology No. 7 of the N.N. Priorov National Medical Research Center for Traumatology and Orthopedics (Moscow, Russia).

### Study duration

The study was conducted between July 2019 and September 2023.

### Description of the medical intervention

The demographic parameters (sex and age) and radiological data (Cobb angles before, after surgery, and after  $>2$  years at the most recent followup, regardless of whether a revision was performed) were recorded. Radiological data from followup examinations conducted at 6 and 12 months were excluded from the analysis, as the focus was on long-term outcomes. The following variables were analyzed: Lenke deformity type, Risser test score, surgical intervention type, number of fixation levels, nucleotomy for mobilization, blood loss volume, operation time, and complications throughout the followup period. Cord breakage was identified as a change in a screw angle of  $>5^\circ$  on standing spine radiographs. The functional outcome was assessed using the Scoliosis Research Society (SRS)-22 questionnaire.

### Surgical technique

The procedure was performed via a thoracotomy (mini) approach, which requires the removal of a portion of the rib. This method is similar to the classical anterior approach in treating spondylosis. The incision was made in the ninth intercostal space, as is standard practice in thoracic surgery. This approach allows for screw placement from Th8 to L1 and through three ribs above for screw placement in Th5–7. One screw was placed at the levels of Th5–6. The pleura was dissected from the anterolateral surface of each vertebral body just in front of the heads of the ribs along the length of the planned fixation. The segmental vessels were coagulated. Lumbar/thoracolumbar access was performed along the upper edge of the 10th rib, and the costochondral junction

was dissected. For thoracolumbar access, the incision can be extended in the direction of the external oblique abdominal muscle approximately 3–5 cm anteriorly. The incision length was depended on which part of the lumbar spine must be visualized. Subsequently, standard retroperitoneal access to the spine with frenotomy was performed. Once the deformity apex was viewed, X-ray control of the levels was performed. In 49.3% of the cases, nucleotomy for mobilization was performed by dissecting the fibrous ring and partial removal of the pulposus nucleus (Table 1, Fig. 1).

In all cases, 6-mm-diameter hydroxyapatite-coated Zimmer Dynesys screws with glass were placed. The screw placement was performed under X-ray control to ensure proper positioning and bicortical placement. A flexible polyethylene terephthalate cord was guided from the bottom to the top through the screwheads, which were passed into the vertebral bodies. Spinal correction was achieved through segmental tensioning of the cord between vertebrae and derotation and translation of the spine to achieve maximum correction on the operating table.

### Main outcome of the study

The success criteria for the surgical intervention were defined as satisfactory correction of >50% of the original deformity, absence of correction loss after a 2-year followup period, absence of cord rupture, and no redo surgery associated with various complications.

### Statistical analysis

A statistical difference was calculated using descriptive statistics, specifically the mean of the parameter, standard deviation, and minimum and maximum values. The Mann–Whitney *U*-criterion was used to determine the differences

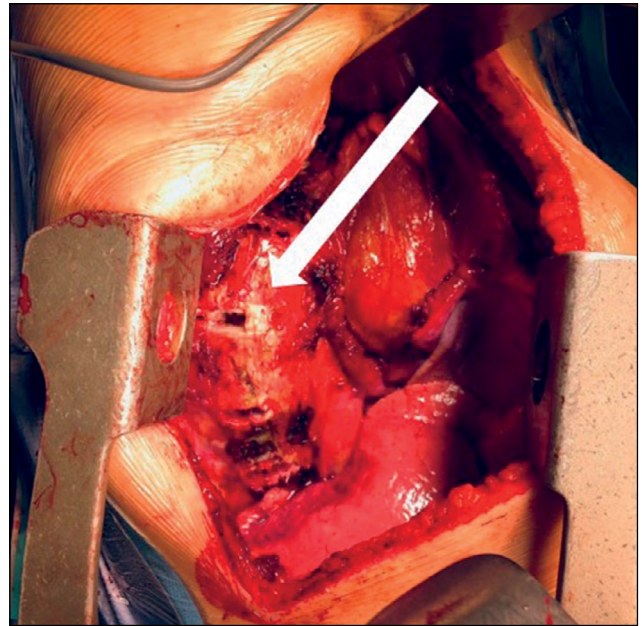


Fig. 1. Type of surgical wound after thoracophrenolumbotomy, a nucleotomy was performed in order to mobilize the scoliotic curve in the area of planned fixation.

in parameters between groups. A *p*-value of <0.05 was considered statistically significant.

### Ethical review

All procedures conducted with human participants were in accordance with the ethical standards of the Association of Traumatologists–Orthopedists of Russia and the 1964 Declaration of Helsinki and its subsequent amendments or comparable ethical standards. All patients (or their representatives) provided informed consent.

Table 1. Frequency of nucleotomy for mobilization among all patients

Presence of a nucleotomy	Incidence		
	<i>n</i>	%	
0 levels (none)	28	47.4	
1 level	1	0.61	
2 levels	3	4.9	
3 levels	8	13.1	
4 levels	8	13.1	
5 levels	5	8.2	
6 levels	1	1.6	
7 levels	2	3.3	
9 levels	2	3.3	
Total	59	96.7	
Missed	No data	3	4.9
Total	61	100.0	

## RESULTS

### Surgical intervention and Lenke classification

Dynamic correction of thoracic scoliosis in individuals without significant growth potential (thoracic ASC) was performed in 30 patients, lumbar/thoracolumbar ASC in 32, and bilateral ASC in 13. A hybrid system (dorsal stiffening correction of the thoracic region and ventral dynamic lumbar/thoracolumbar region) was established in 12 cases. The Lenke classification system was employed to categorize the deformities, with no consideration of modifiers, as follows: Lenke 1 (right-sided) = 18, Lenke 2 (left-sided) = 5, Lenke 3 (right-sided) = 19, Lenke 4 (left-sided) = 2, Lenke 5 (right-sided) = 26, and Lenke 6 (left-sided) = 2. The mean blood loss by ventral access was  $281.2 \pm 173$  mL. The mean operation time was  $174.8 \pm 42.3$  min.

### Demographic data

Of the 87 patients, 4 (4.6%) were male and 83 (95.4%) were female. According to the etiology of the scoliotic deformity, the inclusion criterion was IS. The mean followup period was 2.2 (2–3.2) years. The mean age at the time of surgery was 23.3 (range, 14–43) years.

### Radiologic findings

The mean score of Risser's test was 4.42 (3–5). The mean number of fixed levels of the dynamic system was  $7.25 \pm 1.6$  (range, 5–12). The most proximal and distal levels were Th5 and L4, respectively.

The mean Cobb angles in the thoracic ASC group at the first postoperative study and the last followup were  $27.9^\circ \pm 5.3^\circ$  and  $25.2^\circ \pm 6.9^\circ$ , respectively, compared with the preoperative value of  $62.4^\circ \pm 10.9^\circ$  ( $p < 0.05$ ). Patients who underwent surgery for lumbar/thoracolumbar scoliosis also

demonstrated no significant loss of correction. The mean Cobb angles were  $52.5^\circ \pm 8.4^\circ$  preoperatively,  $24.2^\circ \pm 12.4^\circ$  postoperatively, and  $27.2^\circ \pm 11.6^\circ$  at the last followup ( $p < 0.05$ ).

In all groups, patients exhibited no significant loss of deformity correction during the followup period, including those in the two-stage dynamic and hybrid approach groups (Table 2).

The best results were achieved with both thoracic and lumbar/thoracolumbar correction (Fig. 2).

The patients demonstrated a significant improvement in all preoperative Cobb angles immediately after the intervention. The correction was maintained in the majority of patients at followup, with a slight loss of correction observed in two patients.

### SRS-22 score

The mean SRS-22 scores among all patients were  $77.9 \pm 4.5$  preoperatively and  $90.6 \pm 5.5$  postoperatively ( $p < 0.05$ ). The SRS-22 scores at the final followup by groups are presented in Table 3.

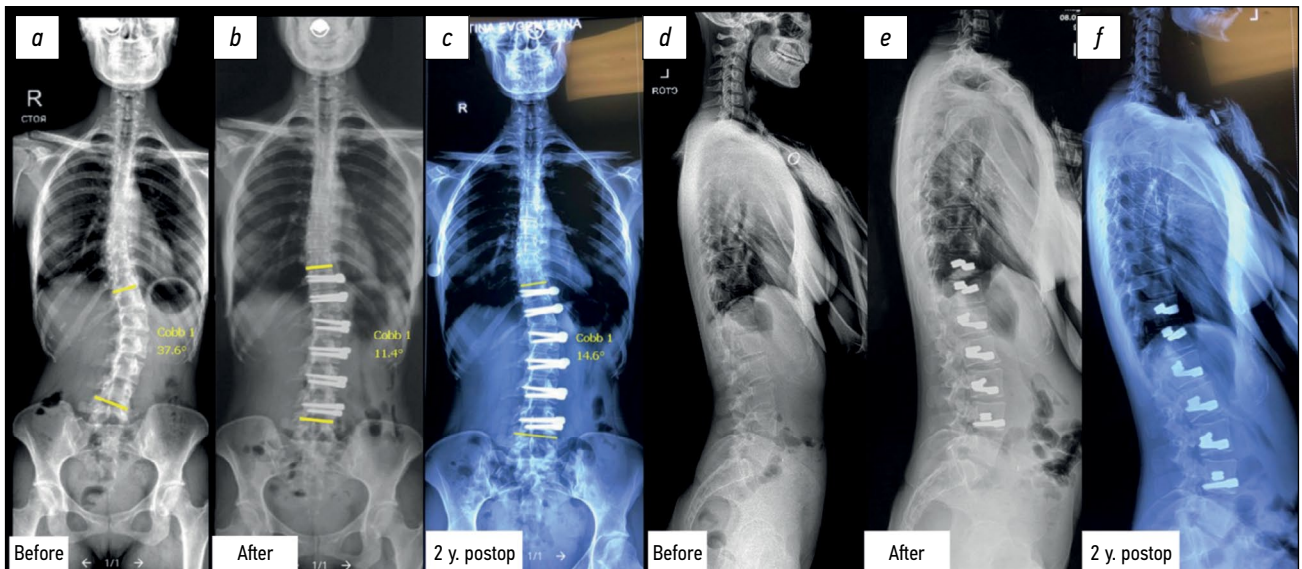
No significant differences in pain and self-esteem were found between the groups; however, measures of function, satisfaction with surgery, and self-perception were higher in the lumbar/thoracolumbar correction group.

### Complications and revisions

Six patients underwent revision surgery. Although all patients achieved satisfactory results, access-related complications were observed, including pulmonary complications such as hemothorax, chylothorax, and pneumothorax. One patient required revision because of hemothorax. Two patients experienced chylothorax postoperatively, which was managed conservatively

**Table 2.** X-ray data in patients with different types of dynamic scoliosis correction at the followup stages

Groups	Cobb angle at followup
Thoracic ASC (n=30)	Before surgery: $62.4 \pm 10.9$ After surgery: $27.9 \pm 5.3$ At remote followup: $29.2 \pm 6.9$
Lumbar/thoracolumbar ASC (n=32)	Before surgery: $52.5 \pm 8.4$ After surgery: $24.2 \pm 12.4$ At remote followup: $27.2 \pm 11.6$
Bilateral ASC (n=13)	<i>Thoracic</i> Before surgery: $53.4 \pm 10.6$ After surgery: $29.2 \pm 10.3$ At remote followup: $28.2 \pm 9.4$
	<i>Lumbar</i> Before surgery: $49.8 \pm 13.6$ After surgery: $28.2 \pm 6.7$ At remote followup: $30.5 \pm 12.1$
Hybrid (lumbar) (n=11)	Before surgery: $57.4 \pm 7.9$ After surgery: $22.9 \pm 12.3$ At remote followup: $24.2 \pm 8.0$



**Fig. 2.** X-ray of the patient before surgery (a, d), immediately after lumbar spine anterior dynamic scoliosis correction (b, e) and at the follow-up stage 2 years postop (c, f). There is no significant loss of correction.

**Table 3.** SRS-22 scores at the final followup

Indicators	Thoracic ASC (n=30)	Lumbar/thoracolumbar ASC (n=32)	Bilateral ASC (n=13)	Hybrid (n=11)
Function	4.1±0.63	4.7±0.3	4.8±0.38	3.9±0.8
Pain	4.0±0.71	4.2±0.66	4.3±0.79	4.4±0.69
Mental function	4.4±0.76	4.6±0.42	4.6±0.9	4.4±0.45
Self-perception	3.94±0.78	4.1±0.35	4.4±0.5	4.2±0.2
Satisfaction with the surgery	4.2±0.64	4.3±0.77	4.3±0.6	4.2±0.74

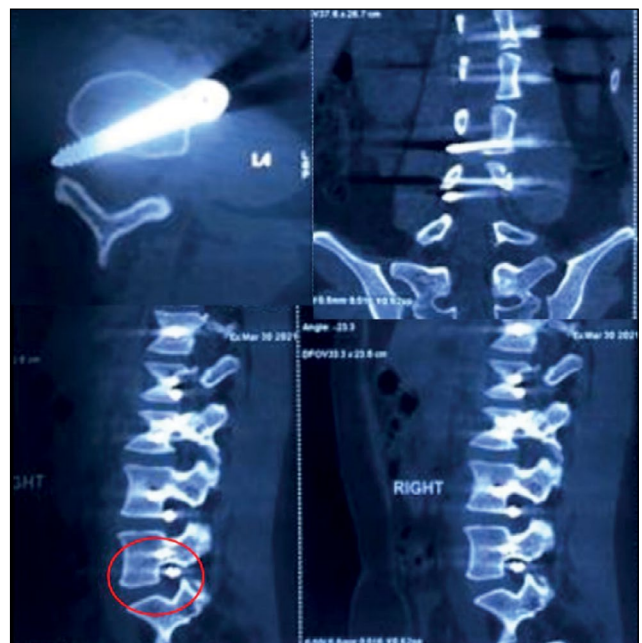Note. Differences are significant at  $p < 0.05$ .

with diet and octreotide. Neuropathy was observed after lumbar/thoracolumbar correction in one case necessitating revision. Malposition was observed in two patients, requiring revision. The screw was incorrectly placed in L4 in one patient, with the 45-mm screw entering the foraminal foramen on the opposite side, accompanied by radiculopathy requiring repeated surgical intervention (Fig. 3).

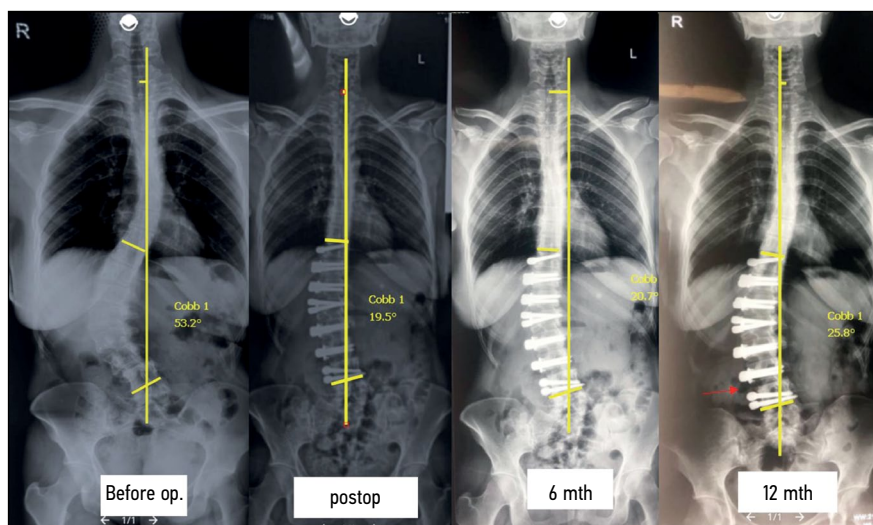
Two cases of cord rupture occurred after lumbar spine correction at the most distal level where no nucleotomy was performed. However, no significant loss of correction was observed after the repeat surgery (Fig. 4).

## DISCUSSION

Dorsal correction and fixation of the spine with spondylosis is the primary approach to surgical treatment of IS. However, the main disadvantage of this method is a total restriction of mobility in the fixation zone. Iatrogenic bone block of vertebral motor segments leads to an increased risk of degenerative changes at adjacent levels, causing secondary back pain [20]. Consequently, preserving spinal mobility, particularly of the lumbar spine, is a highly desirable goal



**Fig. 3.** CT scans of a 16-year-old female patient after performing lumbar spine anterior dynamic scoliosis correction: the presence of the anterior part of the screw in the area of the foraminal opening L4-L5 is noted with the condition of the L4 root compression.



**Fig. 4.** AP X-ray of a 32-year-old female patient after lumbar spine anterior dynamic scoliosis correction at the observation stages. There is an increase in the angle between the heads of the L3-L4 screws (level where the nucleotomy was not performed) 12 months after the surgery. There is no significant loss of correction, dynamic monitoring is recommended.

for the spinal surgeon. Ventral dynamic correction represents a novel approach to the treatment of IS.

A total of 63 patients who underwent thoracic and/or lumbar VBT with a followup period of >5 years were included in the study. The radiological assessment indicated that a cord rupture was characterized by a change in the angle between the screws of  $>5^\circ$ . Demographic, radiologic, and clinical risk factors for suspected VBT ruptures were evaluated. Ruptures were more common at the lumbar level than at the thoracic level. Furthermore, most ruptures occurred at levels distal to the apex. A mere 15% of all patients required revision surgery [21].

P. Trobisch and A. Baroncini et al. analyzed the results of 10 patients who underwent 11 revision surgeries. Ruptures were found on 36 of the 80 segments visualized. Of these 36 segments, only 20 had a suspected preoperative cord tear. Sixteen ruptures were not identified on preoperative radiographs (44%). In addition, one suspected cord tear was not confirmed intraoperatively. For example, using the  $>5^\circ$  rule, only 56% of ruptures could be diagnosed. On the contrary, not all cord ruptures result in loss of correction; this applies to patients who had one cord ruptured. Since the authors started using a second cord, no ruptures have been observed [22]. In our patients, we have routinely used two-cord fixation from the beginning, which may be associated with fewer ruptures. In addition, a significant loss of correction after cord rupture was not observed in our patients; thus, revision surgery was not required. In addition, our cohort was predominantly composed of individuals with complete growth who underwent nucleotomy at all fixation levels. In addition, nucleotomy was believed to reduce the risk of cord rupture, which appear to be associated with some reduction in the mobility of the spinal motion segment after nucleotomy, as we observed cord rupture at the distal level (L3-L4) in two patients where no mobilization was performed.

Overcorrection was not observed during followup, even in adolescents, because patients with high growth potential

(Risser stage at least 3) were not indicated for surgery. However, evidence shows that patients with a Sanders test score of  $\leq 2$  have a high risk of overcorrection; at 3, the situation is more predictable; and at 4 and 5, even fewer mechanical complications are observed [13]. In other words, cord rupture is less common in individuals who did not receive a dynamic correction approach with growth modulation.

The Sanders classification is a more sensitive and specific method of determining skeletal maturity than the Risser test. However, left-hand radiographs were not taken in our patients. Nevertheless, we described a group with “late” Risser of 3–5 (mean 4.42), where the ASC technique was used, which differs significantly from VBT and can be used for larger deformities and in individuals with a more mature skeleton, as the former does not imply self-correction [4]. The ASC technique can correct deformity angles beyond the normal physiologic limit of mobility, thereby demonstrating the effectiveness of this approach. However, data on mobility in our cohort were not available because of the noncomparability of the deformity and correction methods, for example, between the groups of patients with single-stage ASC and the hybrid approach.

In most of our patients, the main arc of the deformity was at the level of either the lumbar/thoracolumbar (Lenke 5) or thoracic spine (Lenke 1). The results of the study focused on the correction of the mean Cobb angles in the standing position immediately after surgery and at followup >2 years later. The mean Cobb angle indices in all groups did not change significantly until the most recent observation compared with the initial postoperative level ( $p < 0.05$ ), indicating that the correction was maintained in the remote period. Some cases showed some improvements, which appears to be related to the preservation of a certain growth potential in some patients. Conversely, a slight deterioration of radiologic parameters was noted in Lenke 5.

T. Pehlivanoglu et al. observed significantly higher mean total scores on the SRS-22 questionnaire (4.9 vs. 3.8,  $p < 0.001$ ) in the vertebroplasty group than in the group having posterior fixation with spondylosis. In addition, the mean SF-36 scores for the mental and physical components were higher in the vertebroplasty group [2]. This is confirmed by our postoperative SRS-22 questionnaire data for all types of correction, and the only difference was our analysis of an older cohort. The mean SRS-22 scores increased significantly ( $p < 0.05$ ), indicating an overall improvement in quality of life. In addition, perioperative complications did not significantly affect long-term functional outcomes.

Some authors believe that the optimal candidates for ASC are patients with the main structural curvature of  $60^\circ$ – $65^\circ$  and flexibility of  $>50\%$  in the traction test without anesthesia [8]. Our data indicate that the localization of the main arch—lumbar or thoracolumbar—is more amenable to dynamic correction, including in groups with a two-stage and hybrid approach (Table 2).

Dynamic scoliosis correction is encouraged in individuals with incomplete spinal growth [11, 12, 23, 24]; however, we believe that this method should be used in these patients because it has fewer complications, particularly cord ruptures [3, 12], as demonstrated by the primary results [8]. The mean blood loss was 281.2 mL, which is lower than that reported in standard spondylosis in the literature [25].

This study is subject to several limitations, including its retrospective design, heterogeneity of patients and deformities, sample size, monocenter data, and motion volume analysis. Furthermore, studies of spinal mobility in the distant period are necessary to prove motion preservation. However, a 2-year followup period is insufficient to evaluate long-term results; thus, a longer followup period is necessary to draw any definitive conclusions about the use of ventral dynamic scoliosis correction.

## REFERENCES

1. Newton PO, Bartley CE, Bastrom TP, et al. Anterior spinal growth modulation in skeletally immature patients with idiopathic scoliosis: a com-parison with posterior spinal fusion at 2 to 5 years postoperatively. *J Bone Joint Surg Am.* 2020;102(9):769–777. doi: 10.2106/JBJS.19.01176
2. Pehlivanoglu T, Oltulu I, Erdag Y, et al. Comparison of clinical and functional outcomes of vertebral body tethering to posterior spinal fusion in patients with adolescent idiopathic scoliosis and evaluation of quality of life: preliminary results. *Spine Deform.* 2021;9(4):1175–1182. doi: 10.1007/s43390-021-00323-5
3. Bernard Ja, Bishop T, Herzog Ja, et al. Dual modality of vertebral body tethering. *Bone and Joint Open.* 2022;3(2):123–129. doi: 10.1302/2633-1462.32.bjo-2021-0120.r1
4. Antonacci C, Antonacci M, Bassett W, et al. Treatment of Mature/Maturing Patients with Adolescent Idiopathic Scoliosis (Sanders  $\geq 5$ ) Using a Unique Anterior Scoliosis Correction Technique. *Med Res Arch.* 2021;9(12). doi: 10.18103/mra.v9i12.2632
5. Pehlivanoglu T, Oltulu I, Erdag Y, et al. Double-sided vertebral body tethering of double adolescent idiopathic scoliosis curves: radiographic outcomes of the first 13 patients with 2 years of follow-up. *Eur Spine J.* 2021;30(7):1896–1904. doi: 10.1007/s00586-021-06745-z
6. Hegde SK, Venkatesan M, Akbari KK, Badikillaya VM. Efficacy of Anterior Vertebral Body Tethering in Skeletally Mature Children with Adolescent Idiopathic Scoliosis: A Preliminary Report. *Int J Spine Surg.* 2021;15(5):995–1003. doi: 10.14444/8122
7. Yucekul A, Akpunarli B, Durbas A, et al. Does vertebral body tethering cause disc and facet joint degeneration? A preliminary MRI study with minimum 2-years follow-up. *Spine J.* 2021;21(11):1793–1801. doi: 10.1016/j.spinee.2021.05.020
8. Kolesov SV, Pereverzev VS, Panteleyev AA, et al. The first experience of anterior dynamic correction of scoliosis in adolescents with complete growth and adults: surgical technique and immediate results. *Hirurgiya pozvonochnika.* 2021;18(3):19–29. doi: 10.14531/ss2021.3.19-29

## CONCLUSIONS

The advent of dynamic correction of the adult spine represents a novel approach to scoliosis surgery. This approach has the potential to achieve satisfactory radiological and functional outcomes with a minimum followup period of 2 years. Further utilization, accumulation of material, and studies with a higher evidence level and longer followup periods are necessary to reach definitive conclusions.

## ADDITIONAL INFO

**Author contribution.** All authors made a substantial contribution to the conception of the work, acquisition, analysis, interpretation of data for the work, drafting and revising the work, final approval of the version to be published and agree to be accountable for all aspects of the work.

**Funding source.** This study was not supported by any external sources of funding.

**Competing interests.** The authors declare that they have no competing interests.

## ДОПОЛНИТЕЛЬНО

**Вклад авторов.** Все авторы подтверждают соответствие своего авторства международным критериям ICMJE (все авторы внесли существенный вклад в разработку концепции, проведение исследования и подготовку статьи, прочли и одобрили финальную версию перед публикацией).

**Источник финансирования.** Авторы заявляют об отсутствии внешнего финансирования при проведении исследования и подготовке публикации.

**Конфликт интересов.** Авторы декларируют отсутствие явных и потенциальных конфликтов интересов, связанных с проведённым исследованием и публикацией настоящей статьи.



9. Crawford CH, Lenke LG. Growth modulation by means of anterior tethering resulting in progressive correction of juvenile idiopathic scoliosis: A case report. *J Bone Jt Surg Am.* 2010;92(1):202–209. doi: 10.2106/JBJS.H.01728
10. Samdani AF, Ames RJ, Kimball JS, et al. Anterior vertebral body tethering for idiopathic scoliosis: two-year results. *Spine (Phila Pa 1976).* 2014;39(20):1688–1693. doi: 10.1097/BRS.0000000000000472
11. Raitio A, Syvänen J, Helenius I. Vertebral Body Tethering: Indications, Surgical Technique, and a Systematic Review of Published Results. *J Clin Med.* 2022;11(9):2576. doi: 10.3390/jcm11092576
12. Baroncini A, Trobisch PD, Migliorini F. Learning curve for vertebral body tethering: analysis on 90 consecutive patients. *Spine Deform.* 2021;9(1):141–147. doi: 10.1007/s43390-020-00191-5
13. Alanay A, Yucekul A, Abul K, et al. Thoracoscopic Vertebral Body Tethering for Adolescent Idiopathic Scoliosis: Follow-up Curve Behavior According to Sanders Skeletal Maturity Staging. *Spine (Phila Pa 1976).* 2020;45:E1483–E1492.
14. Wong HK, Ruiz JNM, Newton PO, Gabriel Liu KP. Non-Fusion Surgical Correction of Thoracic Idiopathic Scoliosis Using a Novel, Braided Vertebral Body Tethering Device: Minimum Follow-up of 4 Years. *JBJS Open Access.* 2019;12(4):e0026. doi: 10.2106/JBJS.OA.19.00026
15. Rushton PRP, Nasto L, Parent S, et al. Anterior Vertebral Body Tethering for Treatment of Idiopathic Scoliosis in the Skeletally Immature: Results of 112 Cases. *Spine (Phila Pa 1976).* 2021;46(21):1461–1467. doi: 10.1097/BRS.00000000000004061
16. Abdullah A, Parent S, Miyanji F, et al. Risk of early complication following anterior vertebral body tethering for Risk of early complication following anterior vertebral body tethering for idiopathic scoliosis. *Spine Deform.* 2021;9(5):1419–1431. doi: 10.1007/s43390-021-00326-2
17. Newton PO, Kluck DG, Saito W, et al. Anterior spinal growth tethering for skeletally immature patients with scoliosis: A retrospective look two to four years postoperatively. *J Bone Jt Surg Am.* 2018;100(19):1691–1697. doi: 10.2106/JBJS.18.00287
18. Samdani AF, Ames RJ, Kimball JS, et al. Anterior vertebral body tethering for immature adolescent idiopathic scoliosis: one-year results on the first 32 patients. *Eur spine J.* 2015;24(7):1533–1539. doi: 10.1007/s00586-014-3706-z
19. Pereverzev VS, Kolesov SV, Kazmin AI, Morozova NS, Shvets VV. Anterior dynamic versus posterior transpedicular spinal fusion for lenke type 5 idiopathic scoliosis: a comparison of long-term results. *Travmatologiya i ortopediya Rossii.* 2023;29(2):18–28. doi: 10.17816/2311-2905-3189
20. Kuleshov AA, Vetrile ST, Zhestkov KG, Guseinov VG, Vetrile MS. surgical treatment of scoliosis during the period of uncompleted spine growth. *N.N. Priorov Journal of Traumatology and Orthopedics.* 2010;(1):9–16. EDN: MBCMBV
21. Yang MJ, Samdani AF, Pahys JM, et al. What Happens After a Vertebral Body Tether Break? Incidence, Location, and Progression With Five-year Follow-up. *Spine (Phila Pa 1976).* 2023;48(11):742–747. doi: 10.1097/BRS.0000000000004665
22. Trobisch P, Baroncini A, Berrer A, Da Paz S. Difference between radiographically suspected and intraoperatively confirmed tether breakages after vertebral body tethering for idiopathic scoliosis. *Eur Spine J.* 2022;31(4):1045–1050. doi: 10.1007/s00586-021-07107-5
23. Betz RR, Ranade A, Samdani AF, et al. Vertebral Body Stapling A Fusionless Treatment Option for a Growing Child With Moderate Idiopathic Scoliosis. *Spine (Phila Pa 1976).* 2010;35(2):169–176. doi: 10.1097/BRS.0b013e3181c6dff5
24. Pehlivanoglu T, Oltulu I, Ender O, Sarioglu E. Thoracoscopic Vertebral Body Tethering for Adolescent Idiopathic Scoliosis: A Minimum of 2 Years' Results of 21 Patients. *J Pediatr Orthop.* 2020;40(10):575–580. doi: 10.1097/BPO.0000000000001590
25. Halanski MA, Elfman CM, Cassidy JA, et al. Comparing results of posterior spine fusion in patients with AIS: Are two surgeons better than one? *J Orthop.* 2013;10(2):54–58. doi: 10.1016/j.jor.2013.03.001

## СПИСОК ЛИТЕРАТУРЫ

1. Newton P.O., Bartley C.E., Bastrom T.P., et al. Anterior spinal growth modulation in skeletally immature patients with idiopathic scoliosis: a com-parison with posterior spinal fusion at 2 to 5 years postoperatively // *J Bone Joint Surg Am.* 2020. Vol. 102, № 9. P. 769–777. doi: 10.2106/JBJS.19.01176
2. Pehlivanoglu T., Oltulu I., Erdag Y., et al. Comparison of clinical and functional outcomes of vertebral body tethering to posterior spinal fusion in patients with adolescent idiopathic scoliosis and evaluation of quality of life: preliminary results // *Spine Deform.* 2021. Vol. 9, № 4. P. 1175–1182. doi: 10.1007/s43390-021-00323-5
3. Bernard Ja., Bishop T., Herzog Ja., et al. Dual modality of vertebral body tethering // *Bone and Joint Open.* 2022. Vol. 3, № 2. P. 123–129. doi: 10.1302/2633-1462.32.bjo-2021-0120.r1
4. Antonacci C., Antonacci M., Bassett W., et al. Treatment of Mature/Maturing Patients with Adolescent Idiopathic Scoliosis (Sanders ≥5) Using a Unique Anterior Scoliosis Correction Technique // *Med Res Arch.* 2021. Vol. 9, № 12. doi: 10.18103/mra.v9i12.2632
5. Pehlivanoglu T., Oltulu I., Erdag Y., et al. Double-sided vertebral body tethering of double adolescent idiopathic scoliosis curves: radiographic outcomes of the first 13 patients with 2 years of follow-up // *Eur Spine J.* 2021. Vol. 30, № 7. P. 1896–1904. doi: 10.1007/s00586-021-06745-z
6. Hegde S.K., Venkatesan M., Akbari K.K., Badikillaya V.M. Efficacy of Anterior Vertebral Body Tethering in Skeletally Mature Children with Adolescent Idiopathic Scoliosis: A Preliminary Report // *Int J Spine Surg.* 2021. Vol. 15, № 5. P. 995–1003. doi: 10.14444/8122
7. Yucekul A., Akpunarli B., Durbas A., et al. Does vertebral body tethering cause disc and facet joint degeneration? A preliminary MRI study with minimum 2-years follow-up // *Spine J.* 2021. Vol. 21, № 11. P. 1793–1801. doi: 10.1016/j.spinee.2021.05.020
8. Колесов С.В., Переверзев В.С., Пантелеев А.А., и др. Первый опыт вентральной динамической коррекции сколиозов у подростков с законченным ростом и взрослых: хирургическая техника и ближайшие результаты // *Хирургия позвоночника.* 2021. Т. 18, № 3. С. 19–29. doi: 10.14531/ss2021.3.19-29
9. Crawford C.H., Lenke L.G. Growth modulation by means of anterior tethering resulting in progressive correction of juvenile idiopathic scoliosis: A case report // *J Bone Jt Surg Am.* 2010. Vol. 92, № 1. P. 202–209. doi: 10.2106/JBJS.H.01728

10. Samdani A.F., Ames R.J., Kimball J.S., et al. Anterior vertebral body tethering for idiopathic scoliosis: two-year results // *Spine (Phila Pa 1976)*. 2014. Vol. 39, № 20. P. 1688–1693. doi: 10.1097/BRS.0000000000000472
11. Raitio A., Syvänen J., Helenius I. Vertebral Body Tethering: Indications, Surgical Technique, and a Systematic Review of Published Results // *J Clin Med*. 2022. Vol. 11, № 9. P. 2576. doi: 10.3390/jcm11092576
12. Baroncini A., Trobisch P.D., Migliorini F. Learning curve for vertebral body tethering: analysis on 90 consecutive patients // *Spine Deform*. 2021. Vol. 9, № 1. P. 141–147. doi: 10.1007/s43390-020-00191-5
13. Alanay A., Yucekul A., Abul K., et al. Thoracoscopic Vertebral Body Tethering for Adolescent Idiopathic Scoliosis: Follow-up Curve Behavior According to Sanders Skeletal Maturity Staging // *Spine (Phila Pa 1976)*. 2020. Vol. 45. P. E1483–E1492.
14. Wong H.K., Ruiz J.N.M., Newton P.O., Gabriel Liu K.P. Non-Fusion Surgical Correction of Thoracic Idiopathic Scoliosis Using a Novel, Braided Vertebral Body Tethering Device: Minimum Follow-up of 4 Years // *JBJS Open Access*. 2019. Vol. 12, № 4. P. e0026. doi: 10.2106/JBJS.OA.19.00026
15. Rushton P.R.P., Nasto L., Parent S., et al. Anterior Vertebral Body Tethering for Treatment of Idiopathic Scoliosis in the Skeletally Immature: Results of 112 Cases // *Spine (Phila Pa 1976)*. 2021. Vol. 46, № 21. P. 1461–1467. doi: 10.1097/BRS.00000000000004061
16. Abdullah A., Parent S., Miyajji F., et al. Risk of early complication following anterior vertebral body tethering for Risk of early complication following anterior vertebral body tethering for idiopathic scoliosis // *Spine Deform*. 2021. Vol. 9, № 5. P. 1419–1431. doi: 10.1007/s43390-021-00326-2
17. Newton P.O., Kluck D.G., Saito W., et al. Anterior spinal growth tethering for skeletally immature patients with scoliosis: A retrospective look two to four years postoperatively // *J Bone Jt Surg Am*. 2018. Vol. 100, № 19. P. 1691–1697. doi: 10.2106/JBJS.18.00287
18. Samdani A.F., Ames R.J., Kimball J.S., et al. Anterior vertebral body tethering for immature adolescent idiopathic scoliosis: one-year results on the first 32 patients // *Eur spine J*. 2015. Vol. 24, № 7. P. 1533–1539. doi: 10.1007/s00586-014-3706-z
19. Переверзев В.С., Колесов С.В., Казьмин А.И., Морозова Н.С., Швец В.В. Вентральная динамическая или дорсальная транспедикулярная коррекция и фиксация при хирургическом лечении идиопатического сколиоза типа Lenke 5: сравнение отдалённых результатов // *Травматология и ортопедия России*. 2023. Т. 29, № 2. С. 18–28. doi: 10.17816/2311-2905-3189
20. Кулешов А.А., Ветрилэ С.Т., Жестков К.Г., Гусейнов В.Г., Ветрилэ М.С. Хирургическое лечение сколиоза в период незавершённого роста позвоночника // *Вестник травматологии и ортопедии им. Н.Н. Приорова*. 2010. № 1. С. 9–16. EDN: MBCMBV
21. Yang M.J., Samdani A.F., Pahys J.M., et al. What Happens After a Vertebral Body Tether Break? Incidence, Location, and Progression With Five-year Follow-up // *Spine (Phila Pa 1976)*. 2023. Vol. 48, № 11. P. 742–747. doi: 10.1097/BRS.00000000000004665
22. Trobisch P., Baroncini A., Berrer A., Da Paz S. Difference between radiographically suspected and intraoperatively confirmed tether breakages after vertebral body tethering for idiopathic scoliosis // *Eur Spine J*. 2022. Vol. 31, № 4. P. 1045–1050. doi: 10.1007/s00586-021-07107-5
23. Betz R.R., Ranade A., Samdani A.F., et al. Vertebral Body Stapling A Fusionless Treatment Option for a Growing Child With Moderate Idiopathic Scoliosis // *Spine (Phila Pa 1976)*. 2010. Vol. 35, № 2. P. 169–176. doi: 10.1097/BRS.0b013e3181c6dff5
24. Pehlivanoglu T., Oltulu I., Ender O., Sarioglu E. Thoracoscopic Vertebral Body Tethering for Adolescent Idiopathic Scoliosis: A Minimum of 2 Years' Results of 21 Patients // *J Pediatr Orthop*. 2020. Vol. 40, № 10. P. 575–580. doi: 10.1097/BPO.0000000000001590
25. Halanski M.A., Elfman C.M., Cassidy J.A., et al. Comparing results of posterior spine fusion in patients with AIS: Are two surgeons better than one? // *J Orthop*. 2013. Vol. 10, № 2. P. 54–58. doi: 10.1016/j.jor.2013.03.001

## AUTHORS' INFO

**Sergei V. Kolesov**, MD, Dr. Sci. (Med.), professor;  
ORCID: 0000-0002-4252-1854;  
eLibrary SPIN: 1989-6994;  
e-mail: dr-kolesov@yandex.ru

\* **Vladimir S. Pereverzev**;  
address: 10 Priorova str., 127299 Moscow, Russia;  
ORCID: 0000-0002-6895-8288;  
eLibrary SPIN: 8164-1389;  
e-mail: vcpereverz@gmail.com

**Arkadii I. Kazmin**, MD, Cand. Sci. (Med.);  
ORCID: 0000-0003-2330-0172;  
eLibrary SPIN: 4944-4173;  
e-mail: kazmin.cito@mail.ru

**Nataliya S. Morozova**, MD, Cand. Sci. (Med.);  
ORCID: 0000-0001-7448-3904;  
eLibrary SPIN: 4593-3231;  
e-mail: morozcito@gmail.com

## ОБ АВТОРАХ

**Колесов Сергей Васильевич**, д-р мед. наук, профессор;  
ORCID: 0000-0002-4252-1854;  
eLibrary SPIN: 1989-6994;  
e-mail: dr-kolesov@yandex.ru

\* **Переверзев Владимир Сергеевич**;  
адрес: Россия, 127299, Москва, ул. Приорова, 10;  
ORCID: 0000-0002-6895-8288;  
eLibrary SPIN: 8164-1389;  
e-mail: vcpereverz@gmail.com

**Казьмин Аркадий Иванович**, канд. мед. наук;  
ORCID: 0000-0003-2330-0172;  
eLibrary SPIN: 4944-4173;  
e-mail: kazmin.cito@mail.ru

**Морозова Наталия Сергеевна**, канд. мед. наук;  
ORCID: 0000-0001-7448-3904;  
eLibrary SPIN: 4593-3231;  
e-mail: morozcito@gmail.com

\* Corresponding author / Автор, ответственный за переписку

**Vladimir V. Shvec**, MD, Dr. Sci. (Med.);

ORCID: 0000-0001-8884-2410;

e-mail: vshvetcv@yandex.ru

**Michail S. Raspopov**;

ORCID: 0009-0005-9517-7347;

e-mail: mihail.raspopov74@mail.com

**Samir B. Bagirov**;

ORCID: 0000-0003-1038-1815;

eLibrary SPIN: 9620-7038;

e-mail: bagirov.samir22@gmail.com

**Швец Владимир Викторович**, д-р мед. наук;

ORCID: 0000-0001-8884-2410;

e-mail: vshvetcv@yandex.ru

**Распов Михаил Сергеевич**;

ORCID: 0009-0005-9517-7347;

e-mail: mihail.raspopov74@mail.com

**Багиров Самир Бюкиши оглы**;

ORCID: 0000-0003-1038-1815;

eLibrary SPIN: 9620-7038;

e-mail: bagirov.samir22@gmail.com