

DOI: <https://doi.org/10.17816/vto636328>

EDN: NDIHQA



Single-Stage Treatment of Chronic Subtalar Dislocation: A Case Report

Miodrag Vranješ^{1, 2}, Kristian Dudaš², Predrag Rašović^{1, 2}¹ University of Novi Sad, Novi Sad, Serbia;² Clinical Center of Vojvodina, Clinic for Orthopedic Surgery and Traumatology, Novi Sad, Serbia

ABSTRACT

BACKGROUND: Chronic subtalar dislocation can develop in patients with severe, long-standing flatfoot or in those with neuroarthropathy or neglected trauma. We report a rare case of chronic subtalar dislocation, wherein treatment was effectively performed employing subtalar joint complex arthrodesis, involving the talo-navicular and talo-calcaneal joints and cuboido-talar pseudoarthrosis.

CLINICAL CASE DESCRIPTION: A 55-year-old female patient was referred to the specialist orthopedic clinic with complaints of progressively worsening right ankle pain for 12 months. She had been diagnosed with acquired flatfoot five years prior, which had since deteriorated. Computed tomography revealed lateral dislocations of both the subtalar and talonavicular joints. A single-stage surgery using cannulated screws was performed for achieving arthrodesis. Within just 4.5 months of this procedure, the patient was able to bear weight and walk independently.

CONCLUSION: Incorporating talo-cuboid fusion is crucial for a stable outcome. The outcome seems to be unaffected by subtalar dislocation duration, provided the soft tissue and skin coverage are manageable.

Keywords: chronic subtalar dislocation; arthrodesis; adult acquired flatfoot deformity.

To cite this article:

Vranješ M, Dudaš K, Rašović P. Single-stage treatment of a chronic subtalar dislocation: a case report. *N.N. Priorov Journal of Traumatology and Orthopedics*. 2025;32(2):487–492. DOI: 10.17816/vto636328 EDN: NDIHQA

Received: 21.09.2024

Accepted: 09.12.2024

Published online: 26.05.2025

DOI: <https://doi.org/10.17816/vto636328>

EDN: NDIHQQA

Одноэтапное лечение хронического подтаранного вывиха: клинический случай

Миодраг Враньеш^{1, 2}, Кристиан Дудаш², Предраг Рашович^{1, 2}¹ Нови-Садский университет, Нови-Сад, Сербия;² Клинический центр Воеводина, Клиника ортопедической хирургии и травматологии, Нови-Сад, Сербия

АННОТАЦИЯ

Обоснование. Хроническая форма подтаранного вывиха наблюдается в тяжёлых запущенных случаях декомпенсированного плоскостопия либо может быть связана с нейроартропатией или нелеченой травмой. Мы представляем редкий случай, эффективно вылеченный с помощью артродеза комплекса подтаранного сустава, включающего тало-навикулярный, тало-кальканеальный суставы и кубовидно-таранный псевдоартрит.

Описание клинического случая. 55-летняя женщина была направлена в специализированную ортопедическую клинику с 12-месячным прогрессированием боли в области голеностопного сустава. Пять лет назад ей был поставлен диагноз приобретённого плоскостопия, которое с тех пор усугублялось. Компьютерная томография выявила латеральный вывих стопы как в подтаранном, так и в тало-навикулярном суставе. Была проведена одноэтапная хирургическая операция с использованием канюлированных винтов для выполнения артродеза. Эта процедура позволила пациентке опираться на ногу и ходить самостоятельно уже через 4,5 месяца.

Заключение. Формирование костного сращения в области контакта между таранной и кубовидной костью является ключевым для достижения стабильного результата. Продолжительность подтаранного вывиха стопы, по-видимому, не оказывает значительного влияния на исход, если мягкие ткани и кожные покровы остаются в удовлетворительном состоянии.

Ключевые слова: хронический подтаранный вывих; артродез; деформация приобретённого плоскостопия у взрослых.

Как цитировать:

Враньеш М., Дудаш К., Рашович П. Одноэтапное лечение хронического подтаранного вывиха: клинический случай // Вестник травматологии и ортопедии им. Н.Н. Приорова. 2025. Т. 32, № 2. С. 487–492. DOI: 10.17816/vto636328 EDN: NDIHQQA

BACKGROUND

A relatively uncommon deformity, isolated lateral dislocation of the subtalar joint, is reported to typically result from trauma [1]. Talar dislocations are rare and often described as neglected or linked to an initial fracture [2]. Chronic subtalar dislocation can develop in severe, long-standing cases of flatfoot, such as adult-acquired flatfoot deformity (AAFD) stage III, or in association with Charcot neuroarthropathy [3], both of which are conditions that considerably diminish quality of life.

In the few studies that have documented chronic subtalar dislocation treatment [2, 4, 5] all patients underwent surgery employing either a transplatar nail for complete joint fusion [2, 6], or spatial frames [7], or a combination of both techniques [4]. Corrections were typically administered over multiple successive operations [6], although rarely, they could also be performed in one [5, 6].

We describe an unusual case of a chronic lateral subtalar dislocation without associated fracture, trauma, or Charcot neuroarthropathy, which was managed with a single-stage

operative procedure to restore pain-free weight bearing and ambulation.

CLINICAL CASE DESCRIPTION

A 55-year-old female patient with rheumatoid arthritis, asthma, and hypertension was referred to the specialist orthopedic clinic by her primary physician due to a 12-month history of progressive right ankle pain and challenges with walking. She denied any history of recent trauma to the affected ankle. Notably, she was diagnosed with acquired flatfoot more than five years ago, which had since deteriorated, resulting in chronic deformity of the left foot and ankle. Upon examination, she exhibited an antalgic gait with signs of discomfort. Although no neurovascular abnormalities were detected, her left foot and ankle demonstrated a pronounced valgus deformity. Notably, the severe valgus deformity caused pronounced skin tension over the medial malleolus, accompanied by skin atrophy and ulceration (Fig. 1). Plain radiographs revealed gross sclerosis and disorganization of foot bones, with medial dislocation of the tarsus, as well as

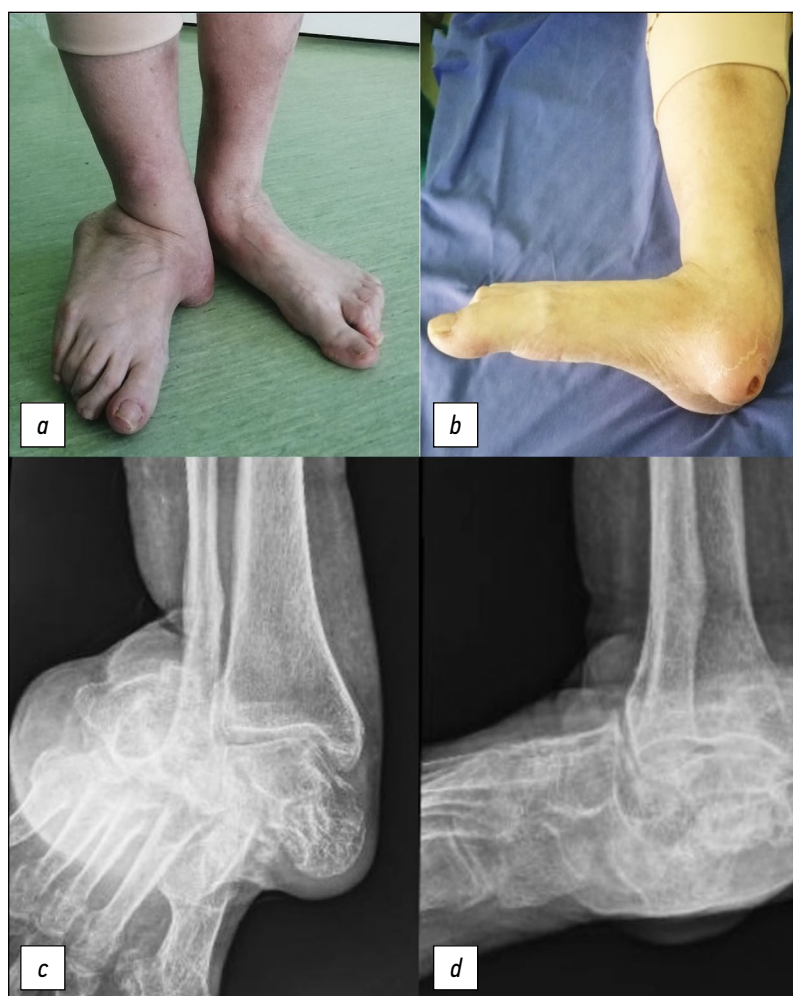

Fig. 1. Clinical image and plain radiography at presentation: anteroposterior (*a* and *c*) and lateral (*b* and *d*) views.

Рис. 1. Клиническая картина и обзорная рентгенография при поступлении: передне-задний (*a* и *c*) и боковой (*b* и *d*) вид.

associated lateral dislocation of the calcaneum and cuboid (Fig. 1).

The computed tomography (CT) scan with 3D reconstruction revealed findings consistent with plain radiographs obtained at hospital admission. Specifically, it confirmed lateral dislocations of both the subtalar and talonavicular joints. Although there was slight fragmentation, the talus demonstrated no deformation. However, the remaining talo-navicular and talo-calcaneal contact sites exhibited significant arthrosis and cyst formation. Additionally, pseudoarticulations were noted between the calcaneum and fibula (Fig. 2).

Considering the chronicity and severity of the bony deformities and soft tissue involvement, a one-stage procedure was planned. To restore pain-free weight bearing and ambulation, talo-calcaneo-cuboido-navicular fusion was performed employing a two-sided surgical approach (Fig. 2). The soft tissue contractures surrounding the bones were released. In the fusion procedure, four screws were utilized to secure the talus, calcaneus, cuboid, and navicular bones together. Initially, a single 4.5-mm cannulated screw was used to perform a talo-navicular fixation. Subsequently, subtalar fixation was achieved employing two 6.5 mm cannulated screws. Finally, a cuboidotalar fixation was established using a second 4.5 mm cannulated screw (Fig. 3).

The surfaces of this pathological joint were prepared by excising the cartilage and then filled with frozen cancellous allograft. Eventually, both surgical wounds healed successfully. The lateral wound required an additional two months for complete closure due to the presence of a localized area of skin necrosis. During this period, a non-weight-bearing status was maintained for three months. For the first two months, the patient was immobilized in a back slab; after that, a walking boot was used. Full weight-bearing activity was progressively resumed after three months. Physiotherapy was initiated after 3.5 months. The patient achieved her goal of independent weight bearing and ambulation 4.5 months following the reconstructive process, with satisfactory cosmetic and functional stability in her foot and ankle (Fig. 3).

DISCUSSION

Surgical correction of chronic foot and ankle deformities, whether in patients with diabetes or in those without, remains a formidable challenge due to the persistently high incidence of complications [6, 7].

The underlying etiology of this clinical condition may be related to the long-standing posterior tibial tendon dysfunction (PTTD). Clinical evidence repeatedly outlines the typical pattern of case development [5, 8, 9]. However, the presence of PTTD has not been confirmed by

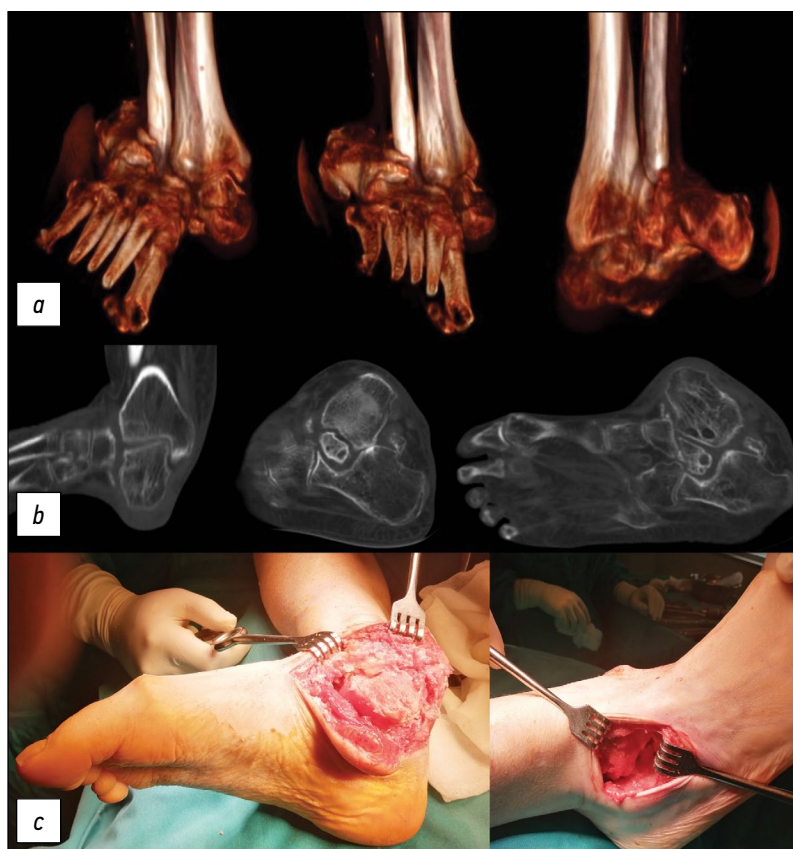


Fig. 2. Preoperative CT with 3D reconstruction (a and b) and intraoperative clinical images of the medial and lateral approaches (c).

Рис. 2. Предоперационная КТ с 3D-реконструкцией (a и b) и интраоперационные клинические снимки медиального и латерального доступов (c).

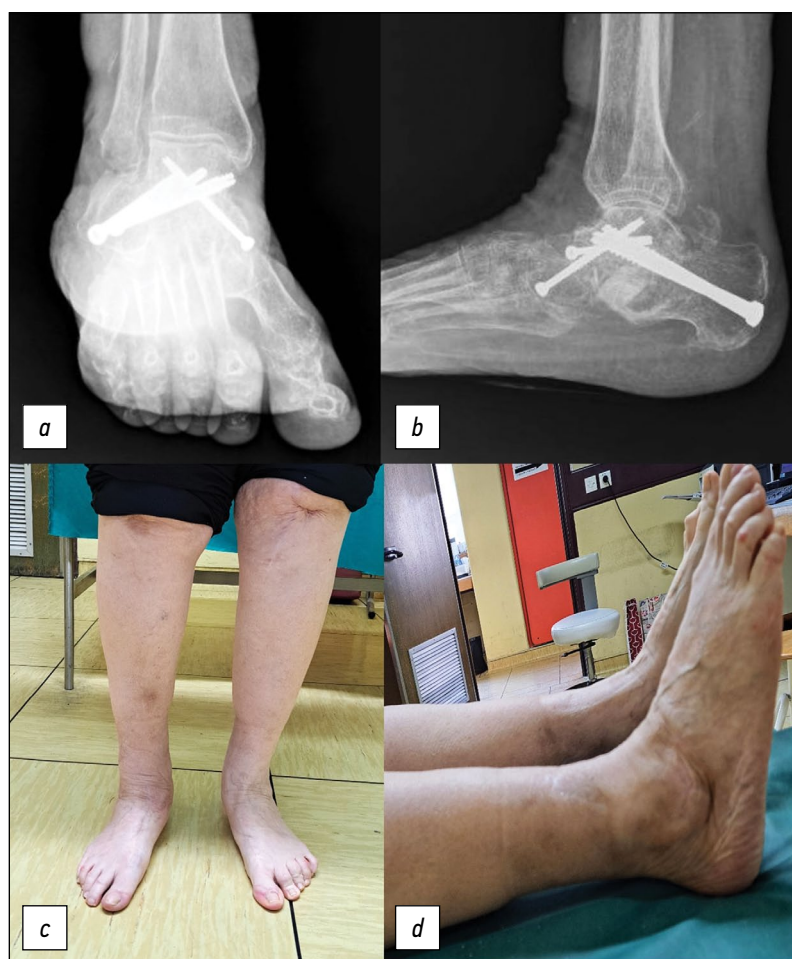

Fig. 3. Plain radiographs and clinical images six months following the procedure: anteroposterior (*a* and *c*) and lateral (*b* and *d*) views.

Рис. 3. Обзорные рентгенограммы и клиническая картина через 6 месяцев после вмешательства: передне-задний (*a* и *c*) и боковой (*b* и *d*) вид.

magnetic resonance imaging studies. We decided against investigating PTTD surgically because it would not have influenced our treatment strategy, and further tissue damage could have impeded the already compromised skin's healing process.

Our patient had been living with a deformity for five years prior to undergoing surgery, consistent with the duration of a previously reported case [5]. Although Chan et al. [4] reported that their patient had experienced medial subtalar dislocation and ankle injury ten years prior to surgery; however, they did not indicate when the irreversible subtalar dislocation occurred. We believe that even if the subtalar dislocation had occurred only a few years ago, our surgical approach would remain unchanged.

The surgical technique employed in this uncommon case has not been previously documented. Tonogai et al. [5] performed a similar operation, but without talo-cuboid fusion. We believe the effectiveness of this surgical procedure depends on increasing the area of contact between the talus and the midfoot. The patient exhibited persistent flatfoot postoperatively, similar to the previous study. At the one-year follow-up, however, our patient expressed satisfaction with the surgical procedure and denied experiencing any

pain while walking. Moreover, after such an extended period of subtalar dislocation, there is a significant possibility that a triple arthrodesis — which includes calcaneo-cuboid arthrodesis to address AAFD — may not provide the desired firmness to the foot.

CONCLUSION

Chronic lateral subtalar dislocation, in the absence of other comorbidities, can be treated with a single-stage surgical procedure. Incorporating a talo-cuboid fusion is crucial for ensuring a stable operative outcome. As long as the soft tissue and skin coverage are manageable, the operative outcome remains unaffected by the duration of the chronic subtalar dislocation.

ADDITIONAL INFO

Author contribution. All authors have approved the final version before publication and have also agreed to be responsible for all aspects of the work, ensuring that issues relating to the accuracy and integrity of any part of it are properly addressed and resolved.

Funding sources. No funding.

Disclosure of interests. The authors declare the absence of relationships, activities and interests (personal, professional or financial) related to third parties (commercial, non-profit, private), whose interests may be affected by the content of the article, as well as other relationships, activities and interests over the past three years, which must be reported.

Statement of originality. The authors did not use previously published information (text, data) to create this paper.

Generative AI. Generative AI technologies were not used for this article creation.

Provenance and peer-review. This paper was submitted to the journal on an initiative basis and reviewed according to the usual procedure. Two external reviewers, a member of the editorial board and the scientific editor of the publication participated in the review.

Informed consent for publication. The authors obtained a written consent prior to surgery (Feb 2, 2023) from the patient for the publication of medical data and photographs.

ДОПОЛНИТЕЛЬНАЯ ИНФОРМАЦИЯ

Вклад авторов. Все авторы одобрили финальную версию перед публикацией, а также согласились нести ответственность за все аспекты

работы, гарантируя надлежащее рассмотрение и решение вопросов, связанных с точностью и добросовестностью любой её части.

Источники финансирования. Отсутствуют.

Раскрытие интересов. Авторы заявляют об отсутствии отношений, деятельности и интересов (личных, профессиональных или финансовых), связанных с третьими лицами (коммерческими, некоммерческими, частными), интересы которых могут быть затронуты содержанием статьи, а также иных отношений, деятельности и интересов за последние три года, о которых необходимо сообщить.

Оригинальность. При создании настоящей работы авторы не использовали ранее опубликованные сведения (текст, данные).

Генеративный искусственный интеллект. При создании настоящей статьи технологии генеративного искусственного интеллекта не использовали.

Рассмотрение и рецензирование. Настоящая работа подана в журнал в инициативном порядке и рассмотрена по обычной процедуре. В рецензировании участвовали два внешних рецензента, член редакционной коллегии и научный редактор издания.

Информированное согласие на публикацию. Авторы получили письменное согласие пациентки до операции (02.02.2023 г.) на публикацию медицинских данных и фотографий.

СПИСОК ЛИТЕРАТУРЫ | REFERENCES

1. Abdullah A, Mohannad A, Faisal A, et al. Isolated Subtalar Dislocations: Insights from a Case Study and Literature Review. *Med Arch*. 2024;78(1):71–4. doi: 10.5455/medarch.2024.78.71–74
2. Bajuri MY, Johan RR, Bahari SI. Neglected subtalar dislocation with unstable foot; to walk away or step our foot in? *BMJ Case Rep*. 2013;2013:bcr2012007697. doi: 10.1136/bcr-2012-007697
3. Dr E, Tm L, Pr B. Surgical Treatment and Management for Chronic Dislocated Subtalar Joint. The Journal of foot and ankle surgery: official publication of the American College of Foot and Ankle Surgeons [Internet]. 2020 Apr [cited 2024 Mar 25];59(2). Available from: <https://pubmed.ncbi.nlm.nih.gov/32131006/>
4. Chan MC, Khan SA, Tan JG. Reconstruction of Chronic Subtalar Dislocation. *Strategies in Trauma and Limb Reconstruction*. 2019;14(1):53–56. doi: 10.5005/jp-journals-10080-1412
5. Tonogai I, Sairyo K. Arthrodesis for chronic lateral subtalar joint dislocation caused by posterior tibial tendon dysfunction: A case

- report. *International Journal of Surgery Case Reports*. 2021;78:21–5. doi: 10.1016/j.ijscr.2020.11.136
6. Elbert DR, Langan TM, Burns PR. Surgical Treatment and Management for Chronic Dislocated Subtalar Joint. *J Foot Ankle Surg*. 2020;59(2):379–84. doi: 10.1053/j.jfas.2019.08.011
7. Liu J, Slotkin S, Zeni F. Staged Treatment of Chronic Locked Fracture-Dislocation of the Calcaneus: A Case Report. *JBJS Case Connect*. 2019;9(4):e0233. doi: 10.2106/JBJS.CC.18.00233
8. Elomrani NF, Kasis AG, Tis JE, Saleh M. Outcome after foot and ankle deformity correction using circular external fixation. *Foot Ankle Int*. 2005;26(12):1027–32. doi: 10.1177/107110070502601205
9. Apostle KL, Coleman NW, Sangeorzan BJ. Subtalar joint axis in patients with symptomatic peritalar subluxation compared to normal controls. *Foot Ankle Int*. 2014;35(11):1153–8. doi: 10.1177/1071100714546549

AUTHORS' INFO

* Miodrag Vranješ;

ORCID: 0000-0002-0642-4942;

e-mail: miodrag.vranjes@mf.uns.ac.rs

Kristian Dudaš;

e-mail: kristiand@gmail.com

Predrag Rašović;

ORCID: 0000-0003-4189-6395;

e-mail: predrag.rasovic@mf.uns.ac.rs

ОБ АВТОРАХ

* Миодраг Враньеш;

ORCID: 0000-0002-0642-4942;

e-mail: miodrag.vranjes@mf.uns.ac.rs

Кристиан Дудаш;

e-mail: kristiand@gmail.com

Предраг Рашович;

ORCID: 0000-0003-4189-6395;

e-mail: predrag.rasovic@mf.uns.ac.rs

* Corresponding author / Автор, ответственный за переписку