


DOI: <https://doi.org/10.17816/cardar71371>



# Postabaltive Pericarditis in Patient with a Prior History of Rheumatic Disease: a Case Report

Evgeny G. Zhelyakov<sup>1</sup>, Andrey V. Ardashev<sup>1</sup>, Armen A. Kocharian<sup>2</sup>, Mikhail L. Ginsburg<sup>3</sup>, Elena Daniels<sup>3</sup>

<sup>1</sup> Moscow State university named after M.V. Lomonosov, Moscow, Russian Federation;

<sup>2</sup> Federal Scientific and clinical centre of Biomedical Agency of Russia, Moscow, Russian Federation;

<sup>3</sup> Lubertsy Region Hospital №2, Moscow, Russian Federation

A 60 year-old male with a previous (40 years ago) history of rheumatic carditis without valve involvement and 5 years history of paroxysmal atrial fibrillation underwent ablation (PV isolation with roof and mitral isthmus lines). The following day patient developed AF episode with severe mid-sternal chest pain with widespread concave ST elevation throughout most of the limb leads (I, II, III, aVL, aVF) and precordial leads (V2-6). Serum troponin I was 87.2 ng/ml with a creatinine concentration of 0.88 mg/dl and hemoglobin level of 15 g/dl. 2D transthoracic echocardiogram excluded wall motion abnormalities, or significant pericardial effusions. Recurrence of acute rheumatic fever was excluded based on revised Jones criteria. Careful analysis of ECG allowed us to recognize the ECG criteria of pericarditis and to avoid unnecessary emergent coronary angiography. Ultimately, the patient was diagnosed with pericarditis. After diagnosis, the patient's presenting symptoms resolved with treatment including sotalol 160 mg per day, nonsteroidal anti-inflammatory agents.

**Conclusions:** This is the first reported case study of post-cardiac ablation pericarditis in patient with prior history of rheumatic carditis.

**Keywords:** Postabaltive Pericarditis; paroxysmal atrial fibrillation; ablation; complications of ablation.

**To cite this article:**

Zhelyakov EG, Ardashev AV, Kocharian AA, Ginsburg ML, Daniels E. Postabaltive pericarditis in patient with a prior history of rheumatic disease: a case report. *Cardiac Arrhythmias*. 2021;1(1):49–54. DOI: <https://doi.org/10.17816/cardar71371>

Received: 08.06.2021

Accepted: 07.07.2021

Published: 20.07.2021



DOI: <https://doi.org/10.17816/cardar71371>

## Случай развития перикардита после проведения радиочастотной абляции у пациента с предшествующим ревматическим анамнезом

Е.Г. Желяков<sup>1</sup>, А.В. Ардашев<sup>1</sup>, А.А. Кочарян<sup>2</sup>, М.Л. Гинзбург<sup>3</sup>, Е. Даниэльс<sup>3</sup><sup>1</sup> Медицинский научно-образовательный центр МГУ имени М.В. Ломоносова, Москва, Россия;<sup>2</sup> Федеральный Научно Клинический Центр ФМБА России, Москва, Россия;<sup>3</sup> Областная больница №2, Люберцы, Московская область, Россия

Представлен клинический случай развития острого перикардита после проведения радиочастотной абляции (РЧА) пароксизмальной фибрилляции предсердий (ФП) у 60-летнего мужчины с указаниями в анамнезе на перенесенный ранее (40 лет назад) ревматический кардит без поражения клапанов. Пациенту была выполнена РЧА в левом предсердии (изоляция устьев всех легочных вен, линейные воздействия в области свода и митрального перешейка). На следующий день у пациента развился эпизод ФП, сопровождавшийся выраженной болью в области грудины и изменениями на ЭКГ — подъемом сегмента ST в отведениях I, II, III, AVL, aVF и прекардиальных отведений (V2-6). Уровень тропонина I составлял 87,2 нг/мл, креатинина — 0,88 мг/дл, гемоглобина — 15 г/дл. Трансторакальная эхокардиография не выявила наличие значимого выпота в перикардальной сумке и участков гипо и акинеза миокарда левого желудочка. Рецидив острой ревматической лихорадки был исключен на основании пересмотренных критериев Джонса. Тщательный анализ ЭКГ позволил нам распознать ЭКГ-критерии перикардита и избежать ненужной экстренной коронарной ангиографии. В конечном счете пациенту был установлен диагноз перикардит. Пациенту было проведено лечение нестероидными противовоспалительными препаратами средства, которое привело к эффективному купированию болевого синдрома и разрешению воспалительного процесса в перикарде.

**Ключевые слова:** перикардит; ревматизм; фибрилляция предсердий; радиочастотная абляция.

### Как цитировать:

Желяков Е.Г., Ардашев А.В., Кочарян А.А., Гинзбург М.Л., Даниэльс Е. Случай развития перикардита после проведения радиочастотной абляции у пациента с предшествующим ревматическим анамнезом // Cardiac Arrhythmias. 2021. Т. 1, № 1. С. 51–56. DOI: <https://doi.org/10.17816/cardar71371>

## INTRODUCTION

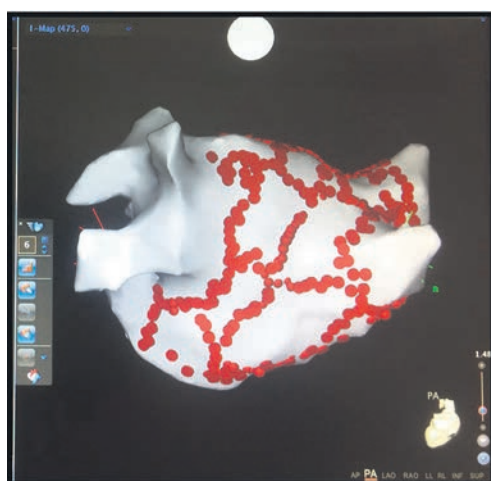
Nowadays catheter ablation of atrial fibrillation (AF) is the most effective rhythm control option. The benefits of their use in clinical practice far outweigh the potential risks associated with the complications. It is noteworthy that in the period from 2005 to 2012 (the so-called period of the development of the ablation technique), the overall incidence of complications linked with intervention was from 3.9 to 6% [1]. In the works published in recent years, there is a significant increase in the percentage of complications (from 10.5 to 16.3%) associated with the interventional treatment of AF [2]. This is due to the fact that in the early 2000s, complications of ablation were defined as conditions that led to irreversible consequences in the patient's clinical status (for example, stroke) or required urgent surgical and/or interventional intervention. Also among the possible explanations for the increase in the proportion of complications is the introduction into clinical practice of clear definitions of what should be considered a complication and their classification, published in 2012 [1]. No less interesting, in our opinion, is the evolution of the structure of complications. In particular, the number of cases of pulmonary venous stenosis has significantly decreased over the past 20 years, which is associated with the current trend towards antral ablation. It is noteworthy that the widespread introduction of the cryoablation method into clinical practice has led to the appearance of such complications that were previously extremely rare. From 2005 to 2018, there was at least a fourfold increase in the number of cases of diaphragmatic nerve palsy [3]. In particular, the data from the register of all catheter interventional interventions performed for AF in Germany in 2014 indicate that this complication occurred in 21 cases (0.4%) during cryoablation and in none when using radiofrequency energy [4].

It is also interesting that inflammatory changes in the pericardium associated with ablation have been registered as complications recently [5]. Moreover, in none of the cases described was there any mention of the patient's previous rheumatism.

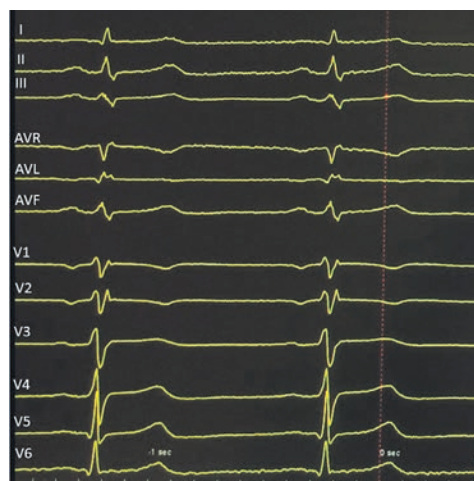
## CASE REPORT

60 years old male was admitted to our clinic on 03 March 2017 for ablation of symptomatic (EHRA-II) paroxysmal AF. Until 2017, combined antiarrhythmic therapy (sotalol 120 mg/day and allapinine 50 mg/day) allowed for effective control of sinus rhythm (AF paroxysms occurred 2-3 times a year). The patient noticed an increase in the frequency of AF events (2-3 episodes per month) in the last three months. The patient's medical history indicated a diagnosis of rheumatism established at the age of 20 (polyarthritis and rheumatic myocarditis). Subsequent dynamic follow-up by a rheumatologist, as well as repeated echocardiographic studies, did not reveal rheumatic signs of the heart valves. Before ablation we excluded an unstable variant of coronary artery disease, thyroid dysfunction and the activity of the rheumatic process. Patient was treated with anticoagulants (xarelto 20 mg/day) 1 month before the ablation.

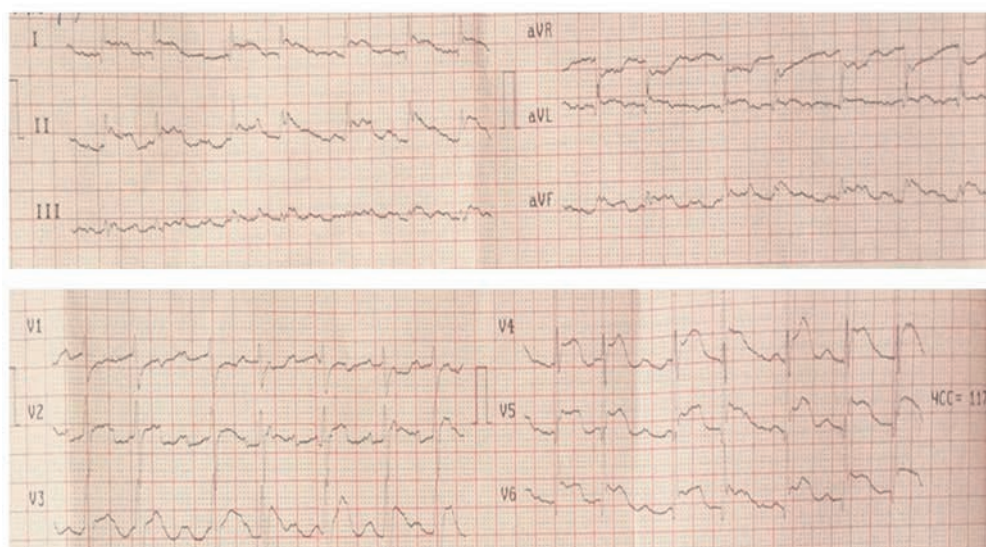
On 04.03.17, we performed ablation of AF using the CARTO system, which included antral isolation of all pulmonary veins, lines in the mitral isthmus and left atrial roof, as well as modification of the arrhythmia substrate at the posterior wall (Fig. 1). Transthoracic echocardiographic no revealed of pericardial effusion next morning and patient was discharged with recommendations for taking sotalol 80 mg/day, allapinine 25 mg at night and xarelto 20 mg. At discharge, the ECG recorded a sinus rhythm without changes in the ST segment (Fig. 2).



**Fig. 1.** 3-D reconstruction of the left atrium (posterior view). Brown dots are areas of ablation applications applied along the perimeter of all the pulmonary veins, of the mitral isthmus and the roof of the left atrium, as well as the modification of the substrate of the posterior wall of the left atrium.



**Fig. 2.** 12 surface ECG leads recorded at discharge from the hospital on the day after ablation



**Fig. 3.** 12 surface ECG leads registered at the onset of the pericarditis. Atrial fibrillation with a ventricular activation rate of 117 per minute. Note to the diffuse elevation of the ST segment, which is verified in all leads, with the exception of leads III, aVR and V1 without pathological Q waves and a reciprocal decrease in the ST segment. Also there is Spodick sign - a downward direction from the top of the T wave to the atrial fibrillation waves f (see leads I, II, V4-V6).

In the morning of 06 March 2017, the patient had a severe pain in the heart area and palpitations. ECG showed atrial flutter, ST segment elevation in leads I, II, AVL, as well as in the precordial leads (Fig. 3). The patient was admitted to the hospital with suspected acute myocardial infarction. Serum troponin I was 87.2 ng/ml, creatinine level of 0.88 mg/dl and hemoglobin level of 15 g/dl. 2D transthoracic echocardiography excluded wall motion abnormalities, or significant pericardial effusions (150 ml).

According to the results of the examination, the patient revealed exudative pericarditis. Careful ECG analysis allowed us to exclude the diagnosis of acute coronary syndrome. In this regard, it was decided not to perform coronarography.

Against the background of the therapy (xarelto 20 mg, sotalol 120 mg, spironolactone 25 mg, ibuprofen 600 mg, omeprazole 20 mg), the patient's condition improved: the sinus rhythm was restored, the blood pressure was in the range of 100–110/70 mmHg, heart rate 56 per minute. According to repeated transthoracic echocardiography the dynamics showed a decrease in pericardial effusion to 50 ml, the patient was discharged after 10 days. Subsequent clinical 1 and 3 month follow up after ablation did not reveal signs and symptoms of pericarditis or activation of the rheumatic process, although rare episodes of AF remained.

## DISCUSSION

### Complications of ablation

Today, catheter ablation is the most effective method of controlling sinus rhythm in patients with AF [6, 7].

The half of the patients after ablation of AF have a pericardial reaction [10] with a small amount of fluid in

the pericardium which manifest of discomfort in the chest area. As a rule, this symptoms resolve within the natural course of the postoperative period and is not considered as a complication of procedure. It is based on the development of limited pericarditis, which occurs as a result of transmural damage of the atrial myocardium and inflammation of the pericardium. Transthoracic echocardiography may verify a small amount of fluid in the pericardial cavity. This symptom usually resolves within the first few days after ablation without special treatment [1, 6]. Much less often pericarditis requires special treatment. According to the German national registry, which included 33,353 patients who had ablation for AF and/or typical atrial flutter, the diagnosis of pericarditis, which required special treatment, was established from 1.7 to 4% of cases [4]. As a rule, pericarditis can occur acutely (in the first days) after interventional intervention [5] or delayed (in the period from 18 days to 3 months) after RFA (Dressler syndrome) [8]. In most cases, the inflammatory reaction of the pericardium manifests itself in the form of effusive pericarditis, which can be complicated by cardiac tamponade. Isolated cases of constrictive pericarditis and pericarditis after hemotamponade resolution have been described [9]. An analysis of publications on RFA in patients with rheumatism indicates that the frequency of pericarditis does not differ from that in patients with a different etiology of arrhythmic syndrome [5, 8, 9].

### Differential diagnosis of acute pericarditis

The onset of acute pericarditis is often manifested by severe pain syndrome in the chest area and gives every reason to assume the possible development of a myocardial infarction with ST-segment elevation. In this regard, conducting a quick and correct differential diagnosis is key to choosing an adequate treatment strategy. In this publication,

we would like to focus the attention on ECG changes that occur in pericarditis, which are different from ECG signs of myocardial infarction with ST segment elevation [10]. A characteristic ECG manifestation of the initial phase of acute pericarditis is diffuse elevation of the ST segment, which is verified in almost all leads, with the exception of leads III, aVR, and V1, and indicates the involvement of the epicardium in the pathological process (subepicardial damage) (see Fig. 3). Another ECG sign of pericarditis is the appearance of similarity of leads I and II (see Fig. 3), whereas in lower myocardial infarction, leads II and III become similar. Attention is drawn to the appearance of the Spodick symptom — a downward direction from the top of the T wave to the P wave, which is often determined in many leads in patients with acute pericarditis. Against the background of sinus rhythm in pericarditis, there is a depression of the PR segment in most leads from the extremities and thoracic leads (a manifestation of atrial damage), with a rise in the PR segment in the AVR lead [11].

In contrast to ST-segment elevation myocardial infarction, acute pericarditis shows no foci of ST-segment changes, no Q-waves, and no reciprocal ST-segment decline.

In some cases, ECG signs of early repolarization syndrome may resemble changes in acute pericarditis (ST segment elevation with downward concavity and positive T teeth). The differential diagnostic criterion that allows us to distinguish these states from each other is the ratio of the ST segment elevation and the T wave amplitude in the V6 lead. If this value is  $> 0.25$ , then pericarditis is assumed, and if  $< 0.25$ , then early ventricular repolarization is assumed.

## CONCLUSION

Despite the tendency to reduce the frequency of complications associated with AF ablation, cardiologists should be wary of relapse of acute pericarditis as a differential diagnosis with rheumatic fever, especially in patients with a history of previous rheumatism.

## REFERENCES

- Hakalahti A, Biancari F, Nielsen JC, Raatikainen MJ. Radiofrequency ablation vs. antiarrhythmic drug therapy as first line treatment of symptomatic atrial fibrillation: systematic review and meta-analysis. *Europace*. 2015;17(3):370–378. DOI: 10.1093/europace/euu376
- Arbelo E, Brugada J, Blomstrom-Lundqvist C, et al. Contemporary management of patients undergoing atrial fibrillation ablation: in-hospital and 1-year follow-up findings from the ESC-EHRA atrial fibrillation ablation long-term registry. *Eur Heart J*. 2017;38(17):1303–1306. DOI: 10.1093/eurheartj/ehw564
- Miyazaki S, Tada H. Complications of cryoballoon pulmonary vein isolation. *Arrhythm Electrophysiol Rev*. 2019;8(1):60–64. DOI: 10.15420/aer.2018.72.2
- Schmidt M, Dorwarth U, Andresen D, et al. German ablation registry: Cryoballoon vs. radiofrequency ablation in paroxysmal atrial fibrillation—One-year outcome data. *Heart Rhythm*. 2016;13(4):836–844. DOI: 10.1016/j.hrthm.2015.12.007
- Orme J, Eddin M, Loli A. regional pericarditis status post cardiac ablation: a case report. *N Am J Med Sci*. 2014;6(9):481–483. DOI: 10.4103/1947-2714.141653
- Cappato R, Calkins H, Chen SA, et al. Updated worldwide survey on the methods, efficacy, and safety of catheter ablation for human atrial fibrillation. *Circ Arrhythm Electrophysiol*. 2010;3(1):32–38. DOI: 10.1161/CIRCEP.109.859116
- Packer DL, Mark DB, Robb RA, et al. Effect of catheter ablation vs antiarrhythmic drug therapy on mortality, stroke, bleeding, and cardiac arrest among patients with atrial fibrillation. The CABANA Randomized Clinical Trial. *JAMA*. 2019;321(13):1261–1274. DOI: 10.1001/jama.2019.0693
- Luckie M, Jenkins N, Davidson NC, Chauhan A. Dressler's syndrome following pulmonary vein isolation for atrial fibrillation. *Acute Card Care*. 2008;10(4):234–235. DOI: 10.1080/17482940701843722
- Troughton RW, Asher CR, Klein AL. Pericarditis. *Lancet*. 2004;363(9410):717–727. DOI: 10.1016/S0140-6736(04)15648-1
- Surawicz B, Lasserter KC. Electrocardiogram in pericarditis. *Am J Cardiol*. 1970;26(5):471–474. DOI: 10.1016/0002-9149(70)90704-6
- Spodick DH. Diagnostic electrocardiographic sequences in acute pericarditis: Significance of PR segment and PR vector changes. *Circulation*. 1973;48(3):575–580. DOI: 10.1161/01.cir.48.3.575

## СПИСОК ЛИТЕРАТУРЫ

- Hakalahti A., Biancari F., Nielsen J.C., Raatikainen M.J. Radiofrequency ablation vs. antiarrhythmic drug therapy as first line treatment of symptomatic atrial fibrillation: systematic review and meta-analysis // *Europace*. 2015. Vol. 17, No. 3. P. 370–378. DOI: 10.1093/europace/euu376
- Arbelo E., Brugada J., Blomstrom-Lundqvist C. et al. Contemporary management of patients undergoing atrial fibrillation ablation: in-hospital and 1-year follow-up findings from the ESC-EHRA atrial fibrillation ablation long-term registry // *Eur. Heart J*. 2017. Vol. 38, No. 17. P. 1303–1306. DOI: 10.1093/eurheartj/ehw564
- Miyazaki S., Tada H. Complications of cryoballoon pulmonary vein isolation // *Arrhythm. Electrophysiol. Rev*. 2019. Vol. 8, No. 1. P. 60–64. DOI: 10.15420/aer.2018.72.2
- Schmidt M., Dorwarth U., Andresen D. et al. German ablation registry: Cryoballoon vs. radiofrequency ablation in paroxysmal atrial

- fibrillation One-year outcome data // *Heart Rhythm*. 2016. Vol. 13, No. 4. P. 836–844. DOI: 10.1016/j.hrthm.2015.12.007
5. Orme J., Eddin M., Loli A. regional pericarditis status post cardiac ablation: a case report // *N. Am. J. Med. Sci.* 2014. Vol. 6, No. 9. P. 481–483. DOI: 10.4103/1947-2714.141653
6. Cappato R., Calkins H., Chen S.A. et al. Updated worldwide survey on the methods, efficacy, and safety of catheter ablation for human atrial fibrillation // *Circ. Arrhythm. Electrophysiol.* 2010. Vol. 3, No. 1. P. 32–38. DOI: 10.1161/CIRCEP.109.859116
7. Packer D.L., Mark D.B., Robb R.A. et al. Effect of catheter ablation vs antiarrhythmic drug therapy on mortality, stroke, bleeding, and cardiac arrest among patients with atrial fibrillation. The CABANA Randomized Clinical Trial // *JAMA*. 2019. Vol. 321, No. 13. P. 1261–1274. DOI: 10.1001/jama.2019.0693
8. Luckie M., Jenkins N., Davidson N.C., Chauhan A. Dressler's syndrome following pulmonary vein isolation for atrial fibrillation // *Acute Card. Care*. 2008. Vol. 10, No. 4. P. 234–235. DOI: 10.1080/17482940701843722
9. Troughton R.W., Asher C.R., Klein A.L. Pericarditis // *Lancet*. 2004. Vol. 363, No. 9410. P. 717–727. DOI: 10.1016/S0140-6736(04)15648-1
10. Surawicz B., Lasseter K.C. Electrocardiogram in pericarditis // *Am. J. Cardiol.* 1970. Vol. 26, No. 5. P. 471–474. DOI: 10.1016/0002-9149(70)90704-6
11. Spodick D.H. Diagnostic electrocardiographic sequences in acute pericarditis: Significance of PR segment and PR vector changes // *Circulation*. 1973. Vol. 48, No. 3. P. 575–580. DOI: 10.1161/01.cir.48.3.575

## AUTHORS INFO

**\*Evgeny G. Zhelyakov**, MD, e-mail: zheleu@rambler.ru;  
ORCID: 0000-0003-1865-8102

**Andrey V. Ardashev**, doctor of medical sciences, professor;  
e-mail: ardashev@yahoo.com; SPIN: 9336-4712

**Armen A. Kocharian**, MD;  
e-mail: armenkocharian@yandex.ru;  
ORCID: 0000-0001-7937-4686

**Mikhail L. Ginsburg**, doctor of medical sciences;  
e-mail: ginsburgMikh@mail.ru

**Elena Daniels**, physician; e-mail: elenadahiels@yandex.ru

## ОБ АВТОРАХ

**\*Евгений Геннадьевич Желяков**, кандидат медицинских наук; e-mail: zheleu@rambler.ru; ORCID: 0000-0003-1865-8102

**Андрей Вячеславович Ардашев** доктор медицинских наук, профессор; e-mail: ardashev@yahoo.com; SPIN-код: 9336-4712

**Кочарян Армен Артурович** врач хирург;  
e-mail: armenkocharian@yandex.ru;  
ORCID: 0000-0001-7937-4686

**Гинзбург Михаил Львович**, доктор медицинских наук;  
e-mail: ginsburgMikh@mail.ru

**Елена Даниэльс**, врач; e-mail: elenadahiels@yandex.ru

\* Corresponding author / Автор, ответственный за переписку