

DOI: <https://doi.org/10.17816/OV630330>

Comparative study of orbital volumes according to multispiral computed tomography data

Dmitry V. Davydov¹, Natalia S. Serova², Olga A. Kakorina², Olga Yu. Pavlova²¹ National Medical Research Radiological Center, Moscow, Russia;² I.M. Sechenov First Moscow State Medical University (Sechenov University), Moscow, Russia

ABSTRACT

BACKGROUND: It is believed that accurate reconstruction of the correct anatomy of the orbital bony walls, restoration of symmetry and volume are necessary for a favorable functional prognosis and elimination of an aesthetic defect. The main problem when estimating orbital volume is its complex anatomy. Scientists use various methods to determine orbital volume, and in reviews comparing various methods for calculating orbital volumes, there is no data on which orbital volumetric method is the most accurate, since each of them has both advantages and disadvantages.

AIM: The aim of this study is the analysis and the comparison of orbital volumes according to multispiral computed tomography data of healthy patients without bone-traumatic changes of orbital walls.

MATERIALS AND METHODS: To measure the volume of orbits, 50 random patients were selected who were examined in the radiology department No. 2 of the University Clinical Hospital No. 1 of the Sechenov University from 2023 to 2024 and who underwent multispiral computed tomography of the facial skeleton for indications unrelated to orbital conditions. Computed tomography data from 25 women and 25 men of different ages (from 18 to 85 years old) were analyzed. A total of 8 groups were formed depending on gender and age: group 1 — women 18–25 years old, group 2 — men 18–25 years old, group 3 — women 26–35 years old, group 4 — men 26–35 years old, group 5 — women 36–50 years old, group 6 — men 36–50 years old, group 7 — women 51 and older, group 8 — men 51 and older. Multispiral computed tomography of the facial skeleton was performed using the Aquilion One 640 CT scanner (Japan) with 0.5 slice thickness in bone and soft tissue windows, to be able to calculate orbital volumes at the workstation, all bone contours of the orbits were marked on each axial slice, starting from the upper wall to the bottom of the orbit with a representation of the orbital volumes in ml.

RESULTS: The difference in the volumes of the right and left orbits of 0.5 ml or more was detected in 5 women out of 25 cases, among men the difference was present in 12 cases out of 25; a difference in volumes of more than 1 ml was noted in 1 woman and 2 men; a difference of more than 1.5 ml was not observed in any study group. The orbital asymmetry coefficient in women ranged from 0 ml to 1.21 ml, in men — from 0.08 ml to 1.19 ml, in women, the average volume of both orbits is less than in men. It was also detected that the volume of orbits increases with age, both in men and women.

CONCLUSIONS: Considering that the majority of patients had differences in orbital volumes of up to 1.0 ml, we agree with studies that indicate the possibility of using a healthy contralateral orbit as a guideline when planning reconstructive surgery. However, for planning surgical treatment, it is recommended to use manual contouring, as this allows the most accurate reproducibility of the bone boundaries of the orbit, although it requires more time than semi- and automatic segmentation. Also, the advantages of the used method for calculating the volumes of orbits in this study include reproducibility on any workstation from different manufacturers, since the method is carried out on a standard tomograph workstation and does not require any additional software.

Keywords: orbit; orbital volume; multispiral computed tomography; MSCT; radiology diagnostics; orbital bone walls.

To cite this article

Davydov DV, Serova NS, Kakorina OA, Pavlova OYu. Comparative study of orbital volumes according to multispiral computed tomography data. *Ophthalmology Reports*. 2024;17(2):41–51. DOI: <https://doi.org/10.17816/OV630330>

Received: 14.04.2024

Accepted: 14.05.2024

Published online: 28.06.2024

DOI: <https://doi.org/10.17816/OV630330>

Сравнительное исследование объёмов орбит по данным мультиспиральной компьютерной томографии

Д.В. Давыдов¹, Н.С. Серова², О.А. Какорина², О.Ю. Павлова²¹ Московский научно-исследовательский онкологический институт им. П.А. Герцена — филиал Национального медицинского исследовательского центра радиологии, Москва, Россия;² Первый Московский государственный медицинский университет им. И.М. Сеченова (Сеченовский Университет), Москва, Россия

АННОТАЦИЯ

Актуальность. Считается, что точная реконструкция правильной анатомии костных стенок орбиты, восстановление симметрии и объёма необходимы для благоприятного функционального прогноза и устранения эстетического дефекта. Основная проблема при оценке объёма орбиты заключается в её сложной анатомии. Для определения объёмов орбит учёные используют различные методы, а в обзорах, сравнивающих различные методы расчёта объёмов орбит, нет данных о том, какой метод волюмометрии орбиты является наиболее точным, так как каждый из них имеет как преимущества, так и недостатки.

Цель — анализ и сравнение объёмов орбит по данным мультиспиральной компьютерной томографии у здоровых пациентов без костно-травматических повреждений стенок орбит.

Материалы и методы. Для измерения объёмов орбит произвольно были выбраны 50 пациентов, которые проходили обследование в отделении лучевой диагностики № 2 Университетской клинической больницы № 1 Сеченовского Университета с 2023 по 2024 г., и которым выполняли мультиспиральную компьютерную томографию лицевого скелета по показаниям, не связанным с патологией орбиты. Были проанализированы данные компьютерной томографии 25 женщин и 25 мужчин разных возрастов (от 18 до 85 лет), из них было сформировано 8 групп в зависимости от пола и возраста: 1-я группа — женщины 18–25 лет, 2-я группа — мужчины 18–25 лет, 3-я группа — женщины 26–35 лет, 4-я группа — мужчины 26–35 лет, 5-я группа — женщины 36–50 лет, 6-я группа — мужчины 36–50 лет, 7-я группа — женщины 51 года и старше, 8-я группа — мужчины 51 года и старше. Мультиспиральную компьютерную томографию лицевого скелета проводили на аппарате Aquilion One 640 (Япония), с толщиной среза 0,5 мм, в костном и мягкотканном режимах, для расчёта объёма на рабочей станции на каждом аксиальном срезе проводили маркировку всех костных границ орбит, начиная с верхней стенки до уровня дна орбиты с представлением объёмов в миллилитрах.

Результаты. Разница объёмов правой и левой орбиты 0,5 мл и более встретила у 5 женщин из 25, среди мужчин разница была выявлена в 12 случаях из 25; разница объёмов более 1 мл была отмечена у 1 женщины и у 2 мужчин; более 1,5 мл не наблюдалась ни в одной из исследуемых групп. Коэффициент асимметрии орбит у женщин варьировал от 0 до 1,21 мл, у мужчин — от 0,08 до 1,19 мл, у женщин объём обеих орбит в среднем меньше, чем у мужчин. Выявлено, что объёмы орбит увеличиваются с возрастом как у мужчин, так и у женщин.

Заключение. Учитывая, что большинство пациентов имели различия в разнице орбит до 1,0 мл, мы согласны с исследованиями, которые указывают на возможность использования здоровой контралатеральной орбиты в качестве ориентира при планировании реконструктивной операции. Однако для планирования хирургического лечения рекомендуется пользоваться ручной маркировкой, так как это позволяет добиться наиболее точной воспроизводимости костных границ орбиты, хотя и требует большего количества времени, чем полу- и автоматическая сегментация. К преимуществам разработанной методики расчёта объёмов орбит в данном исследовании следует отнести воспроизводимость на любой рабочей станции различных производителей, так как метод проводится с использованием стандартных инструментов и не требует дополнительного программного обеспечения.

Ключевые слова: орбита; объём орбиты; мультиспиральная компьютерная томография; МСКТ; лучевая диагностика; костные стенки орбиты.

Как цитировать

Давыдов Д.В., Серова Н.С., Какорина О.А., Павлова О.Ю. Сравнительное исследование объёмов орбит по данным мультиспиральной компьютерной томографии // Офтальмологические ведомости. 2024. Т. 17. № 2. С. 41–51. DOI: <https://doi.org/10.17816/OV630330>

Рукопись получена: 14.04.2024

Рукопись одобрена: 14.05.2024

Опубликована online: 28.06.2024

BACKGROUND

The bony orbit is the most complex anatomical structure of the facial skeleton with significant functional importance. The form and the volume of the orbit physiologically change with age and may increase or decrease in various pathological conditions [1, 2]. Traumatic lesions of the orbit lead to a significant change of the configuration of its walls, and the rate of lesions depends on the localization of the injury. Bone-traumatic injuries in the area of the facial skeleton making up, according to data from multifunctional hospitals, one third of all multisystem injuries in 36% of cases, are accompanied by injury of orbitals walls, and fractures of the mid-face (orbital, buccal zygomatic, and nasal regions) combine with orbital fractures in 80% of cases [3].

It is recognized that the exact reconstruction of the regular anatomy of the bony walls of the orbit, the restoration of the symmetry and the volume are necessary for favorable functional prognosis and for elimination of the esthetic defect [2, 4, 5]. According to data by many authors, under- or overestimation of the orbital volume in planning of reconstructive procedures may lead to enophthalmos or proptosis and, as a consequence of this, to diplopia, possible loss of sensitivity in the buccal and nasal regions [6–8]. According to the results of various retrospective studies, the percentage of the secondary postoperative enophthalmos in patients operated for isolated injury of the orbital floor reaches 26.6% [9, 10].

K. Yab, et al. [11], as well as many other authors, based on the analysis of CT-images of patients with orbital fractures, established that for so long as the increase of the orbital volume does not surpass 2 ml, the enophthalmos remains at the 1 mm level. Then the degree of enophthalmos will increase proportionally to the increase of the orbital volume, but in an isolated orbital floor fracture will never surpass 4 mm [1, 12]. Thus, a reliable 3D analysis of orbital walls' injuries and knowledge of volume are necessary for precise diagnosis and for the planning of surgical procedure in various injuries [13].

Most often, when planning the reconstructive treatment of the injured orbit, the healthy contralateral side and its individual bone configuration are used. At the same time, the surgeon has to know how symmetrical the bony walls of the orbit are and how they change according to age and sex [14]. Some researchers came to a conclusion that the bony orbit and, consequently, its volume change with age [15–18].

The main problem in the estimation of the orbital volume is in its complex anatomy. The bony orbit is pyramid-shaped, with multiple openings and local curves. The anterior border of the orbit is characterized by multiple bone protrusions, such as supraorbital groove and

anterior lacrimal crest [19]. This feature also could be a source of differences in estimating the orbital volume in patients, because the anterior orbital aperture does not lie in a single plane [5, 20, 21].

To determine orbital volumes, scientists use various methods, including experimental cadaver models and image analysis of real-life faces:

- Use of 1 mm glass balls on cadavers with their subsequent immersion into a graduated cylinder [22];
- Creation of silicon impressions on cadavers (the volume of impressions is measured by water drive) [22];
- Analysis and estimation of data using the cone-beam computerized tomography [23];
- Achievement of manual segmentation on the CT images with subsequent 3D-modelling [1, 7, 17, 18, 24–26];
- Use of artificial intelligence and automatic/semi-automatic segmentation on the CT-images with subsequent use of 3D-software for volumetric orbitometry [2, 5, 20, 22, 23, 27, 28].

In reviews comparing various methods of orbital volume calculation, there are no data upon which method of orbital volumetry is the most accurate one, as each of them has both advantages and limitations [22, 29].

Aim — to analyze and to compare the orbital volumes according to the multi-slice spiral CT in healthy patients without bone-traumatic or bone-destructive changes.

MATERIALS AND METHODS

To measure orbital volumes, 50 patients were randomly chosen, who underwent examination in the Diagnostic Radiology Department #2 of the University clinical hospital No.1 of the Sechenov University from January, 2023, through February, 2024, and in whom the multi-slice spiral CT of the facial skeleton conforming to the indications not related to orbital pathologic conditions. CT-data of 25 women and 25 men of various ages (from 18 to 85 years), of Caucasian race, were analyzed.

Inclusion criteria: age of patients from 18 to 85 years; intact bony walls of the orbits without bone-traumatic or bone-destructive changes.

Exclusion criteria: patients with history of injuries, surgeries, oncologic diseases in the area of the orbit and paranasal sinuses; age of patients less than 18 years; thyroid diseases and presence of CT-signs of thyroid eye disease; axial refractive anomalies.

In the study, 8 groups were formed according to sex and age: 1st group — women 18–25 years, 2nd group — men 18–25 years, 3rd group — women 26–35 years, 4th group — men 26–35 years, 5th group — women 36–50 years, 6th group — men 36–50 years, 7th group — women 51 years and older, 8th group — men 51 years and older.

CT-examination of the facial skeleton was carried out using the Aquilion One 640 device according to standard

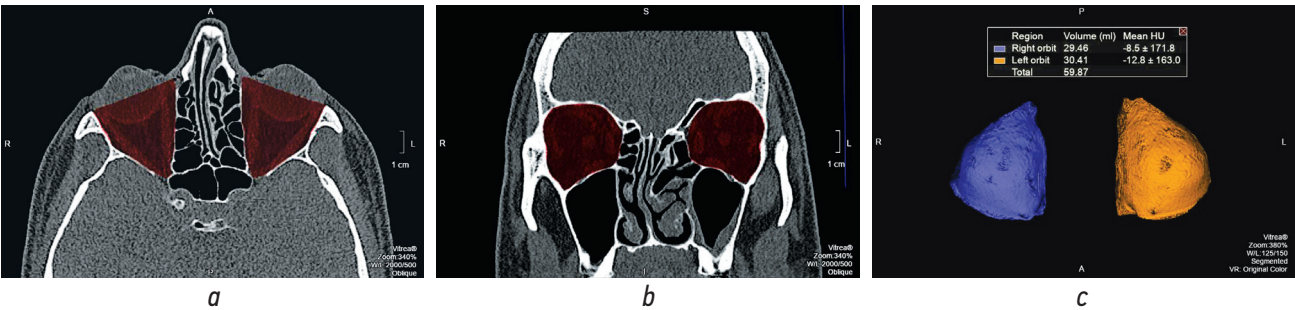


Fig. 1. MSCT. Image processing for orbital volume measurement: *a* — axial section, bone window mode, marking of the orbital bone contours; *b* — coronal reconstruction, bone window mode, marking of the orbital bone contours; *c* — 3D-reconstruction, volumes of the right and left orbits in mathematical units (ml)

Рис. 1. Мультиспиральная компьютерная томография. Обработка изображений для измерения объёмов орбиты: *a* — аксиальный срез, режим костного окна, маркировка костных границ обеих орбит; *b* — корональная реконструкция, режим костного окна, маркировка костных границ обеих орбит; *c* — 3D-реконструкция, объёмы правой и левой орбиты в математических единицах (мл)

technique. The patient's head was placed on the head support, fixed centrally, laser marks were used to determine tomography levels, images were obtained with slice thickness of no more than 0.5 mm, with reconstructions in bone and soft-tissue regimens. After the CT, on the obtained images, the bony borders of the orbits were determined, by which the marking of orbital walls was performed. The requisite condition for correct examination performance was the symmetry of bony borders of both orbits. To achieve this, it was necessary drawing a line across the total length of the orbit and a perpendicular line to the length to establish the outer limit of marking.

On each axial slice, a marking of all bony orbital borders was performed, starting from the upper wall to the level of the orbital floor, with presentation of orbital volumes in milliliters. For an accurate measurement, the bony borders were strictly followed, and anatomical variations of orbital structure of both orbits were taken into account (the method of orbital volume calculation received earlier a Russian Federation patent "A method of efficacy estimation of a reconstructive surgical procedure of the orbit" RU2638623 S1, 14.12.2017. Bull. No. 35) (Figure 1).

RESULTS

In the present study, a manual segmentation of CT-images was used with marking of orbital bony walls and comparison with the contralateral side. In spite of the fact that this method is considered to be the most time-consuming one, as automatic or semi-automatic segmentation are performed several-fold more rapidly, the accuracy of the bony boundaries manual marking is most valid [23].

As a result of carried out investigations, it was established that the volume difference between the right and the left orbit 0.5 ml and more was encountered in 5 women from 25 cases, among men, the difference was revealed in 12 cases from 25; the volume difference of more than 1 ml was found in 1 woman and in 2 men; the difference of more than 1.5 ml was found in none of the examined groups (Figures 2, 3).

The results of orbital volume calculations in groups, taking into account the sex and the age are presented in the Table 1. In the Table 2, the mean values of orbital volumes in every group are shown. The Figure 4 demonstrates the numerical distribution of orbital volume values

Table 1. Calculation of orbital volume by groups, gender and age

Таблица 1. Расчеты объёмов орбит по группам, полу и возрасту

Patient	Age, years	Right orbit, ml	Left orbit, ml	Asymmetry index, ml
18–25 years, women				
Patient 1	20	26.93	26.95	0.02
Patient 2	19	21.01	21.03	0.03
Patient 3	24	25.82	25.97	0.15
Patient 4	19	22.60	22.40	0.2
Patient 5	22	20.48	22.40	0.4
Patient 6	24	22.85	22.25	0.6
Patient 7	23	24.80	24.09	0.71

Table 1 (continued) / Окончание таблицы 1

Patient	Age, years	Right orbit, ml	Left orbit, ml	Asymmetry index, ml
18–25 years, men				
Patient 8	20	29.45	29.55	0.1
Patient 9	25	24.58	24.85	0.27
Patient 10	24	23.87	23.44	0.43
Patient 11	18	28.69	29.78	1.09
Patient 12	22	29.61	28.51	1.1
26–35 years, women				
Patient 13	33	25.17	25.15	0.02
Patient 14	26	23.92	23.99	0.07
Patient 15	28	24.71	24.80	0.09
Patient 16	32	23.73	23.50	0.23
Patient 17	31	23.26	23.00	0.26
Patient 18	29	25.15	25.45	0.3
26–35 years, men				
Patient 19	27	26.41	26.33	0.08
Patient 20	27	28.25	28.12	0.13
Patient 21	32	26.37	26.20	0.17
Patient 22	27	25.53	26.15	0.62
Patient 23	29	33.73	34.41	0.68
Patient 24	28	27.54	28.25	0.71
Patient 25	33	33.56	34.75	1.19
36–50 years, women				
Patient 26	45	22.73	22.68	0.05
Patient 27	44	26.72	26.65	0.07
Patient 28	39	27.63	27.74	0.11
Patient 29	38	25.09	24.70	0.39
Patient 30	48	25.69	24.48	1.21
36–50 years, men				
Patient 31	48	25.36	25.47	0.11
Patient 32	37	27.75	27.64	0.11
Patient 33	38	27.72	27.50	0.22
Patient 34	42	30.38	29.97	0.41
Patient 35	46	25.02	24.31	0.71
Patient 36	36	31.36	30.55	0.81
51 years and older, women				
Patient 37	71	24.33	24.33	0
Patient 38	64	23.24	23.15	0.09
Patient 39	69	29.21	29.32	0.11
Patient 40	55	28.32	28.03	0.29
Patient 41	64	24.80	24.35	0.45
Patient 42	80	25.57	26.37	0.8
Patient 43	52	26.05	25.23	0.82
51 years and older, men				
Patient 44	54	29.32	29.17	0.15
Patient 45	77	30.70	31.09	0.39
Patient 46	60	26.65	27.13	0.48
Patient 47	56	28.92	28.38	0.54
Patient 48	84	28.40	27.51	0.89
Patient 49	66	27.93	27.01	0.92
Patient 50	51	29.46	30.41	0.95

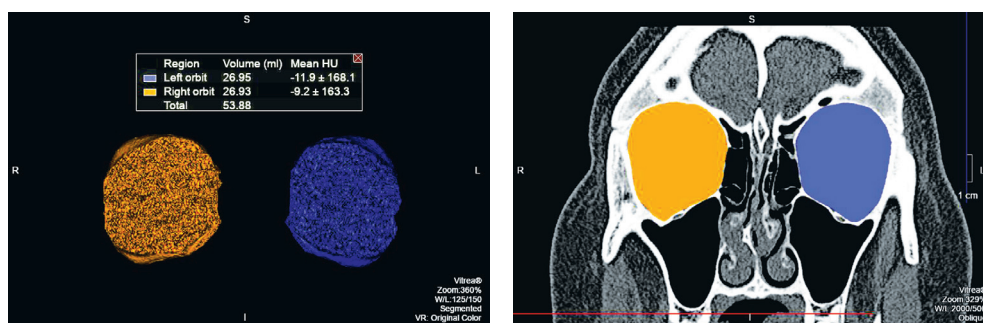


Fig. 2. MSCT. Image processing for orbital volume measurement. The volume of the right orbit was 26.93 ml, the volume of the left orbit was 26.95 ml, the difference was 0.02 ml

Рис. 2. Мультиспиральная компьютерная томография. Обработка изображений для измерения объёмов орбиты. Объём правой орбиты 26,93 мл, объём левой орбиты 26,95 мл, разница составила 0,02 мл

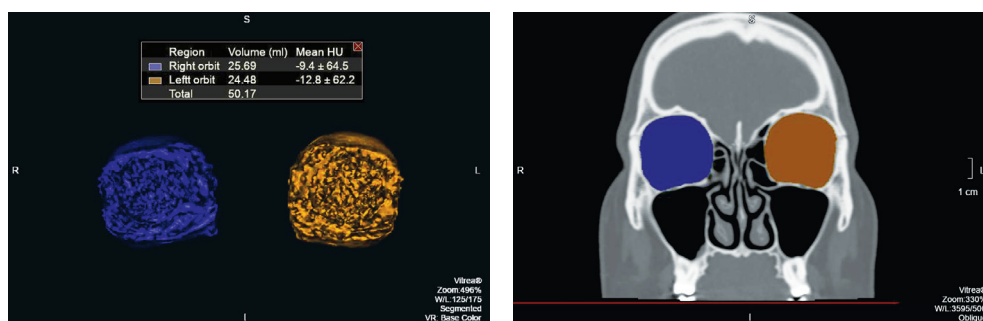


Fig. 3. MSCT. Image processing for orbital volume measurement. The volume of the right orbit was 25.69 ml, the volume of the left orbit was 24.48 ml, the difference was 1.21 ml

Рис. 3. Мультиспиральная компьютерная томография. Обработка изображений для измерения объёмов орбиты. Объём правой орбиты 25,69 мл, объём левой орбиты 24,48 мл, разница составила 1,21 мл

Table 2. Average values of orbital volume by groups

Таблица 2. Средние значения объёмов орбит по группам

Age group	Sex	Right orbit (mean, ml)	Left orbit (mean, ml)
18–25 years	F	23.50 ± 2.43*	23.25 ± 2.18
26–35 years	F	24.32 ± 0.80	24.32 ± 0.97
36–50 years	F	25.57 ± 1.86	25.25 ± 1.98
51+ years	F	25.93 ± 2.15	25.84 ± 2.21
18–25 years	M	27.24 ± 2.79	27.23 ± 2.90
26–35 years	M	28.77 ± 3.44	29.17 ± 3.80
36–50 years	M	29.73 ± 2.57	27.57 ± 2.44
51+ years	M	28.77 ± 1.28	28.67 ± 1.26

*Mean square deviation based on unbiased variance estimation.

*Среднее квадратичное отклонение на основании несмещённой оценки дисперсии.

in the groups. It was revealed that in women the asymmetry was encountered more rarely or did not surpass the 0.5 ml difference, and the volume of the right orbit predominated over that of the left orbit in 62% of cases (Figure 5).

As a result of our study, it was established that the orbital asymmetry index varied in women from 0 to 1.21 ml,

in men — from 0.08 to 1.19 ml. The mean volume of the right orbit in women was 24.83 ml, in men — 28.63 ml, the mean volume of the left orbit in women was 24.67 ml, in men — 28.16 ml; in women the volume of both orbits in average is less, than in men (Figure 6). Thus, the orbital volume increases with age both in men and women (Figure 7).

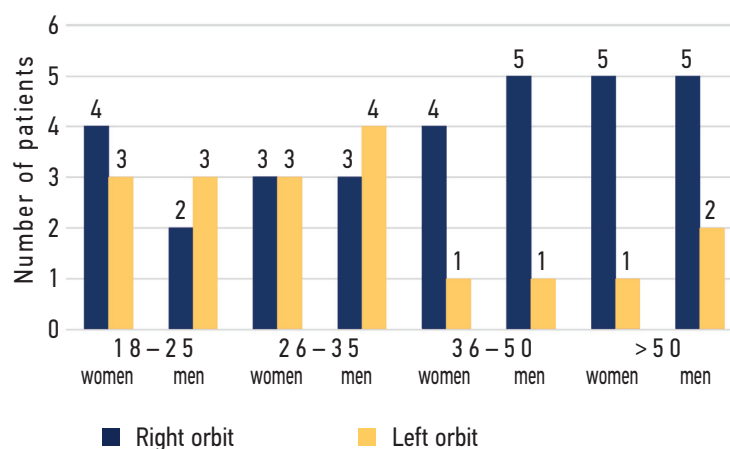


Fig. 4. Distribution of orbital volume values by groups

Рис. 4. Численное распределение значений объемов орбит по группам

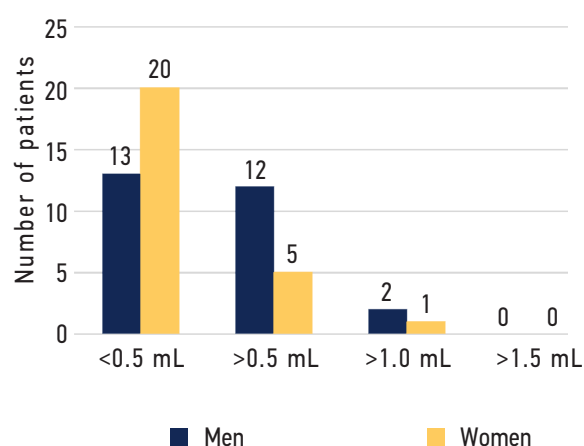


Fig. 5. The incidence of asymmetry among men and women according to the results of the study

Рис. 5. Частота встречаемости асимметрии среди мужчин и женщин по результатам исследования

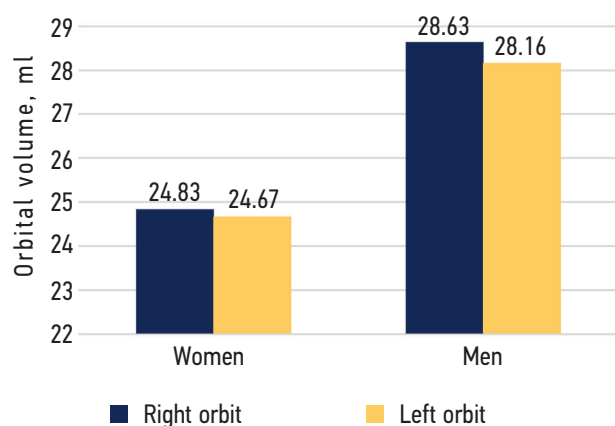


Fig. 6. The average volume of the right and left orbits in women and men

Рис. 6. Средний объем правой и левой орбит у женщин и мужчин

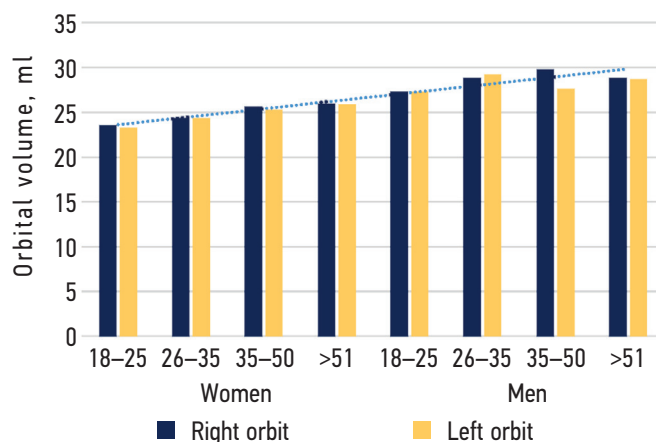


Fig. 7. The average volume of orbits in different age and gender groups

Рис. 7. Средний объем орбит в разных группах по возрасту и полу

DISCUSSION

In earlier studies, controversial results were highlighted concerning the symmetry between the orbital volumes. For example, in the study by O. Lieger, et al. [30], no statistically significant difference between the orbital volumes was found, that is why the authors recommend “reflecting” the form and the volume of the volume of the orbit performing the reconstructions. The study by V.B.-H. Shyu, et al. [5] confirms, that the difference between the orbital volumes was not statistically significant, however in that study, the calculations were performed in an Asian population, and could have significant differences with Caucasian patients [7]. In our study, the difference between the orbital volumes of more than 0.5 ml was more frequent in men (Table 1).

In the publications of N.I. Regensburg, et al. [30] and D. Amin, et al. [31] the dependences were investigated

of orbital volumes from sex, age and nationality, as well as the ratio of the bony orbit volume, orbital fat, and volume of the extraocular muscles. It was shown that with age, the ratio of orbital fat to the total orbital volume increases, and there is a small decrease of the extraocular muscles ratio to the orbital volume. P. Andrades, et al. [18] did not find any significant difference between the right and the left orbit ($p = 0.73$), and the most important criteria in orbital volume evaluation, to the authors’ meaning, were age, height and width of the face, and intraorbital distance.

The results obtained in our study correlate with other works due to the established increase of orbital volumes with age both in men and women. In the investigation by J.E. Pessa, et al. [32], the problems of the facial skeleton remodelling were studied in patients, starting from the newborns and till 76 years. It was revealed that at young

age (15–24 years), the ratio of the maxillar height to that of the orbit is the highest, and during infancy (up to one year) and at the age from 53 to 76 years, this ratio changes due to smaller maxillar height in comparison to larger orbit. In the studies by D.M. Kahn, et al. [33] and Z. Li, et al. [34], there were also the manifestations of the orbital volume increase with age found, because of the bony tissue resorption, whereas the resorption of the supraorbital orbital rim was more pronounced than that of the infraorbital orbital rim through the aging process.

In the article by B. Chon, et al. [15], the CT results of patients with mean time interval 9.4 years were analyzed. The orbital volume at the second scanning exceeded the baseline volume at the first scanning by 0.91 ml. However, the authors associate the volume increase to changes of the orbital soft tissues.

Ugradar, et al. [16] established that statistically significant changes in orbital volumes were revealed in women; this could be explained by a decrease of bone tissue density after menopause [2], at the same time, no significant increase in orbital volumes in men was established.

CONCLUSIONS

In our study, it was revealed that in a healthy human the right and the left orbit are asymmetric: the difference in 0.5 ml have up to 5 women out of 25 and 12 men out of 25, the difference in 1.0 ml was established in 3 cases out of 50. In our study, it was also found that orbital volumes change and increase with age both in men and women. Taking into consideration that most patients had the differences in orbital volumes up to 1.0 ml, we agree with studies, which point on the possibility to use the healthy contralateral orbit as the target when planning reconstructive surgery. However, to plan the surgical treatment, it is recommended to use manual marking as this allows the most accurate reproducibility of the bony orbital borders, in spite it demands more time, as semi- and automatic segmentation. To the advantages of elaborated in the present study orbital volume calculation the reproducibility on any workstation of various producing companies is to be counted, as this method is carried

out on a standard workstation of a tomograph and does not demand any additional software.

ADDITIONAL INFORMATION

Authors' contribution. All authors made a substantial contribution to the conception of the study, acquisition, analysis, interpretation of data for the work, drafting and revising the article, final approval of the version to be published and agree to be accountable for all aspects of the study. Personal contribution of each author: D.V. Davydov — concept and design of the study, analysis of the obtained data, final edits; N.S. Serova — study concept and design, consultation of diagrams and CT images; O.A. Kakorina — collection and processing of materials, literature review, writing the text; O.Yu. Pavlova — analysis of the obtained data, editing of diagrams and text.

Funding source. The study was not supported by any external sources of funding.

Competing interests. The authors declare that they have no competing interests.

Consent for publication. Written consent was obtained from the patients for publication of relevant medical information within the manuscript.

ДОПОЛНИТЕЛЬНАЯ ИНФОРМАЦИЯ

Вклад авторов. Все авторы внесли существенный вклад в разработку концепции, проведение исследования и подготовку статьи, прочли и одобрили финальную версию перед публикацией. Личный вклад каждого автора: Д.В. Давыдов — концепция и дизайн исследования, анализ полученных данных, окончательные правки; Н.С. Серова — концепция и дизайн исследования, консультация схем и КТ-изображений; О.А. Какорина — сбор и обработка материалов, обзор литературы, написание текста; О.Ю. Павлова — анализ полученных данных, редактирование диаграмм и текста.

Источник финансирования. Авторы заявляют об отсутствии внешнего финансирования при проведении исследования.

Конфликт интересов. Авторы декларируют отсутствие явных и потенциальных конфликтов интересов, связанных с публикацией настоящей статьи.

Информированное согласие на публикацию. Авторы получили письменное согласие пациентов на публикацию медицинских данных и фотографий.

REFERENCES

1. Davydov DV, Serova NS, Pavlova OYu. Risk prediction of posttraumatic enophthalmos development on the basis of orbital volume calculations using multislice computed tomography data. *Ophthalmology Reports*. 2018;11(3):26–33. EDN: YQIDCH doi: 10.17816/OV11326-33
2. Sigron GR, Britschgi CL, Gahl B, Thieringer FM. Insights into orbital symmetry: a comprehensive retrospective study of 372 computed tomography scans. *J Clin Med*. 2024;13(14):1041. doi: 10.3390/jcm13041041
3. Gorbachev DS, Poritsky YuV. Diagnosis and treatment of diseases and injuries of the orbit and lacrimal ducts (historical essay on the 195th anniversary of the first Russian Department of Ophthalmology of the Military Medical Academy). *Bulletin of the National Medical-Surgical Center named after N.I. Pirogov*. 2014;9(2):19–24. EDN: WZCGJP
4. Davydov DV, Levchenko OV, Drobyshev AYU, Mikhailyukov VM. Frameless navigation in the surgical treatment of post-traumatic de-

formities and orbital defects. *Practical Medicine*. 2012;(4-2):187-191. EDN: PCHGQX

5. Shyu VB, Hsu CE, Chen CH, Chen CT. 3D-assisted quantitative assessment of orbital volume using an open-source software platform in a Taiwanese population. *PLoS ONE*. 2015;10(3):e0119589. doi: 10.1371/journal.pone.0119589

6. Hartwig S, Nissen MC, Voss JO, et al. Clinical outcome after orbital floor fracture reduction with special regard to patient's satisfaction. *Chin J Traumatol*. 2019;22(3):155-160. doi: 10.1016/j.cjtee.2019.01.002

7. Hahn HM, Jung YK, Lee IJ, et al. Revisiting bilateral bony orbital volumes comparison using 3D reconstruction in Korean adults: a reference study for orbital wall reconstruction, 3D printing, and navigation by mirroring. *BMC Surg*. 2023;23(1):351. doi: 10.1186/s12893-023-02268-0

8. Cole P, Boyd V, Banerji S, Hollier LH. Comprehensive management of orbital fractures. *Plast Reconstr Surg*. 2007;120(Suppl 2):57S-63S. doi: 10.1097/01.prs.0000260752.20481.b4

9. Chi MJ, Ku M, Shin KH, Baek S. An analysis of 733 surgically treated blowout fractures. *Ophthalmologica*. 2009;224(3):167-175. doi: 10.1159/000238932

10. Gushchina MB, Afanasyeva DS. Post-traumatic enophthalmos: problems of diagnosis and rehabilitation. *Clinical Ophthalmology*. 2019;19(4):252-256. EDN: TOHUBI doi: 10.32364/2311-7729-2019-19-4-252-256

11. Yab K, Tajima S, Ohba S. Displacements of eyeball in orbital blowout fractures. *Plast Reconstr Surg*. 1997;100(6):1409-1417. doi: 10.1097/00006534-199711000-00005

12. Nikolaenko VP, Astakhov YuS. Part 1. Epidemiology and classification of orbital fractures. Clinic and diagnosis of fractures of the lower wall of the orbit. *Ophthalmology Reports*. 2009;2(2):56-70. EDN: KVPHLZ

13. Sigrón GR, Barba M, Chammartin F, et al. Functional and cosmetic outcome after reconstruction of isolated, unilateral orbital floor fractures (blow-out fractures) with and without the support of 3D-printed orbital anatomical models. *J Clin Med*. 2021;10(16):3509. doi: 10.3390/jcm10163509

14. Erdoğan K, Tatlısumak E, Ovalı GY, et al. Age- and sex-related morphometric changes and asymmetry in the orbito-zygomatic region. *J Craniofac Surg*. 2021;32(2):768-770. doi: 10.1097/SCS.00000000000007008

15. Chon B, Zhang KR, Hwang CJ, Perry JD. Longitudinal changes in adult bony orbital volume. *Ophthal Plast Reconstr Surg*. 2020;36(3):243-246. doi: 10.1097/IOP.0000000000001519

16. Ugradar S, Lambros V. Orbital volume increases with age: a computed tomography-based volumetric study. *Ann Plast Surg*. 2019;83(6):693-696. doi: 10.1097/SAP.0000000000001929

17. Erkoç MF, Öztoprak B, Gümüş C, et al. Exploration of orbital and orbital soft-tissue volume changes with gender and body parameters using magnetic resonance imaging. *Exp Ther Med*. 2015;9(5):1991-1997. doi: 10.3892/etm.2015.2313

18. Andrades P, Cuevas P, Hernández R, et al. Characterization of the orbital volume in normal population. *J Craniomaxillofac Surg*. 2018;46(4):594-599. doi: 10.1016/j.jcms.2018.02.003

19. Tasman W, Jaeger EA. *Duane's ophthalmology*. Chapter 32: embryology and anatomy of the orbit and lacrimal system. Lippincott / Williams & Wilkins. 2007.

20. Ji Y, Qian Z, Dong Y, et al. Quantitative morphometry of the orbit in Chinese adults based on a three-dimensional reconstruction method. *J Anat*. 2010;217(5):501-506. doi: 10.1111/j.1469-7580.2010.01286.x

21. McGurk M, Whitehouse RW, Taylor PM, Swinson B. Orbital volume measured by a low-dose CT scanning technique. *Dentomaxillofac Radiol*. 1992;21(2):70-72. doi: 10.1259/dmfr.21.2.1397459

22. Osaki TH, de Castro DK, Yabumoto C, et al. Comparison of methodologies in volumetric orbitometry. *Ophthalmic Plast Reconstr Surg*. 2013;29(6):431-436.

23. Wagner ME, Gellrich NC, Friesen KI, et al. Model-based segmentation in orbital volume measurement with cone beam computed tomography and evaluation against current concepts. *Int J Comput Assist Radiol Surg*. 2016;11(1):1-9. doi: 10.1007/s11548-015-1228-8

24. Furuta M. Measurement of orbital volume by computed tomography: especially on the growth of the orbit. *Jpn J Ophthalmol*. 2001;45(6):600-606. doi: 10.1016/s0021-5155(01)00419-1

25. Friedrich RE, Bruhn M, Lohse C. Cone-beam computed tomography of the orbit and optic canal volumes. *J Craniomaxillofac Surg*. 2016;44(9):1342-1349. doi: 10.1016/j.jcms.2016.06.003

26. Kwon J, Barrera JE, Most SP. Comparative computation of orbital volume from axial and coronal CT using three-dimensional image analysis. *Ophthalmic Plast Reconstr Surg*. 2010;26(1):26-29. doi: 10.1097/IOP.0b013e3181b80c6a

27. Koppel DA, Foy RH, McCaul JA, et al. The reliability of "Analyze" software in measuring orbital volume utilizing CT-derived data. *J Craniomaxillofac Surg*. 2003;31(2):88-91. doi: 10.1016/s1010-5182(02)00170-1

28. Regensburg NI, Kok PH, Zonneveld FW, et al. A new and validated CT-based method for the calculation of orbital soft tissue volumes. *Invest Ophthalmol Vis Sci*. 2008;49(5):1758-1762. doi: 10.1167/iovs.07-1030

29. Sentucq C, Schlund M, Bouet B, et al. Overview of tools for the measurement of the orbital volume and their applications to orbital surgery. *J Plast Reconstr Aesthet Surg*. 2021;74(3):581-591. doi: 10.1016/j.bjps.2020.08.101

30. Lieger O, Schaub M, Taghizadeh E, Büchler P. How symmetrical are bony orbits in humans? *J Oral Maxillofac Surg*. 2019;77(1):118-125. doi: 10.1016/j.joms.2018.08.018

31. Amin D, Jeong J, Manhan AJ, Bouloux GF, Abramowicz S. Do racial differences in orbital volume influence the reconstruction of orbital trauma. *J Oral Maxillofac Surg*. 2022;80(1):121-126. doi: 10.1016/j.joms.2021.07.030

32. Pessa JE, Zadoo VP, Yuan C, et al. Concertina effect and facial aging: nonlinear aspects of youthfulness and skeletal remodeling, and why, perhaps, infants have jowls. *Plast Reconstr Surg*. 1999;103(2):635-644. doi: 10.1097/00006534-199902000-00042

33. Kahn DM, Shaw RB. Aging of the bony orbit: a three-dimensional computed tomographic study. *Aesthet Surg J*. 2008;28(3):258-264. doi: 10.1016/j.asj.2008.02.007

34. Li Z, Chen K, Yang J, et al. Deep learning-based CT radiomics for feature representation and analysis of aging characteristics of Asian bony orbit. *J Craniofac Surg*. 2022;33(1):312-318. doi: 10.1097/SCS.00000000000008198

СПИСОК ЛИТЕРАТУРЫ

1. Давыдов Д.В., Серова Н.С., Павлова О.Ю. Прогнозирование риска развития посттравматического энтофальма на основании расчётов объёмов орбит по данным мульти-спиральной компьютерной томографии // Офтальмологические ведомости. 2018. Т. 11, № 3. С. 26–33. EDN: YQIDCH doi: 10.17816/OV11326-33
2. Sigron G.R., Britschgi C.L., Gahl B., Thieringer F.M. Insights into orbital symmetry: a comprehensive retrospective study of 372 computed tomography scans // J Clin Med. 2024. Vol. 13, N. 14. P. 1041. doi: 10.3390/jcm13041041
3. Горбачёв Д.С., Порицкий Ю.В. Диагностика и лечение заболеваний и повреждений глазницы и слезоотводящих путей (исторический очерк к 195-летию первой в России кафедры офтальмологии Военно-медицинской академии) // Вестник Национального медико-хирургического центра им. Н.И. Пирогова. 2014. Т. 9, № 2. С. 19–24. EDN: WZCGJP
4. Давыдов Д.В., Левченко О.В., Дробышев А.Ю., Михайлюков В.М. Безрамная навигация в хирургическом лечении посттравматических деформаций и дефектов глазницы // Практическая медицина. 2012. № 4–2. С. 187–191. EDN: PCHGQX
5. Shyu V.B., Hsu C.E., Chen C.H., Chen C.T. 3D-assisted quantitative assessment of orbital volume using an open-source software platform in a Taiwanese population // PLoS ONE. 2015. Vol. 10, N. 3. P. e0119589. doi: 10.1371/journal.pone.0119589
6. Hartwig S., Nissen M.C., Voss J.O., et al. Clinical outcome after orbital floor fracture reduction with special regard to patient's satisfaction // Chin J Traumatol. 2019. Vol. 22, N. 3. P. 155–160. doi: 10.1016/j.cjtee.2019.01.002
7. Hahn H.M., Jung Y.K., Lee I.J., et al. Revisiting bilateral bony orbital volumes comparison using 3D reconstruction in Korean adults: a reference study for orbital wall reconstruction, 3D printing, and navigation by mirroring // BMC Surg. 2023. Vol. 23, N. 1. P. 351. doi: 10.1186/s12893-023-02268-0
8. Cole P., Boyd V., Banerji S., Hollier L.H. Comprehensive management of orbital fractures // Plast Reconstr Surg. 2007. Vol. 120 (Suppl 2). P. 57S–63S. doi: 10.1097/01.prs.0000260752.20481.b4
9. Chi M.J., Ku M., Shin K.H., Baek S. An analysis of 733 surgically treated blowout fractures // Ophthalmologica. 2009. Vol. 224, N. 3. P. 167–175. doi: 10.1159/000238932
10. Гущина М.Б., Афанасьева Д.С. Посттравматический энтофальм: проблемы диагностики и реабилитации // Клиническая офтальмология. 2019. Т. 19, № 4. С. 252–256. EDN: TONUBI doi: 10.32364/2311-7729-2019-19-4-252-256
11. Yab K., Tajima S., Ohba S. Displacements of eyeball in orbital blowout fractures // Plast Reconstr Surg. 1997. Vol. 100, N. 6. P. 1409–1417. doi: 10.1097/00006534-199711000-00005
12. Николаенко В.П., Астахов Ю.С. Часть 1. Эпидемиология и классификация орбитальных переломов. Клиника и диагностика переломов нижней стенки орбиты // Офтальмологические ведомости. 2009. Т. 2, № 2. С. 56–70. EDN: KVPHLZ
13. Sigron G.R., Barba M., Chammartin F., et al. Functional and cosmetic outcome after reconstruction of isolated, unilateral orbital floor fractures (blow-out fractures) with and without the support of 3D-printed orbital anatomical models // J Clin Med. 2021. Vol. 10, N. 16. P. 3509. doi: 10.3390/jcm10163509
14. Erdoğan K., Tatlisumak E., Ovali G.Y., et al. Age- and sex-related morphometric changes and asymmetry in the orbito-zygomatic region // J Craniofac Surg. 2021. Vol. 32, N. 2. P. 768–770. doi: 10.1097/SCS.00000000000007008
15. Chon B., Zhang K.R., Hwang C.J., Perry J.D. Longitudinal changes in adult bony orbital volume // Ophthal Plast Reconstr Surg. 2020. Vol. 36, N. 3. P. 243–246. doi: 10.1097/IOP.0000000000001519
16. Ugradar S., Lambros V. Orbital volume increases with age: a computed tomography-based volumetric study // Ann Plast Surg. 2019. Vol. 83, N. 6. P. 693–696. doi: 10.1097/SAP.0000000000001929
17. Erkoç M.F., Öztoprak B., Gümüş C., et al. Exploration of orbital and orbital soft-tissue volume changes with gender and body parameters using magnetic resonance imaging // Exp Ther Med. 2015. Vol. 9, N. 5. P. 1991–1997. doi: 10.3892/etm.2015.2313
18. Andrades P., Cuevas P., Hernández R., et al. Characterization of the orbital volume in normal population // J Craniomaxillofac Surg. 2018. Vol. 46, N. 4. P. 594–599. doi: 10.1016/j.jcms.2018.02.003
19. Tasman W., Jaeger E.A. Duane's ophthalmology. Chapter 32: embryology and anatomy of the orbit and lacrimal system. Lippincott / Williams & Wilkins. 2007.
20. Ji Y., Qian Z., Dong Y., et al. Quantitative morphometry of the orbit in Chinese adults based on a three-dimensional reconstruction method // J Anat. 2010. Vol. 217, N. 5. P. 501–506. doi: 10.1111/j.1469-7580.2010.01286.x
21. McGurk M., Whitehouse R.W., Taylor P.M., Swinson B. Orbital volume measured by a low-dose CT scanning technique // Dentomaxillofac Radiol. 1992. Vol. 21, N. 2. P. 70–72. doi: 10.1259/dmfr.21.2.1397459
22. Osaki T.H., de Castro D.K., Yabumoto C., et al. Comparison of methodologies in volumetric orbitometry // Ophthalmic Plast Reconstr Surg. 2013. Vol. 29, N. 6. P. 431–436.
23. Wagner M.E., Gellrich N.C., Friesse K.I., et al. Model-based segmentation in orbital volume measurement with cone beam computed tomography and evaluation against current concepts // Int J Comput Assist Radiol Surg. 2016. Vol. 11, N. 1. P. 1–9. doi: 10.1007/s11548-015-1228-8
24. Furuta M. Measurement of orbital volume by computed tomography: especially on the growth of the orbit // Jpn J Ophthalmol. 2001. Vol. 45, N. 6. P. 600–606. doi: 10.1016/s0021-5155(01)00419-1
25. Friedrich R.E., Bruhn M., Lohse C. Cone-beam computed tomography of the orbit and optic canal volumes // J Craniomaxillofac Surg. 2016. Vol. 44, N. 9. P. 1342–1349. doi: 10.1016/j.jcms.2016.06.003
26. Kwon J., Barrera J.E., Most S.P. Comparative computation of orbital volume from axial and coronal CT using three-dimensional image analysis // Ophthalmic Plast Reconstr Surg. 2010. Vol. 26, N. 1. P. 26–29. doi: 10.1097/IOP.0b013e3181b80c6a
27. Koppel D.A., Foy R.H., McCaul J.A., et al. The reliability of "Analyze" software in measuring orbital volume utilizing CT-derived data // J Craniomaxillofac Surg. 2003. Vol. 31, N. 2. P. 88–91. doi: 10.1016/s1010-5182(02)00170-1
28. Regensburg N.I., Kok P.H., Zonneveld F.W., et al. A new and validated CT-based method for the calculation of orbital soft tissue volumes // Invest Ophthalmol Vis Sci. 2008. Vol. 49, N. 5. P. 1758–1762. doi: 10.1167/iovs.07-1030

- 29.** Sentucq C., Schlund M., Bouet B., et al. Overview of tools for the measurement of the orbital volume and their applications to orbital surgery // *J Plast Reconstr Aesthet Surg.* 2021. Vol. 74, N. 3. P. 581–591. doi: 10.1016/j.bjps.2020.08.101
- 30.** Lieger O., Schaub M., Taghizadeh E., Büchler P. How symmetrical are bony orbits in humans? // *J Oral Maxillofac Surg.* 2019. Vol. 77, N. 1. P. 118–125. doi: 10.1016/j.joms.2018.08.018
- 31.** Amin D., Jeong J., Manhan A.J., Bouloux G.F., Abramowicz S. Do racial differences in orbital volume influence the reconstruction of orbital trauma // *J Oral Maxillofac Surg.* 2022. Vol. 80, N. 1. P. 121–126. doi: 10.1016/j.joms.2021.07.030
- 32.** Pessa J.E., Zadoo V.P., Yuan C., et al. Concertina effect and facial aging: nonlinear aspects of youthfulness and skeletal remodeling, and why, perhaps, infants have jowls // *Plast Reconstr Surg.* 1999. Vol. 103, N. 2. P. 635–644. doi: 10.1097/00006534-199902000-00042
- 33.** Kahn D.M., Shaw R.B. Aging of the bony orbit: a three-dimensional computed tomographic study // *Aesthet Surg J.* 2008. Vol. 28, N. 3. P. 258–264. doi: 10.1016/j.asj.2008.02.007
- 34.** Li Z., Chen K., Yang J., et al. Deep learning-based CT radiomics for feature representation and analysis of aging characteristics of Asian bony orbit // *J Craniofac Surg.* 2022. Vol. 33, N. 1. P. 312–318. doi: 10.1097/SCS.00000000000008198

AUTHORS' INFO

Dmitry V. Davydov, MD, Dr. Sci. (Medicine), Professor;
ORCID: 0000-0002-8025-4830; eLibrary SPIN: 1368-2453;
e-mail: d-davydov3@yandex.ru

Natalia S. Serova, MD, Dr. Sci. (Medicine), Professor, Corresponding Member of the Russian Academy of Sciences;
ORCID: 0000-0003-2975-4431; eLibrary SPIN: 4632-3235;
e-mail: dr.serova@yandex.ru

Olga A. Kakorina; e-mail: 20.olgak.02@mail.ru

***Olga Yu. Pavlova**, MD, Cand. Sci. (Medicine);
address: 8/2 Trubetskaya st., Moscow, 119048, Russia;
ORCID: 0000-0001-8898-3125; eLibrary SPIN: 8326-0220;
e-mail: pavlova_o_yu@staff.sechenov.ru

* Corresponding author / Автор, ответственный за переписку

ОБ АВТОРАХ

Дмитрий Викторович Давыдов, д-р мед. наук, профессор;
ORCID: 0000-0002-8025-4830; eLibrary SPIN: 1368-2453;
e-mail: d-davydov3@yandex.ru

Наталья Сергеевна Серова, д-р мед. наук, профессор, чл.-корр. РАН; ORCID: 0000-0003-2975-4431;
eLibrary SPIN: 4632-3235;
e-mail: dr.serova@yandex.ru

Ольга Андреевна Какорина; e-mail: 20.olgak.02@mail.ru

***Ольга Юрьевна Павлова**, канд. мед. наук;
адрес: Россия, 119048, Москва, ул. Трубецкая, д. 8, стр. 2;
ORCID: 0000-0001-8898-3125; eLibrary SPIN: 8326-0220;
e-mail: pavlova_o_yu@staff.sechenov.ru