

**ИНОРОДНОЕ ТЕЛО (МОНЕТА) МЕККЕЛЕВА ДИВЕРТИКУЛА
У РЕБЕНКА ДВУХ ЛЕТ**

© В.П. Гаврилюк¹, С.В. Костин¹, В.А. Мучкина², Д.А. Северинов¹, Н.В. Косолапова²

ФГБОУ ВО Курский государственный медицинский университет
Минздрава России, Курск, Россия (1)
ОБУЗ Курская областная детская больница №2 (2)

Дивертикул Меккеля – локальное мешковидное выпячивание стенки подвздошной кишки, образованное вследствие неполного зарращения желточного протока, который участвует в питании зародыша.

Цель. Познакомить широкий круг коллег с интересным клиническим случаем инородного тела (монета) в Меккелевом дивертикуле. В данной статье изложены подходы к диагностике и оперативному лечению таких пациентов. Данное клиническое наблюдение представляет интерес для абдоминальных хирургов с той точки зрения, что дивертикул Меккеля обнаруживается чаще всего при наличии клиники, возникающей при дивертикулите, кровоточащей или перфоративной язве, непроходимости кишечника, вызванной узлообразованием или инвагинацией.

Заключение. Ситуация, в которой тупоконечное инородное тело дало возможность обнаружить дивертикул Меккеля, описывается нами как казуистически редкая.

Ключевые слова: Меккелев дивертикул; дивертикулит; инородное тело желудочно-кишечного тракта; дети; детская хирургия; оперативное лечение.

**A FOREIGN BODY (A COIN) OF MECKEL'S DIVERTICULUM
IN A TWO-YEAR-OLD CHILD**

V.P. Gavriilyuk¹, S.V. Kostin¹, V.A. Muchkina², D.A. Severinov¹, N.V. Kosolapova²

Kursk State Medical University, Kursk, Russia (1)
Kursk Regional Children's Hospital №2 (2)

Meckel's diverticulum is a sac-like bulge of the wall of ileum formed in result of incomplete closure of the viteline duct that participates in nutrition of the embryo.

Aim. To familiarize a wide community of colleagues with an interesting clinical case of a foreign body (a coin) in Meckel's diverticulum. In the article, approaches to diagnostics and operative treatment of such patients are given. This clinical observation is of interest to abdominal surgeons from the point of view that Meckel's diverticulum is most commonly identified by clinical symptoms present in diverticulitis, bleeding or perforating ulcer, in intestinal obstruction caused by formation of a node or of invagination.

Conclusion. A situation in which a blunt-ended foreign body permitted to identify Meckel's diverticulum, is described as casuistically rare.

Keywords: Meckel's diverticulum; diverticulitis; a foreign body of the gastro-intestinal tract; children; pediatric surgery; surgical treatment.



Meckel's diverticulum (named after a German anatomist J. Meckel) is a local sac-like bulge of the wall of ileum at 10-100 cm distance from the ileocecal angle formed in result of incomplete closure of viteline duct that participates in nutrition of embryo [1-3] and is the most common congenital anomaly of the gastrointestinal tract (GIT).

Meckel's diverticulum (MD) is present in 2% of population [4,5]. Its incidence in boys is 3-5 times that in girls [6]. Only in 2% of cases MD manifests by certain symptoms, mostly in children under 2 years [7,8]. The main causes of these symptoms are development of pathological processes associated with derangement of circulation in the diverticulum or an inflammation secondary to acute appendicitis or invagination of the intestine. There are reported cases when Meckel's diverticulum did not manifest itself over the life of the 'carrier' [9]. Therefore, MD is most commonly an intraoperative finding. In practice of a pediatric surgeon, cases of foreign bodies in the GIT become increasingly common [10]. Hospitalization of a child into a surgical department is often associated with removal of different foreign bodies (needles, coins, small toys, etc.) including those localized in the GIT and being the cause of development of an acute pathology (volvulus, intestinal obstruction, etc.) [11-13].

Aim of work: to familiarize a wide range of colleagues with an interesting clinical case of a foreign body (a coin) getting into Meckel's diverticulum.

Clinical example. On November 6, 2018, a woman N. addressed the reception department of Kursk Regional Pediatric Hospital №2 with a child (a boy of 2 years and 10 months age) with complaints of the pain in the abdomen and restlessness. It was known from anamnesis that the child had been ill within 1.5 days when pain in the abdomen first appeared. Elevation of the body tempera-

ture to low-grade level was noted. The mother with the child addressed Central Hospital in the place of residence where survey abdominal X-ray was performed that identified a foreign body in the GIT and signs of intestinal obstruction. The child was directed to the surgical department with the diagnosis 'invagination of intestine'.

In the reception department the condition of the child was evaluated as moderately severe. Body temperature 36.3⁰C. Clear consciousness. Negative response to examination. Peripheral lymph nodes not enlarged. Heart sounds clear, rhythm regular. Liver not enlarged. Spleen not palpable. Kidneys not palpable. Tinel's symptom negative on both sides. Retention of stool for 24 hours was noted. The tongue moist, abdomen not bloated, participated in breathing, in palpation the child actively tensed the muscles of the anterior abdominal wall, was fidgeting in palpation of the right iliac region. Appendicular symptoms (Rovsing's, Sitkovsky's, Barto-ier-Mikhelson) negative, peritoneal symptoms (Shchetkin-Blumberg, Voskresesky's) negative.

Ultrasound examination (US) of the abdominal organs (06.11.2018): meteorism, visible mesenteric lymph nodes up to 15 mm in diameter. Vermiform appendix was visualized fragmentarily to 4 mm. The walls of intestinal loops infiltrated. No effusion in the abdominal cavity.

Survey X-ray of abdominal organs (06.11.2018): no free gas identified. Gas air bubble of the stomach of large dimension with a horizontal level of fluid. Enhanced pneumatization of the intestine in the upper abdomen, moderate pneumatization in lower parts. On the right in the projection of pelvis (in projection of ileocecal angle) a foreign body was seen of metal density, round shape with sharp contours, 2.1 cm in diameter (Figure 1A).

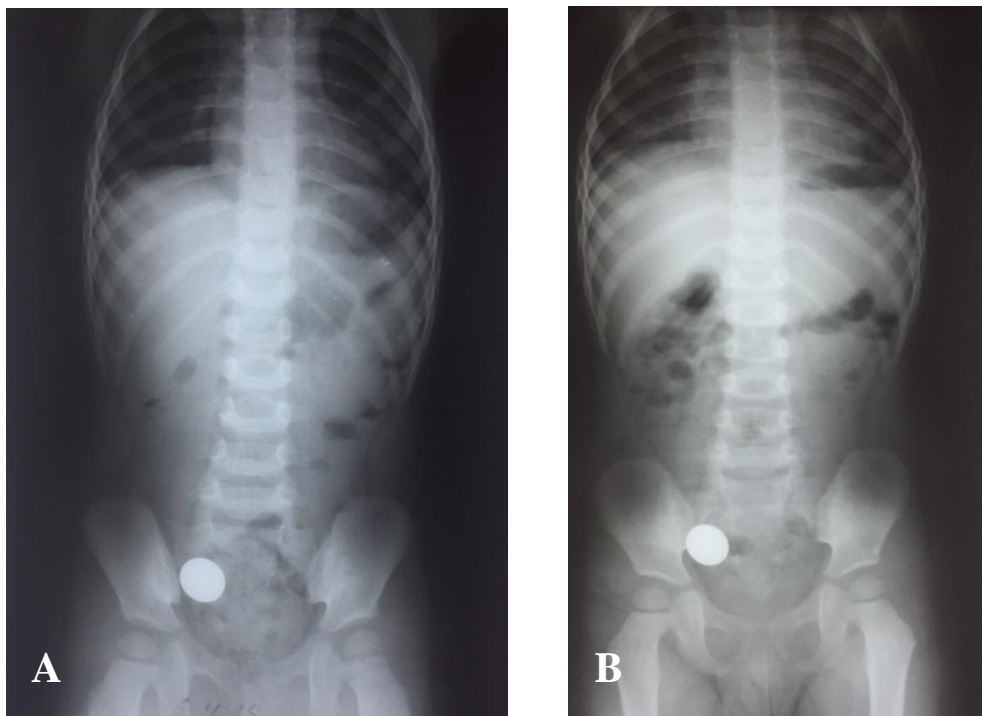


Fig. 1. Survey X-ray of abdominal cavity of child H., 2 years 10 months of age on admission to hospital (A), a day after (B): on the right of the iliac region a foreign body (a coin) is determined

Due to absence of clinical data speaking for invagination of the intestine, the child was observed in the department for a foreign body in the GIT. Passage of the foreign body was evaluated (survey X-ray of the abdominal organs was performed).

Survey X-ray of abdominal organs (07.11.2018): no free gas and fluid levels were determined. The foreign body did not change its position in dynamics, localization was the same. Pneumatization of the intestine was moderately increased in the upper intestine and was moderate in the lower part (Figure 1B).

On 07.11.2018 the condition of the child worsened that was manifested by increase in the anxiety, negative reaction to examination. In connection with a long stay of the foreign body in the GIT, surgical treatment was indicated: revision of the organs of the abdominal cavity, removal of the foreign body after preoperative preparation.

The child was made an operation:

Wedge resection of Meckel's diverticulum. Removal of the foreign body. Appendectomy.

Description of the procedure: Under general anesthesia after the standard treatment of the operative field, laparotomy was conducted in the right iliac region, the abdominal cavity was opened by oblique incision according to Volkovich-Dyakonov. Revision of the abdominal cavity was started. No data were found for intestinal malrotation. The cupula of cecum was in its typical place. The latter was exteriorized together with vermiform appendix (located retroceally), the latter was injected with vessels about 11 cm in length. By palpation, no foreign body was determined in the region of ileocecal angle. In revision of the small intestine at the distance of 40 cm from the ileocecal angle MD was determined 4 cm in length on a wide base (3.5 cm in diameter), of purple color, with fibrin films and with infiltrated walls. In the lumen of Meckel's diverticulum a foreign body was determined. Wedge resection of MD was

conducted, after which the removed portion of the intestine was sent to histological examination (Figure 2). The ileum was closed with one-row continuous suture. Test for leakage and patency – leak-proof and patent. In the lumen of MD a foreign body was determined – a 1 rouble coin. Taking into account changes in the vermiform appendix, a decision was taken to perform appendectomy. The vermiform appendix was separated out of flat adhesions, mesentery of the vermiform appendix

was dissected away on clamps, sutured, ligated to both sides with lavsan. Appendectomy was performed with placement of the stump into the cupula of cecum with purse-string and Z-shaped suture. Resected appendix was sent to histological examination. In the course of the operation hemostasis was conducted, control of hemostasis – dry. Sanitation of the abdominal cavity, effusion was dried up. Layer-by-layer complete closure of the wound. Wound cleaning. Aseptic bandage.

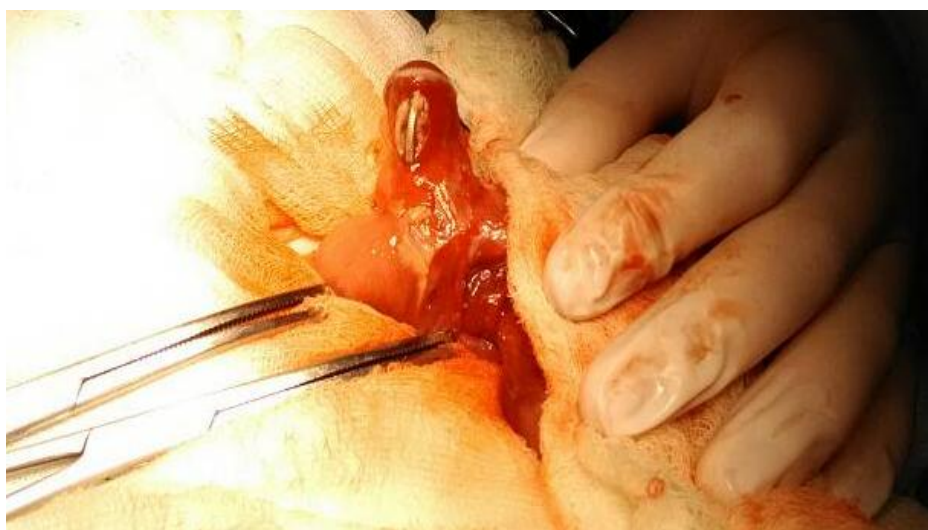

Fig. 2. Intraoperative photo of Meckel's diverticulum with a foreign body (a coin)

Taking into account intraoperative data, the child was administered antibacterial therapy: cefepime 460 mg 3 times a day and amikacin 215 mg once a day.

Diagnosis after operation: *A foreign body of Meckel's diverticulum (a coin). Secondary Meckel's diverticulitis. Secondary appendicitis.*

In the early postoperative period the child stayed in the resuscitation department. On the third day after the operation he was transferred to the department of pediatric surgery. During stay in hospital he received, additionally to antibacterial therapy, anesthetic therapy (paracetamol in suppositories) and anti-adhesion therapy (suppositories with longidaza 1500 MU), physiotherapy (electro-

phoresis with 3% potassium iodide solution). The patient was discharged from hospital on the 9th day in satisfactory condition.

Conclusion

The given clinical observation is of interest to abdominal surgeons from the point of view that Meckel's diverticulum is in most cases detected by the clinical picture associated with diverticulitis, bleeding or perforated ulcer, intestinal obstruction due to formation of a node or invagination. The situation in which the diverticulum was detected owing to the presence of a foreign body is described as casuistically rare. This determines the rarity of the observation and was the reason for the given publication.

Литература

1. Поддубный И.В., Дьяконова Е.Ю., Исмаилов М.У., и др. Лапароскопические операции при патологии дивертикула Меккеля // *Детская хирургия*. 2015. Т. 19, №5. С. 4-6.
2. Тимербулатов М.В., Тимербулатов Ш.В., Сахутдинов В.Г. Дивертикул Меккеля у взрослых и детей // *Эндоскопическая хирургия*. 2017. Т. 23, №2. С. 61-66. doi:10.17116/endoskop201723261-66
3. Ионов Д.В., Туманян Г.Т., Лисюк Н.П. Редкие инородные тела желудочно-кишечного тракта у детей // *Эндоскопическая хирургия*. 2011. Т. 17, №3. С. 51-53.
4. Пошехонов А.С., Легур А.В., Харагезов А.М. Инородные тела желудочно-кишечного тракта у детей // *Университетская Клиника*. 2017. Т. 2, №4(25). С. 148-150.
5. Лейга А.В., Карагезян Р.Л., Чепурной М.Г., и др. Инородное тело (игла) в дивертикуле Меккеля у ребенка // *Детская хирургия*. 2016. Т. 20, №2. С. 109-110. doi:10.18821/1560-9510-20-2-109-110
6. Синенченко Г.И., Вербицкий В.Г., Демко А.Е., и др. Современные возможности ранней диагностики и малоинвазивного хирургического лечения перфораций кишки инородным телом // *Вестник Северо-Западного государственного медицинского университета им. И.И. Мечникова*. 2019. Т. 11, №1. С. 61-64. doi:10.17816/mechnikov201911161-64
7. Тимербулатов В.М., Тимербулатов М.В., Мехдиев Д.И., и др. Диагностика и лечение осложнённых форм дивертикула Меккеля // *Клиническая медицина*. 2017. Т. 95, №11. С. 1013-1017. doi:10.18821/0023-2149-2017-95-11-1013-1017
8. Комаров Н.В., Комаров Р.Н. Перфорация дивертикула Меккеля иглой сосны // *Вестник хирургии им. И.И. Грекова*. 1998. №6. С. 87-88.
9. Бабаева А.А., Ахадов Т.А., Карасева О.В. Рентгенодиагностика у больных с инородными телами желудочно-кишечного тракта при наблюдении в динамике, на фоне проводимого лечения // *Вестник новых медицинских технологий*. 2018. №6. С. 46-58. Доступно по: <http://medtsu.tula.ru/VNMT/Bulletin/E2018-6/1-6.pdf>. Ссылка активна на 5 февраля 2020. doi:10.24411/2075-4094-2018-16224
10. Кирсанов И.И., Македонская Т.П., Тарасов С.А., и др. Возможности видеолапароскопии в диагностике и лечении перфорации тонкой кишки и дивертикула Меккеля (два клинических наблюдения) // *Журнал им. Н.В. Склифосовского «Неотложная медицинская помощь»*. 2016. №1. С. 63-65.
11. Park J.J., Wolff B.G., Tollefson M.K., et al. Meckel's diverticulum: the Mayo Clinic experience with 1476 patients (1950-2002) // *Annals of Surgery*. 2005. Vol. 241, №3. P. 529-533. doi:10.1097/01.sla.0000154270.14308.5f
12. Stone P.A., Hofeldt M.J., Campbell J.E., et al. Meckel Diverticulum: Ten-year Experience in Adults // *Southern Medical Journal*. 2004. Vol. 97. P. 1038-1041. doi:10.1097/01.SMJ.0000125222.90696.03
13. Ding Y, Zhou Y, Ji Z., et al. Laparoscopic management of perforated Meckel's diverticulum in adults // *International Journal of Medical Sciences*. 2012. Vol. 9, №3. P. 243-247. doi:10.7150/ijms.4170

References

1. Poddubny IB, D'yakonova EYu, Ismailov MU, et al. Laparoscopic surgery on pathological Meckel's diverticulum. *Russian Journal of Pediatric Surgery*. 2015;19(5):4-6. (In Russ).
2. Timerbulatov MV, Timerbulatov ShV, Sakhautdinov VG. Meckel's diverticulum in adults and children. *Endoscopic Surgery*. 2017;23(2):61-6. (In Russ). doi:10.17116/endoskop201723261-66
3. Ionov DV, Tumanian GT, Lisiuk NP. Rare gastrointestinal foreign bodies in children. *Endoscopic Surgery*. 2011;17(3):51-3. (In Russ).
4. Poshehonov AS, Legur AV, Kharagezov AM. Foreign bodies of the gastrointestinal tract in children. *University Clinic*. 2017;2(4(25)):148-51. (In Russ).
5. Leyga AV, Karagezyan RL, Chepurnoy MG, et al. A foreign 109 body (needle) in Meckel's diverticulum in a child. *Russian Journal of Pediatric Surgery*. 2016;20(2):109-10. (In Russ). doi:10.18821/1560-9510-20-2-109-110
6. Sinenchenko GI, Verbitsky VG, Demko AE, et al. Modern opportunities of early diagnostics and minimally invasive surgical treatment of intestinal perforation by a foreign body. *Herald of North-Western State Medical University named after I.I. Mechnikov*. 2019;11(1):61-4. (In Russ). doi:10.17816/mechnikov201911161-64
7. Timerbulatov VM, Timerbulatov MV, Mechdiev DI, et al. Diagnosis and treatment of complicated Meckel's diverticulum. *Clinical Medicine*. 2017; 95(11):1013-7. (In Russ). doi:10.18821/0023-2149-2017-95-11-1013-1017
8. Komarov NV, Komarov RN. Perforacija divertikula Mekkelja igolkoj sosny. *Vestnik Khirurgii imeni I.I. Grekova*. 1998;(6):87-8. (In Russ).
9. Babayeva AA, Akhadov TA, Karasyova OV. Radiodiagnosis of patients with foreign bodies in gastrointestinal tract observed in dynamics while undergoing treatment. *Journal of New Medical Technologies*. 2018;(6):46-58. (In Russ). Available at: <http://medtsu.tula.ru/VNMT/Bulletin/E2018-6/1-6.pdf>. Accessed: 2020 February 5. doi:10.24411/2075-4094-2018-16224
10. Kirsanov II, Makedonskaya TP, Tarasov SA, et al. Capabilities of video-assisted laparoscopy in the diagnosis and treatment of perforation of the small intestine and Meckel's diverticulum (2 clinical observations). *Zhurnal imeni N.V. Sklifosovskogo «Neotlozhnaya Meditsinskaya Pomoshch'»*. 2016; (1):63-5. (In Russ).

11. Park JJ, Wolff BG, Tollefson MK, et al. Meckel's diverticulum: the Mayo Clinic experience with 1476 patients (1950-2002). *Annals of Surgery*. 2005; 241(3):529-33. doi:10.1097/01.sla.0000154270.14308.5f
12. Stone PA, Hofeldt MJ, Campbell JE, et al. Meckel Diverticulum: Ten-year Experience in Adults. *Southern Medical Journal*. 2004;97:1038-41. doi:10.1097/01.SMJ.0000125222.90696.03
13. Ding Y, Zhou Y, Ji Z, et al. Laparoscopic management of perforated Meckel's diverticulum in adults. *International Journal of Medical Sciences*. 2012; 9(3):243-7. doi:10.7150/ijms.4170

Дополнительная информация [Additional Info]

Источник финансирования. Бюджет ФГБОУ ВО Курский государственный медицинский университет Минздрава России. [Financing of study. Budget of Kursk State Medical University.]

Конфликт интересов. Авторы декларируют отсутствие явных и потенциальных конфликтов интересов, о которых необходимо сообщить в связи с публикацией данной статьи. [Conflict of interests. The authors declare no actual and potential conflict of interests which should be stated in connection with publication of the article.]

Участие авторов. Гаврилюк В.П. – курация пациента, разработка концепции статьи, редактирование текста, ответственность за целостность всех частей статьи, Костин С.В. – курация пациента, ведение послеоперационного периода, редактирование текста, ответственность за целостность всех частей статьи, Мучкина В.А. – участие в оперативном вмешательстве, подготовка и компоновка текста, Северинов Д.А. – подготовка и компоновка текста, редактирование, Косолапова Н.В. – подготовка и компоновка текста, редактирование. [Participation of authors. V.P. Gavrilyuk – patient supervision, development of the concept of the article, editing of the text, responsibility for the integrity of all parts of the article; S.V. Kostin – patient supervision, post-operation period maintenance, text editing, responsibility for integrity of all parts of the article; V.A. Muckina – participation in operational intervention, preparation and layout of the text; D.A. Severinov – text preparation and layout, editing; N.V. Kosolapova – text preparation and layout, editing].

Информация об авторах [Authors Info]

Гаврилюк Василий Петрович – д.м.н., доц., зав. кафедрой детской хирургии и педиатрии факультета последипломного образования, ФГБОУ ВО Курский государственный медицинский университет Минздрава России, Курск, Россия. [Vasily P. Gavrilyuk – MD, PhD, Associate Professor, Head of the Department of Pediatric Surgery and Pediatrics of Postdegree Education Faculty, Kursk State Medical University, Kursk, Russia.]
SPIN: 2730-4515, ORCID: 0000-0003-4792-1862, Researcher ID: H-2186-2013.

Костин Станислав Витальевич – к.м.н., доцент кафедры детской хирургии и педиатрии факультета последипломного образования, ФГБОУ ВО Курский государственный медицинский университет Минздрава России; зав. отделением детской хирургии, ОБУЗ Курская областная детская больница №2, Курск, Россия. [Stanislav V. Kostin – MD, PhD, Associate Professor of the Department of Pediatric Surgery and Pediatrics of Postdegree Education Faculty, Kursk State Medical University; Head of the Department of Pediatric's Surgery, Kursk Regional Children's Hospital №2, Kursk, Russia.]
SPIN: 7242-5368, ORCID: 0000-0003-0857-6437.

Мучкина Валентина Александровна – врач-детский хирург отделения детской хирургии, ОБУЗ Курская областная детская больница №2, Курск, Россия. [Valentina A. Muchkina – Pediatric Surgeon, Kursk Regional Children's Hospital №2, Kursk, Russia.]
SPIN: 5272-2412, ORCID: 0000-0003-3347-5611, Researcher ID: G-4584-2014.

***Северинов Дмитрий Андреевич** – ассистент кафедры детской хирургии и педиатрии факультета последипломного образования, ФГБОУ ВО Курский государственный медицинский университет Минздрава России, Курск, Россия. [Dmitry A. Severinov – Assistant of the Department of Pediatric Surgery and Pediatrics of Postdegree Education Faculty, Kursk State Medical University, Kursk, Russia.]
SPIN: 1966-0239, ORCID: 0000-0003-4460-1353, Researcher ID: G-4584-2017. E-mail: dmitry.severinov.93@mail.ru

Косолапова Наталья Викторовна — зав. рентгеновским кабинетом, ОБУЗ Курская областная детская больница № 2, Курск, Россия. [Natalia V. Kosolapova – Head of the X-ray Cabinet, Kursk Regional Children's Hospital №2, Kursk, Russia.]
SPIN: 3111-5055, ORCID ID: 0000-0002-2044-160X, Researcher ID: G-4584-2015.

Цитировать: Гаврилюк В.П., Костин С.В., Мучкина В.А., Северинов Д.А., Косолапова Н.В. Инородное тело (монета) Меккелева дивертикула у ребенка двух лет // Российский медико-биологический вестник имени академика И.П. Павлова. 2020. Т. 28, №1. С. 73-78. doi:10.23888/PAVLOVJ202028173-78

To cite this article: Gavrilyuk VP, Kostin SV, Muchkina VA, Severinov DA, Kosolapova NV. A foreign body (a coin) of Meckel's diverticulum in a two-year-old child. *I.P. Pavlov Russian Medical Biological Herald*. 2020;28(1):73-8. doi:10.23888/PAVLOVJ202028173-78

Поступила/Received: 21.12.2019
Принята в печать/Accepted: 31.03.2020