

УДК 616.14-007.17-089.27

DOI: <https://doi.org/10.17816/PAVLOVJ62354>

## Опыт использования склерооблитерации при венозных ангиодисплазиях (результаты 12-месячного наблюдения)

С.В. Сапелкин, Н.А. Дружинина✉, А.Ф. Харазов, А.В. Чупин

Национальный медицинский исследовательский центр хирургии им. А.В. Вишневского, Москва, Россия

### АННОТАЦИЯ

**Обоснование.** Резекционные вмешательства при венозных ангиодисплазиях связаны с рисками массивной кровопотери и не всегда могут обеспечить полное удаление ангиоматозных тканей и хороший косметический результат. В мировой практике в противовес открытым операциям успешно применяется склерооблитерация — минимально инвазивная методика, заключающаяся во введении склерозирующего препарата в полость венозных каверн, что в дальнейшем приводит к облитерации.

**Цель.** Оценка результатов применения минимально инвазивной методики склерооблитерации у пациентов с венозными мальформациями.

**Материалы и методы.** В период с 2006 по 2020 гг. было выполнено 41 вмешательство по поводу венозно-кавернозного ангиоматоза различной локализации с применением метода склерооблитерации. 19 пациентам проведено комплексное лечение, в которое входила комбинация данной методики с другими оперативными вмешательствами (резекцией ангиоматозных тканей, лазерной и радиочастотной облитерацией).

**Результаты.** Клиническое улучшение достигнуто у 38 пациентов. По данным ультразвукового контроля у 25 пациентов зафиксировано отсутствие кровотока в зоне облитерации, регресс исходной симптоматики в течение 1 года наблюдения после вмешательства. При локальном распространении ангиоматозного процесса результаты лечения оказались лучше (при диффузных формах не удалось достичь положительного эффекта у 3 пациентов).

**Выводы.** Склерооблитерация может обеспечить положительный результат в лечении пациентов с венозно-кавернозными ангиодисплазиями как в качестве самостоятельного метода, так и в сочетании с другими минимально инвазивными методиками и резекцией ангиоматозных тканей.

**Ключевые слова:** венозные ангиодисплазии; венозно-кавернозный ангиоматоз; склерооблитерация; склерозант; минимально инвазивные методики; лечение ангиодисплазий

### Для цитирования:

Сапелкин С.В., Дружинина Н.А., Харазов А.Ф., Чупин А.В. Опыт использования склерооблитерации при венозных ангиодисплазиях (результаты 12-месячного наблюдения) // Российский медико-биологический вестник имени академика И.П. Павлова. 2021. Т. 29, № 3. С. 411–418. DOI: <https://doi.org/10.17816/PAVLOVJ62354>

DOI: <https://doi.org/10.17816/PAVLOVJ62354>

## Experience of using scleroobliteration in venous angiodysplasia (results of 12-month follow-up)

Sergey V. Sapelkin, Natal'ya A. Druzhinina✉, Aleksandr F. Kharazov,  
Andrey V. Chupin

Vishnevsky National Medical State Center of Surgery, Moscow, Russia

### ABSTRACT

**BACKGROUND:** Resection interventions with venous angiodysplasia are associated with risks of massive blood loss and cannot always ensure complete elimination of angiomatous tissues and good cosmetic result. In clinical practice, contrary to open surgeries, scleroobliteration, a minimally invasive technique that introduces a sclerosing agent into the cavity of venous caverns, which later leads to obliteration, is successfully used.

**AIM:** To evaluate the results of using the minimally-invasive technique of scleroobliteration in patients with venous malformations.

**MATERIALS AND METHODS:** From 2006 to 2020, 41 interventions were performed for venous-cavernous angiomatosis of various localization through scleroobliteration. Nineteen patients (46.3%) underwent complex treatment, which included a combination of this minimally-invasive technique with other surgical interventions (resection of angiomatous tissues, laser coagulation, and radiofrequency obliteration).

**RESULTS:** Clinical improvement was achieved in 38 (92.7%) patients. According to the data of ultrasound control, 25 patients (61%) experienced no blood flow in the obliteration zone, and there was regression of the initial symptoms within 1 year of observation following intervention. The results of treatment were better due to the local spread of the angiomatous process. With diffuse forms, it was not possible to achieve a positive effect in 3 patients (11.1%).

**CONCLUSION:** Scleroobliteration can provide a positive result in the treatment of patients with venous-cavernous angiodysplasia, both as an independent method and in combination with other minimally-invasive techniques.

**Keywords:** *venous angiodysplasia; venous-cavernous angiomatosis; scleroobliteration; sclerosant; minimally invasive techniques; treatment of angiodysplasias*

### For citation:

Sapelkin SV, Druzhinina NA, Kharazov AF, Chupin AV. Experience of using scleroobliteration in venous angiodysplasia (results of 12-month follow-up). *I.P. Pavlov Russian Medical Biological Herald*. 2021;29(3):411–418. DOI: <https://doi.org/10.17816/PAVLOVJ62354>

Received: 01.03.2021

Accepted: 05.07.2021

Published: 30.09.2021

## BACKGROUND

This work is a part of a large investigation on minimally invasive methods conducted at the Department of Vascular Surgery of Vishnevsky National Medical Research Center of Surgery.

This paper evaluates the results of a minimally invasive method such as scleroobliteration in patients with venous malformation and discusses how to improve the treatment results. We presented earlier the treatment results of patients with venous cavernous angiomas and lesions at a depth of more than 10 mm from the skin surface using the radiofrequency obliteration method [1].

Having first appeared at an early age, venous dysplasia progressively develops throughout the life of the patient [2, 3]. The variability of clinical manifestations (from asymptomatic course to life-threatening situations) poses a question about the choice of treatment method, which could not only help relieve the symptoms but also improve the social adaptation of patients [4, 5].

Resection interventions are associated with risks of massive blood loss and cannot always ensure complete elimination of angiomatic tissues and good cosmetic result. In clinical practice, contrary to open surgeries, scleroobliteration, a minimally invasive technique

that introduces a sclerosing agent into the cavity of venous caverns, which later leads to obliteration, is successfully used.

**Aim** — to evaluate the results of using a minimally invasive scleroobliteration technique in patients with venous malformations.

## MATERIALS AND METHODS

This study includes 41 patients with venous-cavernous form of angiodysplasia who underwent sclerotherapy procedures in the period from 2006 to 2020 at the Department of Vascular Surgery of Vishnevsky National Medical Research Center of Surgery.

In the preoperative stage, all patients underwent ultrasound (US) examination and computed tomography (CT), to determine the volume and depth of the lesion and size of venous caverns and clarify the relations with the surrounding anatomical structures.

The clinical and demographic characteristics of the analyzed group of patients are shown in Table 1. The peculiarity of the group under study is having lesions at a depth of less than 10 mm from the skin surface, which is a limitation for minimally invasive techniques other than scleroobliteration. In US, special attention was given to the depth of angiomatic process, lesion area, and size of venous caverns (Figure 1).

**Table 1.** Clinical and demographic characteristics of patients with venous dysplasia (n = 41)

Parameters	Local lesion	Diffuse lesion	Total
Men, n	4	4	8
Age, years, M ± m	29 ± 13	30 ± 14	30 ± 9
Location of venous dysplasia, n:			
head	7	6	13
neck	1	2	3
trunk	1	2	3
upper limbs	1	1	2
lower limbs	4	16	20
Complaints, n:			
cosmetic defect	8	27	35
pain	12	24	36
edema	10	22	32
bleeding	0	1	1
Preceding treatment, n	5	19	24
Total number of patients, n	14	27	41

**Scleroobliteration Technique.** Percutaneous scleroobliteration can be used as the main method of treatment. To perform the intervention, an ultrasound control of the sclerosant injection zone is required for the correct positioning of the puncture needle. The drug is administered by injection with a 27–30 G needle. A liquid form of polidocanol was used in direct

skin lesions. The concentration of the drug should be not more than 0.5% to avoid complications in the postoperative period. Some cases require a foam form of 0.5%–3% of the drug in a volume of up to 4 ml, prepared using Tessari L.'s technique (Figure 2). After surgical intervention, compression with bandages of a low degree of distensibility was performed.

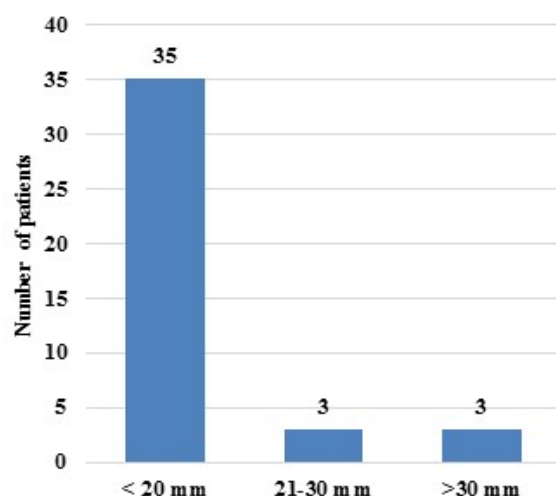


Fig. 1. Incidence of venous caverns in the group under study (n = 41), according to the size.

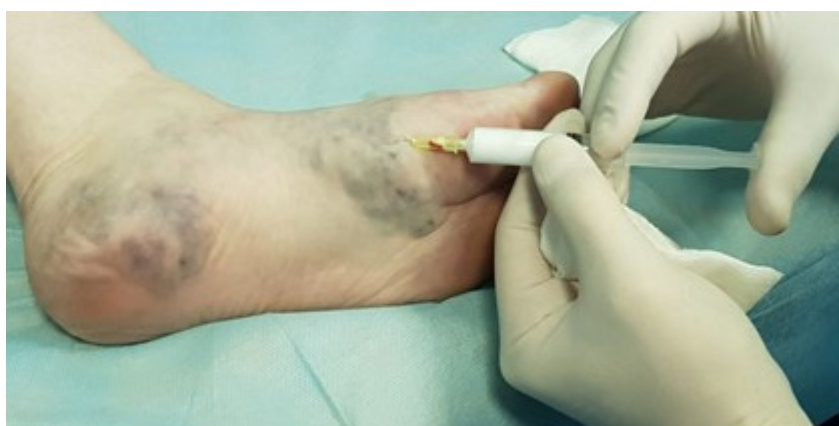

Fig. 2. Microfoam scleroobliteration in diffuse lesion of the foot.

#### ***Resection Intervention and Scleroobliteration.***

According to the scope of the lesion, scleroobliteration alone does not guarantee satisfactory therapeutic results. This is especially important when the lesion is diffuse and involves several anatomic areas. In such a case, it is not always possible to decide to have a resection and scleroobliteration in one surgical intervention at the preoperative diagnosis. Complete removal of venous caverns in the open intervention is often associated with the risk of damage to the vessels and nerves involved in the pathological process. If the spread of the process did not permit expanding the surgical access for resection of residual caverns, they were obliterated using a single injection of the foam form of 1.5%–3% polidocanol. Stepwise treatment was conducted several days after the first intervention in patients where the control ultrasound

showed the residual caverns or if small volumes of the angiomatous process were present in the neighboring anatomic area (for example, resection intervention on shin and scleroobliteration on the foot).

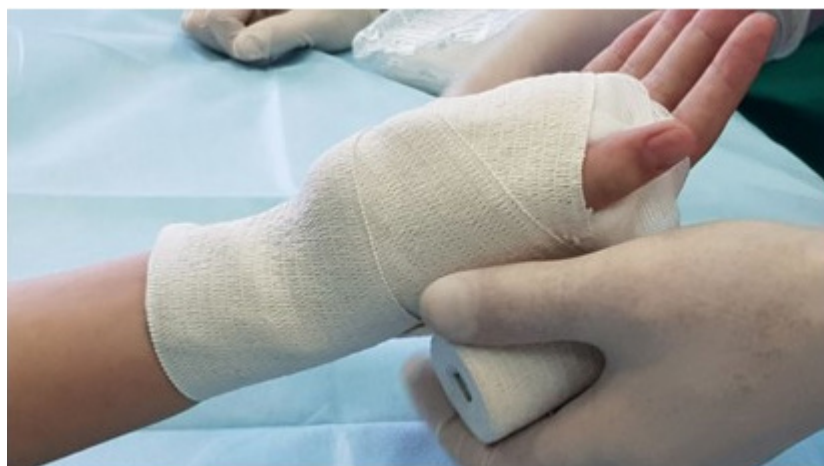Repeated sessions of scleroobliteration are possible in one to three months. This period is necessary for the patient to recover after surgical intervention and to reduce the risk of complications.

Twenty-two patients underwent isolated scleroobliteration. It was conducted as a part of combined treatment in 19 patients. Resection intervention and scleroobliteration were performed simultaneously or within a two-to-three-day interval in 11 patients. Scleroobliteration was combined with laser coagulation in three patients and with radiofrequency obliteration in five patients.

The results were evaluated on the basis of successful obliteration of the intervention zone and improvement of the quality of patient's life (clinical examination and US). The follow-up period was one year with intermediate visits in the third and sixth months after the first session. The results are presented using means of descriptive statistics.

## RESULTS

Immediately after the introduction of the sclerosant, a significant pain was felt at the site of drug introduction, which regressed by the time the procedure was completed. Afterward, compression with elastic bandages of a low degree of distensibility was performed (Figure 3).

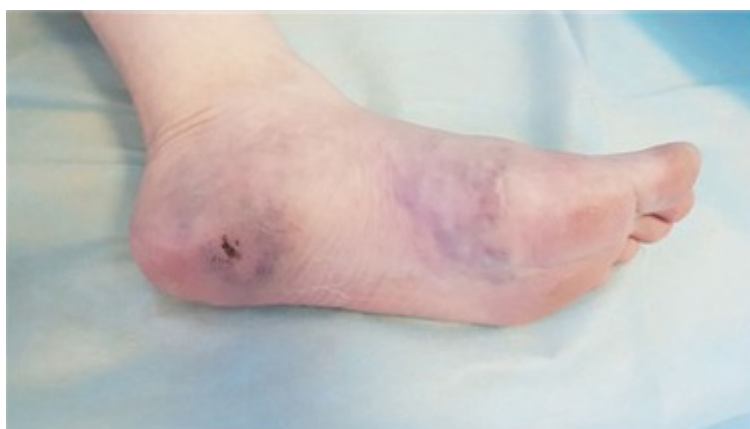

**Fig. 3.** Compression with elastic bandages with a low degree of distensibility after scleroobliteration of the local venous caverns of wrist.

Edema of the intervention zone in the postoperative period was not interpreted as a complication, except for the appearance of conditions that complicated the course of the disease. A pronounced edematous syndrome, which required dynamic observation at the resuscitation unit, was present in three patients with a local angiomatous process on the tongue.

The regress of the initial complications was recorded in 38 patients. Twenty-five patients experienced an absence of blood flow in the surgical intervention zone and complete regression of the pain and edematous syndrome.

Satisfactory results (significant relief of pain and obliteration of venous caverns, as shown in Figure 4) were achieved in 10 patients (Table 2).



**Fig. 4.** Result of scleroobliteration in three months (after two sessions). Significant volume reduction in the pathological venous caverns.

**Table 2.** Results of scleroobliteration during 12 months of follow-up, according to the spread of angiomatous process (n = 41)

Spread	Result			Total, n
	Good, n	Satisfactory, n	With no effect, n	
Local	10	4	0	14
Diffuse	18	6	3	27
Total	28	10	3	41

Only three of 41 patients, with diffuse spread of the process, reported no clinical improvement one year after the intervention, of which two underwent scleroobliteration and one received a complex treatment. The initial size of caverns before treatment was more than 30 mm. On visits in the third and sixth months, postoperative obliteration was partial or was absent altogether. In these three patients, a progressive increase in the angiomatous process was recorded.

In patients with a local lesion (n = 14), positive dynamics were achieved; a complex approach was used in eight patients. Complete obliteration of the intervention zone was achieved in 10 patients.

## DISCUSSION

To discuss the obtained results, one should note a clear global tendency of using minimally invasive techniques when treating patients with venous dysplasia [6–9].

We mentioned our previous experience in managing 42 patients who underwent radiofrequency obliteration of angiomatous tissues as the main treatment method; a positive result was obtained in more than 88% of the patients [1]. However, there exist certain limitations that do not allow using this technique for lesions at a depth of less than 10 mm from the skin surface. This is associated with a high risk of thermal lesions and resultant trophic disorders over the area of intervention. The method of choice in such a situation is scleroobliteration.

Currently, scleroobliteration started to actively compete with resection interventions providing surgeons with a choice in the tactics of medical assistance. The advantages of sclerotherapy are relative availability of the method and the possibility of performing the surgical intervention in both inpatient and outpatient settings.

For a long time, the gold standard of scleroobliteration was the use of ethanol. Treatment using ethanol has proven effective in 75%–95% of the patients. However, introducing the drug is accompanied by a pronounced pain syndrome at the moment of injection

and may cause complications such as skin necrosis, damage to the peripheral nerves, and muscular fibrosis [10–12]. Therefore, safer drugs for scleroobliteration of venous caverns gradually replaced ethanol. Detergents such as polidocanol and sodium tetradecyl sulfate are used instead of ethanol. Their foam form is obtained by mixing the drug with air using techniques proposed by Tessari L. [13, 14]. Their mechanism of action is neutralizing the blood cell membranes, albumin, and plasma proteins [15–18]. The choice of the concentration (0.5%–3%) is determined by the depth and volume of lesion [19]. The microfoam form of the sclerosant squeezes out the blood present in the vessel, which increases the surface area of contact with the wall, promoting better obliteration [14].

Attention should be paid to the fact that there are restrictions on the amount of the drug allowed to be injected into the venous cavity in one intervention. It is recommended that not more than 0.3 ml of 3% polidocanol solution be used in one injection. Moreover, one should consider the air used to prepare the foam form of the solution according to Tessari's method. This is considered a limitation in patients with large volumes of the angiomatous process, which requires a combined or staged treatment.

It is recommended that microfoam scleroobliteration be performed under the guidance of US, which provides both the highest effect and maximum safety as the drug is applied directly to lesion zone [20].

## CONCLUSION

The clinical effectiveness of microfoam scleroobliteration using polidocanol in treating patients with venous angiodysplasias was demonstrated. The main aim of treatment is relief of pain syndrome and reduction of the volume of the formation and achieving an acceptable cosmetic result. To obtain these results, several stages of scleroobliteration are needed. The microfoam form of the drug shows good results in both local and diffuse lesions.

## ADDITIONAL INFORMATION

**Funding.** Budget of Vishnevsky National Medical State Center of Surgery.

**Conflict of interest.** The authors declare no conflict of interests.

**Patient consent.** The study used data from people in accordance with signed informed consent.

**Contribution of the authors:** N.A. Druzhinina — concept and design of the study, collection and processing of the material, writing the text, editing, S.V. Sapelkin — concept and design of the study, editing, A.V. Chupin, A.F. Kharazov — editing.

**Финансирование.** Бюджет Национального медицинского исследовательского центра хирургии им. А.В. Вишневского.

**Конфликт интересов.** Авторы заявляют об отсутствии конфликта интересов.

**Согласие на публикацию.** В исследовании использованы данные людей в соответствии с подписанным информированным согласием.

**Вклад авторов:** Дружинина Н.А. — концепция и дизайн исследования, сбор и обработка материала, написание текста, редактирование, Сапелкин С.В. — концепция и дизайн исследования, редактирование, Чупин А.В., Харазов А.Ф. — редактирование.

## СПИСОК ИСТОЧНИКОВ

1. Сапелкин С.В., Дружинина Н.А., Чупин А.В., и др. Методика радиочастотной облитерации в лечении пациентов с венозными ангиодисплазиями // Российский медико-биологический вестник имени академика И.П. Павлова. 2021. Т. 29, № 1. С. 89–98. doi: 10.23888/PAVLOVJ202129189-98
2. Mulliken J.B., Glowacki J. Hemangiomas and vascular malformations in infants and children: a classification based on endothelial characteristics // Plastic and Reconstructive Surgery. 1982. Vol. 69, № 3. P. 412–422. doi: 10.1097/00006534-198203000-00002
3. Finn M.C., Glowacki J., Mulliken J.B. Congenital vascular lesions: clinical application of a new classification // Journal of Pediatric Surgery. 1983. Vol. 18, № 6. P. 894–900. doi: 10.1016/s0022-3468(83)80043-8
4. Lee B.B., Kim D.I., Kim H.H., et al. New experiences with absolute ethanol sclerotherapy in the management of a complex form of congenital venous malformation // Journal of Vascular Surgery. 2001. Vol. 33, № 4. P. 764–772. doi: 10.1067/mva.2001.112209
5. Fishman S.J., Mulliken J.B. Vascular anomalies. A primer for pediatricians // Pediatric Clinics of North America. 1998. Vol. 45, № 6. P. 1455–1477. doi: 10.1016/s0031-3955(05)70099-7
6. Park H.S., Do Y.S., Park K.B., et al. Clinical outcome and predictors of treatment response in foam sodium tetradecyl sulfate sclerotherapy of venous malformations // European Radiology. 2016. Vol. 26, № 5. P. 1301–1310. doi: 10.1007/s00330-015-3931-9
7. Ahmad S. Efficacy of Percutaneous Sclerotherapy in Low Flow Venous Malformations — a Single Center Series // Neurointervention. 2019. Vol. 14, № 1. P. 53–60. doi: 10.5469/neuroint.2019.00024
8. Kumar S., Bhavana K., Sinha A.K., et al. Image-Guided Percutaneous Injection Sclerotherapy of Venous Malformations // SN Comprehensive Clinical Medicine. 2020. Vol. 2. P. 1462–1490. doi: 10.1007/s42399-020-00412-y
9. Chen R.J., Vrazas J.I., Penington A.J. Surgical Management of Intramuscular Venous Malformations // Journal of Pediatric Orthopaedics. 2021. Vol. 41, № 1. P. e67–e73. doi: 10.1097/BPO.0000000000001667
10. Zhang J., Li H.-B., Zhou S.Y., et al. Comparison between absolute ethanol and bleomycin for the treatment of venous malformation in children // Experimental and Therapeutic Medicine. 2013. Vol. 6, № 2. P. 305–309. doi: 10.3892/etm.2013.1144
11. Su L., Fan X., Zheng L., et al. Absolute ethanol sclerotherapy for venous malformations in the face and neck // Journal of Oral and Maxillofacial Surgery. 2010. Vol. 68, № 7. P. 1622–1627. doi: 10.1016/j.joms.2009.07.094
12. Spence J., Krings T., TerBrugge K.G., et al. Percutaneous treatment of facial venous malformations: a matched comparison of alcohol and bleomycin sclerotherapy // Head & Neck. 2011. Vol. 33, № 1. P. 125–130. doi: 10.1002/hed.21410
13. Parsi K., Exner T., Connor D., et al. Letter: A Convenient Source of Carbon Dioxide for Sclerosant Foams // Dermatologic Surgery. 2006. Vol. 32, № 12. P. 1533–1534. doi: 10.1111/j.1524-4725.2006.32370.x
14. Cavezzi A., Flullini A., Ricci S., et al. Treatment of varicose veins by foam sclerotherapy: two clinical series // Phlebology. 2002. Vol. 17, № 1. P. 13–18. doi: 10.1007/BF02667958
15. Parsi K., Exner T., Connor D., et al. The lytic effects of detergent sclerosants on erythrocytes, platelets, endothelial cells and microparticles are attenuated by albumin and other plasma components in vitro // European Journal of Vascular and Endovascular Surgery. 2008. Vol. 36, № 2. P. 216–223. doi: 10.1016/j.ejvs.2008.03.001
16. Watkins M.R. Deactivation of sodium tetradecyl sulphate injection by blood proteins // European Journal of Vascular and Endovascular Surgery. 2011. Vol. 41, № 4. P. 521–525. doi: 10.1016/j.ejvs.2010.12.012
17. Tessari L., Izzo M., Cavezzi A., et al. Timing and modality of the sclerosing agents binding to the human proteins: laboratory analysis and clinical evidences // Veins and Lymphatics. 2014. Vol. 3, № 1. P. 3275. doi: 10.4081/vl.2014.3275
18. Connor D., Cooley-Andrade O., Goh W.X., et al. Detergent sclerosants are deactivated and consumed by circulating blood cells // European Journal of Vascular and Endovascular Surgery. 2015. Vol. 49, № 4. P. 426–431. doi: 10.1016/j.ejvs.2014.12.029
19. Lee B.B., Glowiczki P., Blei F., editors. Vascular Malformations: Advances and Controversies in Contemporary Management. CRC Press; 2020. P. 166.
20. Star P., Connor D., Parsi K. Novel developments in foam sclerotherapy: Focus on Varithena® (polidocanol endovenous microfoam) in the management of varicose veins // Phlebology. 2018. Vol. 33, № 3. P. 150–162. doi: 10.1177/0268355516687864

## REFERENCES

1. Sapelkin SV, Druzhinina NA, Chupin AV, et al. Radiofrequency obliteration in treatment of venous angiodysplasia. *I. P. Pavlov Russian Medical Biological Herald*. 2021;29(1):89–98. (In Russ). doi: 10.23888/PAVLOVJ202129189-98
2. Mulliken JB, Glowacki J. Hemangiomas and vascular malformations in infants and children: a classification based on endothelial characteristics. *Plastic and Reconstructive Surgery*. 1982;69(3):412–22. doi: 10.1097/00006534-198203000-00002

3. Finn MC, Glowacki J, Mulliken JB. Congenital vascular lesions: clinical application of a new classification. *Journal of Pediatric Surgery*. 1983;18(6):894–900. doi: 10.1016/s0022-3468(83)80043-8
4. Lee BB, Kim DI, Kim HH, et al. New experiences with absolute ethanol sclerotherapy in the management of a complex form of congenital venous malformation. *Journal of Vascular Surgery*. 2001;33(4):764–72. doi: 10.1067/mva.2001.112209
5. Fishman SJ, Mulliken JB. Vascular anomalies. A primer for pediatricians. *Pediatric Clinics of North America*. 1998;45(6):1455–77. doi: 10.1016/s0031-3955(05)70099-7
6. Park HS, Do YS, Park KB, et al. Clinical outcome and predictors of treatment response in foam sodium tetradecyl sulfate sclerotherapy of venous malformations. *European Radiology*. 2016;26(5):1301–10. doi: 10.1007/s00330-015-3931-9
7. Ahmad S. Efficacy of Percutaneous Sclerotherapy in Low Flow Venous Malformations — a Single Center Series. *Neurointervention*. 2019;14(1): 53–60. doi: 10.5469/neuroint.2019.00024
8. Kumar S, Bhavana K, Sinha AK, et al. Image-Guided Percutaneous Injection Sclerotherapy of Venous Malformations. *SN Comprehensive Clinical Medicine*. 2020;2:1462–90. doi: 10.1007/s42399-020-00412-y
9. Chen RJ, Vrazas JI, Penington AJ. Surgical Management of Intramuscular Venous Malformations. *Journal of Pediatric Orthopaedics*. 2021;41(1):e67–e73. doi: 10.1097/BPO.0000000000001667
10. Zhang J, Li H-B, Zhou SY, et al. Comparison between absolute ethanol and bleomycin for the treatment of venous malformation in children. *Experimental and Therapeutic Medicine*. 2013;6(2):305–9. doi: 10.3892/etm.2013.1144
11. Su L, Fan X, Zheng L, et al. Absolute ethanol sclerotherapy for venous malformations in the face and neck. *Journal of Oral and Maxillofacial Surgery*. 2010;68(7):1622–7. doi: 10.1016/j.joms.2009.07.094
12. Spence J, Krings T, TerBrugge KG, et al. Percutaneous treatment of facial venous malformations: a matched comparison of alcohol and bleomycin sclerotherapy. *Head & Neck*. 2011;33(1):125–30. doi: 10.1002/hed.21410
13. Parsi K, Exner T, Connor D, et al. Letter: A Convenient Source of Carbon Dioxide for Sclerosant Foams. *Dermatologic Surgery*. 2006;32(12):1533–4. doi: 10.1111/j.1524-4725.2006.32370.x
14. Cavezzi A, Fullini A, Ricci S, et al. Treatment of varicose veins by foam sclerotherapy: two clinical series. *Phlebology*. 2002;17(1):13–8. doi: 10.1007/BF02667958
15. Parsi K, Exner T, Connor D, et al. The lytic effects of detergent sclerosants on erythrocytes, platelets, endothelial cells and microparticles are attenuated by albumin and other plasma components in vitro. *European Journal of Vascular and Endovascular Surgery*. 2008;36(2):216–23. doi: 10.1016/j.ejvs.2008.03.001
16. Watkins MR. Deactivation of sodium tetradecyl sulphate injection by blood proteins. *European Journal of Vascular and Endovascular Surgery*. 2011;41(4):521–5. doi: 10.1016/j.ejvs.2010.12.012
17. Tessari L, Izzo M, Kavezzi A, et al. Timing and modality of the sclerosing agents binding to the human proteins: laboratory analysis and clinical evidences. *Veins and Lymphatics*. 2014;3(1):3275. doi: 10.4081/vl.2014.3275
18. Connor D, Cooley-Andrade O, Goh WX, et al. Detergent sclerosants are deactivated and consumed by circulating blood cells. *European Journal of Vascular and Endovascular Surgery*. 2015;49(4):426–31. doi: 10.1016/j.ejvs.2014.12.029
19. Lee BB, Glociczki P, Blei F, editors. *Vascular Malformations: Advances and Controversies in Contemporary Management*. CRC Press; 2020. P. 166.
20. Star P, Connor D, Parsi K. Novel developments in foam sclerotherapy: Focus on Varithena® (polidocanol endovenous microfoam) in the management of varicose veins. *Phlebology*. 2018;33(3):150–62. doi: 10.1177/0268355516687864

## ОБ АВТОРАХ

**Сапелкин Сергей Викторович**, д-р мед. наук, профессор;  
ORCID: <https://orcid.org/0000-0003-3610-8382>;  
eLibrary SPIN: 3040-0699, e-mail: ssapelkin@yandex.ru

**\*Дружинина Наталья Александровна**;  
ORCID: <https://orcid.org/0000-0002-6994-7310>;  
eLibrary SPIN: 9124-0358, e-mail: dna13@mail.ru

**Харазов Александр Феликсович**, канд. мед. наук;  
ORCID: <https://orcid.org/0000-0002-6252-2459>;  
eLibrary SPIN: 5239-8127, e-mail: harazik@mail.ru

**Чупин Андрей Валерьевич**, д-р мед. наук;  
ORCID: <https://orcid.org/0000-0002-5216-9970>;  
eLibrary SPIN: 7237-4582

## AUTHOR'S INFO

**Sergey V. Sapelkin**, MD, Dr. Sci. (Med.), Professor;  
ORCID: <https://orcid.org/0000-0003-3610-8382>;  
eLibrary SPIN: 3040-0699, e-mail: ssapelkin@yandex.ru

**\*Natal'ya A. Druzhinina**;  
ORCID: <https://orcid.org/0000-0002-6994-7310>;  
eLibrary SPIN: 9124-0358, e-mail: dna13@mail.ru

**Aleksandr F. Kharazov**, MD, Cand. Sci. (Med.);  
ORCID: <https://orcid.org/0000-0002-6994-7310>;  
eLibrary SPIN: 9124-0358, e-mail: dna13@mail.ru

**Andrey V. Chupin**, MD, Dr. Sci. (Med.);  
ORCID: <https://orcid.org/0000-0002-5216-9970>;  
eLibrary SPIN: 7237-4582

\* Автор, ответственный за переписку/Corresponding author