

**СЛУЧАЙ УСПЕШНОГО ОПЕРАТИВНОГО ЛЕЧЕНИЯ ПАЦИЕНТА
С ЛИМФЕДЕМОЙ НИЖНИХ КОНЕЧНОСТЕЙ**

© П.Н. Мышенцев, С.Е. Каторкин, Л.А. Личман

ФГБОУ ВО Самарский государственный медицинский университет
Минздрава России, Самара, Россия

Актуальность лечения пациентов с лимфедемой нижних конечностей обусловлена трудностями их медицинской и социальной реабилитации. При выраженных стадиях заболевания показаны резекционные операции, которые являются сложными вмешательствами. В работе представлено клиническое наблюдение пациентки 33 лет с первичной лимфедемой правой нижней конечности IV стадии. На фоне проводимого консервативного лечения после комплексного обследования, включавшего волуметрию, ультразвуковое исследование, компьютерную томографию, пациентке проведена дермалипофасциэктомия с применением методики *shave therapy*. Пациентке под спинномозговой анестезией проведена операция модифицированной дермалипофасциэктомии голени по Караванову II с использованием моно- и биполярной электрокоагуляции. Во время операции на этапе удаления фиброизмененных тканей использовался дерматом Acculan 3Ti (GA 670) с регулируемыми диапазонами толщины 0,2-1,2 мм и ширины 8-78 мм. Интраоперационная кровопотеря составила 800 мл и возмещалась кристаллоидными, коллоидными растворами и свежезамороженной плазмой в объеме 600 мл. Активное дренирование области послеоперационной раны по Редону проводилось в течение 10-12 суток. Послеоперационный период протекал без осложнений, наблюдалось улучшение состояния пациентки.

Клиническое наблюдение показало, что использование аппарата *shave therapy* играет положительную роль в проведении основного этапа резекционных операций.

Ключевые слова: лимфедема; оперативное лечение; нижние конечности.

**A CASE OF SUCCESSFUL SURGICAL TREATMENT OF A PATIENT
WITH LYMPHEDEMA OF LOWER LIMBS**

P.N. Myshencev, S.E. Katorkin, L.A. Lichman

Samara State Medical University, Samara, Russia

The importance of treatment of patients with lymphedema of lower limbs arises from difficulties in their medical and social rehabilitation. At the expressed stages of the disease resection surgical operations are indicated which present complicated interventions. In the work clinical observation of a 33 year-old female patient with IV stage of primary lymphedema of the right lower limb is presented. In the course of conservative treatment after a complex examination including volumetry, ultrasound, computed tomography, the patient was made dermalipofascioectomy using method of *shave therapy*. The operation of modified dermalipofascioectomy of the shin was performed by Karavanov II method under spinal anesthesia with use of mono-



and bipolar coagulation. At the stage of elimination of fibrotically changed tissue dermatome Acculan 3Ti (GA 670) was used with controlled ranges of thickness within 0.2-1.2 mm and width within 8-78 mm. Intraoperative loss of blood and lymph was 800 ml and was compensated for with crystalloid, colloid solutions and fresh frozen plasma in the volume of 600 ml. Active drainage of the region of the postoperative wound was conducted by Redon method within 10-12 days. Postoperative period ran without complications, with improvement of the patient's condition.

Clinical observation showed a positive role of application of *shave therapy* apparatus at the main stage of resection operations.

Keywords: *lymphedema; surgical treatment; lower limbs.*

In recent decades a tendency to increased incidence of lymphedema is noted that is mainly associated with increased number of surgical interventions and courses of radiation therapy in oncological patients. Besides, there is also noted increase in the incidence of different inflammatory diseases and malformations of the lymphatic system [1,2]. The social significance of this disease lies in the fact that the majority of patients are individuals of the working age and in this context there arises a problem of a long-term and systematic medical rehabilitation [3]. Selection of the rational therapeutic strategy in lymphedema is undoubtedly a complicated and difficult task [4-6]. A doubtful prognosis and low therapeutic potentials still continue to create an opinion in some doctors about absence of any prospects for treatment of patients with lymphedema. This is especially true of III-IV stages of the disease manifested by pronounced fibrotic changes of soft tissues and significant progressing enlargement of a limb with its stable deformation.

The most effective method of surgical treatment of such patients is resection operational interventions. They are collectively called dermalipofascioectomy since they suggest excision of fibrotically changed skin, subcutaneous tissue and fascia with subsequent reimplantation of skin. Taking into account the volume of the operation, difficulties in treatment of the affected tissues of dense consistency, significant loss of blood and lymph, dermalipofascioectomies are referred to rather complicated interventions. In view of this, an important task is use of methods

and techniques permitting to improve such surgical interventions. In surgical treatment of patients with venous trophic ulcers a method of *shave therapy* is effectively used for removal of scar tissues [7-10]. In our opinion, an actual task is a potential application of this method for treatment of patients with IV stage of lymphedema.

Clinical Case

A female patient of 33 years old, was delivered to a hospital with complaints of evident edema and a feeling of weight in the right lower limb.

As known from the anamnesis, a mild edema of the right lower limb appeared at the age of 3 years. According to the patient's parents, she was consulted in a Moscow clinic. No treatment was given. A rapid progression of edema started after pregnancy and repeated erysipelatosus inflammations of the right shin. Outpatient treatment (courses of phlebotonic medications: rutosides, diosmin, extraction of red grape leaves, preparations of enzyme therapy) was ineffective. Due to progressing edema, wearing of compression garments became impossible.

On examination, an evident deforming dense edema of the right foot and shin with the phenomena of hyperkeratosis and papillomatosis of skin was identified (Fig. 1).

Measurement of the circumference of the right shin showed increased perimeters from 6 to 18 cm on different levels as compared to the left shin. Volumetry conducted by a mathematical method showed the volume of right lower limb 16601 cm³ and of the left – 5442 cm³. Ultrasound duplex scanning

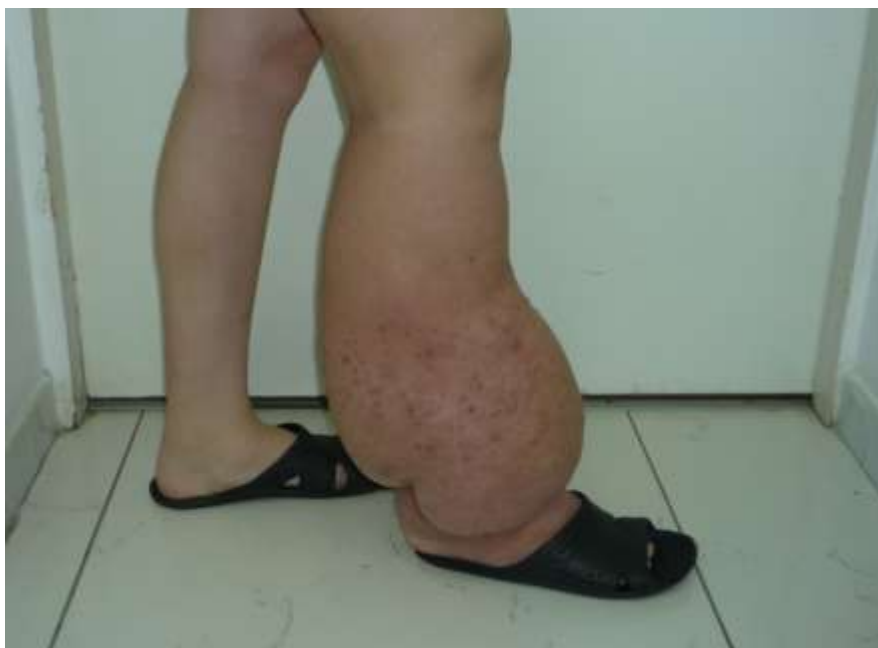

Fig. 1. View of lower limbs of a 33 year old female patient with IV stage primary lymphedema of the right lower limb before the operation

showed normal patency of the deep and superficial veins and consistency of their valvular apparatus. Signs of diffuse enhancement of echogenicity of the soft tissues of the limb with separate areas of reduced echogenicity were found. Multispiral computed tomogra-

phy of the lower limb showed thickening of skin and subcutaneous layer up to 2.5-3 mm and 56 mm, respectively, with a high degree of visualization, and also increase in their density to 13.2 HU (Fig. 2).

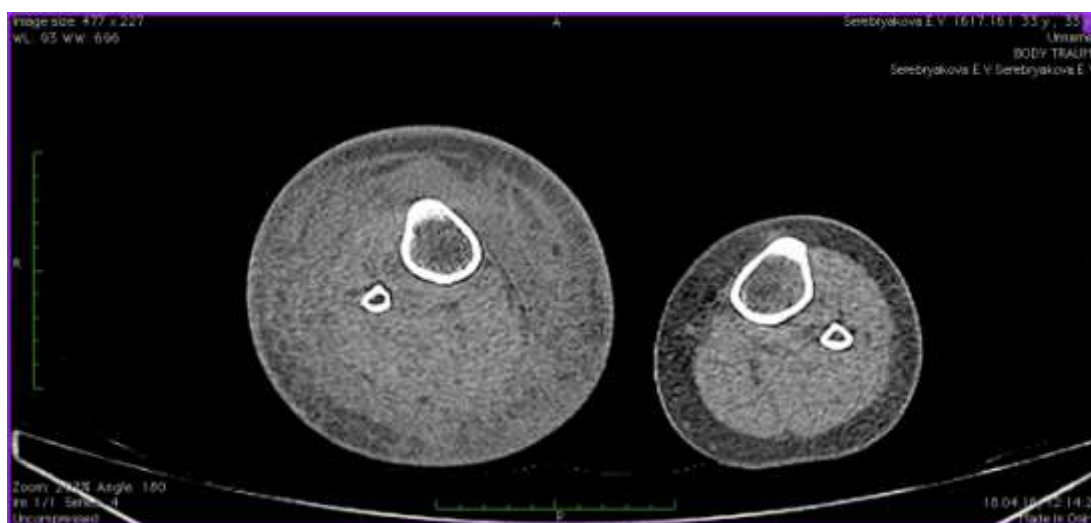


Fig. 2. Computed tomography of lower limbs of a 33 year old female patient with IV stage primary lymphedema of the right lower limb before the operation

In result of examination the following diagnosis was made: primary lymphedema of the right lower limb of IV stage. Preoperative conservative therapy included use of medicinal drugs of antibacterial, desaggregating, angiostrophic, desensitizing effect, sessions of plasmapheresis, of ultraviolet irradiation of blood, lymphotropic antibioticotherapy, magneto- and laser treatment.

After that under spinal anesthesia a surgery of modified dermalipofascioectomy by Karavanov II method was performed with use

of mono- and bipolar electrocoagulation. In the operation at the stage of elimination of fibrotically changed tissues Acculan 3Ti (GA 670) dermatome was used with control of thickness in the range 0.2-1.2 mm and of width in the range 8-78 mm (Fig. 3). Intraoperative loss of blood and lymph was 800 ml and was compensated for with crystalloid, colloid solutions and fresh frozen plasma in the volume of 600 ml. Active drainage of the region of the postoperative wound was conducted by Redon method within 10-12 days.

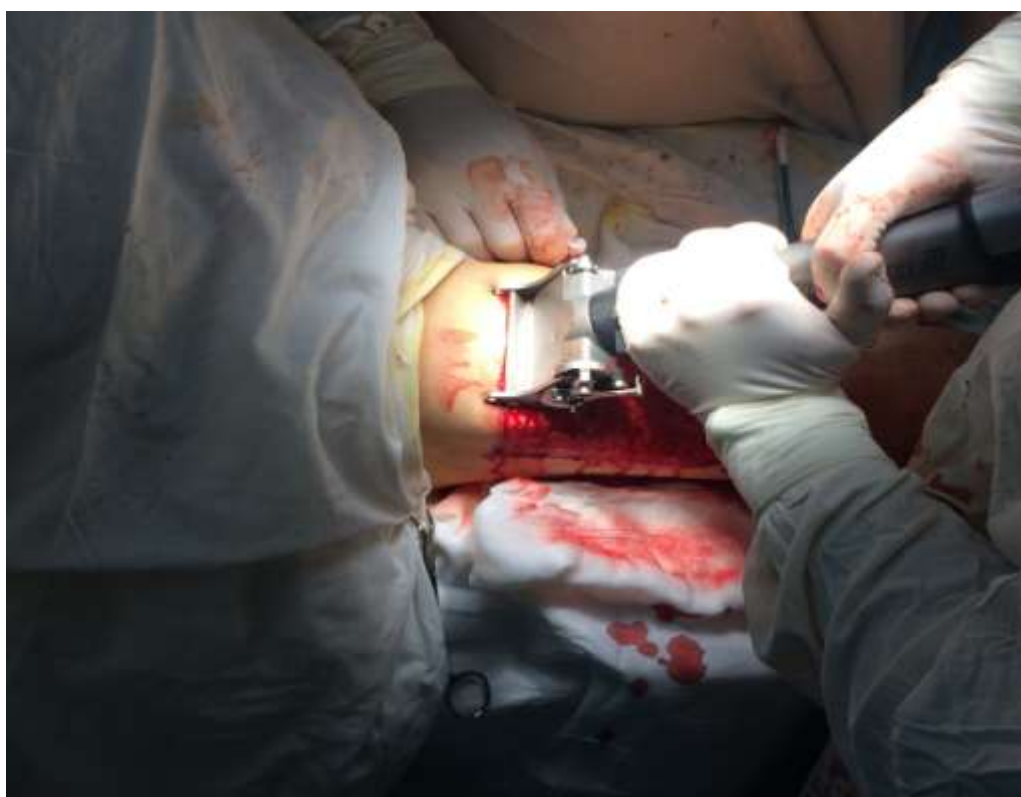

Fig. 3. Use of Acculan 3Ti (GA 670) dermatome in the operation of dermalipofascioectomy

Within the first three days of the postoperative period the condition of the patient was evaluated as moderately severe with phenomena of moderate general weakness, pain syndrome and low-graded temperature. After some time the condition improved, pain decreased, body temperature normalized. Anesthetic, antibacterial drugs, infusional drugs were used including crystalloid solutions and fresh frozen plasma, low

molecular weight heparin (Enoxaparin) 40 mg per day subcutaneously within 7 days, after that sulodexide (Vessel Due F) 600 MU per day intramuscularly for 10 days. Stitches were taken out stage-by-stage on the 12th-16th day. The wound healed mainly by the first intention except for the area 6 cm² in the lower third of the shin where marginal necrosis of skin was observed (Fig. 4).

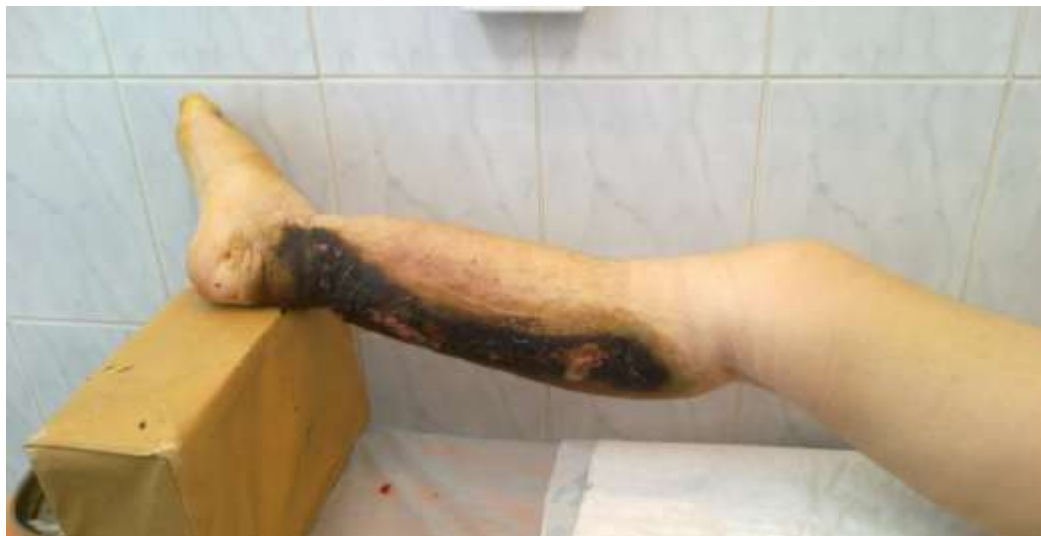

Fig. 4. Condition of the lower limb of the patient on the third day after the operation of dermalipofascioectomy

The patient was discharged on the 23^d day after the operation with the recommendations of supportive conservative treatment: wearing of the 3^d degree compression garments, protractive systemic multienzyme therapy (Wobenzym 3 tablets 3 times a day for 3 months). On examination 6 months later the condition of the patient was satisfactory. Reduction in the functional insufficiency of the affected limb and improvement of the quality of life were stated. The patient felt reduction in the heavy feeling in the leg and significant relief in walking. In volumetry, the volume of the right lower limb was 9477 cm³, and of the left – 5536 cm³. Parameters of computed tomography indicated reduction in the thickness of soft tissues of the shin to 26 mm with preservation of the density at the level of 36 HU.

Discussion

At present planned conservative medical measures play the leading role in treatment of patients with lymphatic edema [2,4]. The modern concept of these measures implies a complex use of pathogenetically justified physiotherapeutic, pharmacological and rehabilitation methods. Important preconditions of effectiveness of the conservative treatment are its prolonged and regular application at the initial stages of lymphedema.

Unfortunately, one must state that because of the insufficient attention of doctors and low adherence of patients to treatment these conditions are often ignored. The given case shows that appearance of the disease at the early age, absence of adequate observation and of permanent conservative treatment led to the advanced form of the primary lymphedema of IV stage with the clinical signs of dense edema and disfiguring deformation of the right lower limb.

Among different methods used in examination of patients with lymphedema, of decisive significance is computed tomography which permits to visualize the condition of soft tissues in every part of limb, and to quantitatively determine their size and density [3,11]. The parameter of density given in Hounsfield units – HU – reflects the extent of fibrous alterations in skin and subcutaneous tissue, and permits to determine the stage of lymphedema with a large extent of reliability. The normal range of this parameter is 150-125 HU. The parameter decreases with increase in the density of tissues. The value 50 HU and below indicates significant diffuse connective-tissue changes in the soft tissues characteristic of IV stage of lymphedema.

In our observation computed tomography performed in a routine examination, per-

mitted to identify the most severe, IV, stage of the disease characterized by a specific appearance of the limb owing to which the disease was earlier called “elephantiasis”. According to the common opinion of specialists, the most optimal method of treatment in this situation is staged surgical interventions of resection type [1,6,12]. In our opinion, among the numerous methods proposed by the domestic and foreign scientists the best one is Karavanov II method. One-stage double-flap dissection and excision of skin, of fibrotically changed subcutaneous tissue and fascia permits not only to eliminate the affected tissue and significantly reduce the volume of the limb, but also to establish communication between superficial and deep lymphatic vessels over a large area and to improve drainage of lymph. In contrast to the original method, we do not apply arterial tourniquet for deprivation of the limb of blood and thus exclude the ischemic factor. Successive use of mono- and bipolar electrocoagulation significantly reduces loss of blood and lymph. Besides, long-term active draining permits to avoid multiple incisions on the sutured flaps which significantly reduces the number of marginal necroses of skin.

According to our observations, a sufficiently effective means for prevention and stimulation of healing of necrotized areas is use of sulodexide possessing fibrinolytic, antiadhesive and angioprotective effects. In the early postoperative period it is administered parenterally with further transition to

peroral intake.

The stage of surgical treatment is followed by complex conservative treatment. Along with compression therapy, remedial gymnastics, physiotherapeutic measures it is reasonable to use drugs of systemic enzyme therapy. These drugs act on many pathogenetic factors of secondary lymphedema. Multienzymes break down extravasally released plasma proteins and thus decrease colloid-osmotic pressure and edema of the interstitium, promote reduction in the permeability of the endothelium, in migration of the proinflammatory cytokines and provide antiedematous, anti-inflammatory, fibrinolytic and immunomodulating effects.

Conclusion

Thus, treatment of patients with extremely pronounced forms of the primary lymphedema of limbs, although seeming prospectless, is a complicated but a really feasible task. Along with different methods used in determination of the stage of the disease and selection of the optimal therapeutic strategy, of special significance is computed tomography. Planned complex conservative treatment is indicated at all stages of the disease. In patients with IV stage of the primary lymphedema indicated and effective are resection operations. Optimization of the technique of dermalipofascioectomy with use of *shave therapy* apparatus is directed at reduction of the injury rate of surgical interventions and at prevention of postoperative complications.

Литература

1. Горшков С.З., Мусалатов Х.А. Слоновость конечностей и наружных половых органов. М.: Медицина, 2008.
2. Поташов Л.В., Бубнова Н.А., Орлов Р.С., и др. Хирургическая лимфология. СПб.: СПбГЭТУ «ЛЭТИ», 2002.
3. Foldi M., Folfi E., Kubrik S. Textbook of Lymphology: for Physicians and Lymphedema Therapists. Hardcover, 2007.
4. Doller W. Possibilities of surgical therapy of lymphedema // Wien Med. Wochenschr. 2013. Vol. 163, №7-8. P. 177-183.
5. Koshima I., Narushima M., Yamamoto Y., et al. Recent advancement on surgical treatments for lymphedema // Ann. Vasc. Dis. 2012. Vol. 5, №4. P. 409-415. doi:10.3400/avd.ra.12.00080
6. Lee B.B., Kim Y.W., Kim D.I., et al. Supplemental surgical treatment to end stage (stage IV-V) of chronic lymphedema // Int. Angiol. 2008. Vol. 27, №5. P. 389-395.
7. Богачев В.Ю., Богданец Л.И., Золотухин И.А., и др. Послойная дерматолипэктомия (*shave therapy*) при длительно незаживающих венозных трофических язвах // Ангиология и сосудистая хирургия. 2003. Т. 9, №4. С. 65-70.

8. Hermanns H.J., Gallenkemper G., Kanya S., et al. Die Shave-Therapie im Konzept der operativen Behandlung des therapieresistenten Ulcus cruris venosum // Aktuelle L. Phlebologie. 2005. Vol. 34, №4. P. 209-215.
9. Сушков С.А., Кухтенков П.А., Хмельников В.Я. Первый опыт применения послойной дерматолипэктомии (shave-therapy) при лечении хронической венозной недостаточности // Новости хирургии. 2007. Т. 15, №1. С. 53-57.
10. Каторкин С.Е., Мельников М.А., Кравцов П.Ф., и др. Эффективность применения послойной дерматолипэктомии (Shave Therapy) в комплексном лечении пациентов с венозными трофическими язвами нижних конечностей // Новости хирургии. 2016. Т. 24, №3. С. 255-264. doi:10.18484/2305-0047.2016.3.255
11. Мышенцев П.Н., Жуков Б.Н., Каторкин С.Е., и др. Значение компьютерной томографии в оценке стадии лимфедемы нижних конечностей // Новости хирургии. 2011. Т. 19, №5. С. 74-77.
12. Мышенцев П.Н., Каторкин С.Е. Тактика лечения при вторичной лимфедеме нижних конечностей // Новости хирургии. 2014. Т. 22, №2. С. 239-243.
- 163(7-8):177-83.
5. Koshima I, Narushima M, Yamamoto Y, et al. Recent advancement on surgical treatments for lymphedema. *Ann Vasc Dis.* 2012;5(4):409-15. doi:10.3400/avd.ra.12.00080
6. Lee BB, Kim YW, Kim DI, et al. Supplemental surgical treatment to end stage (stage IV-V) of chronic lymphedema. *Int Angiol.* 2008;27(5):389-95.
7. Bogachev VJu, Bogdanec LI, Zolotuhin IA, et al. Poslojnaja dermatolipjektomija (shave-therapy) pri dlitel'no nezazhivajushhijh venoznyh troficheskijh jazvah. *Angiologija i sosudistaja hirurgija.* 2003;9(4):65-70. (In Russ).
8. Hermanns HJ, Gallenkemper G, Kanya S, et al. Die Shave-Therapie im Konzept der operativen Behandlung des therapieresistenten Ulcus cruris venosum. *Aktuelle L. Phlebologie.* 2005; 34(4):209-15. (In German).
9. Sushkov SA, Kuhtenkov PA, Hmel'nikov VJA. Pervyj opyt primenenija poslojnoj dermatolipjektomii (shave-therapy) pri lechenii hronicheskoy venoznoj nedostatochnosti. *Novosti hirurgii.* 2007;15(1):53-7. (In Russ).
10. Katorkin SE, Mel'nikov MA, Kravcov PF, et al. Jefferktivnost' primenenija poslojnoj dermatolipjektomii (Shave Therapy) v kompleksnom lechenii pacientov s venoznymi troficheskimi jazvami nizhnijh konechnostej. *Novosti hirurgii.* 2016;24(3):255-64. (In Russ). doi:10.18484/2305-0047.2016.3.255
11. Myshencev PN, Zhukov BN, Katorkin SE, et al. Znachenie komp'juternoj tomografii v ocenke stadii limfedemy nizhnijh konechnostej. *Novosti hirurgii.* 2011;19(5):74-7. (In Russ).
12. Myshencev PN, Katorkin SE. Taktika lechenija pri vtorighnoj limfedeme nizhnijh konechnostej. *Novosti hirurgii.* 2014;22(2): 239-43. (In Russ).

References

1. Gorshkov SZ, MusalatoV HA. *Slonovost' konechnostej i naruzhnyh polovyh organov.* Moscow: Medicina; 2008. (In Russ).
2. Potashov LV, Bubnova NA, Orlov RS, et al. *Hirurgicheskaja limfologija.* Saint-Petersburg: SPbGJeTU «LJeTI»; 2002. (In Russ).
3. Foldi M, Folfi E, Kubrik S. *Textbook of Lymphology: for Physicians and. Lymphedema Therapists.* Hardcover; 2007.
4. Doller W. Possibilities of surgical therapy of lymphedema. *Wien Med Wochenschr.* 2013;

Дополнительная информация [Additional Info]

Источник финансирования. Бюджет клиники госпитальной хирургии Самарского государственного медицинского университета. [Financial support. Budget of Hospital surgery clinic of Samara State Medical University.]

Конфликт интересов. Авторы декларируют отсутствие явных и потенциальных конфликтов интересов, о которых необходимо сообщить, в связи с публикацией данной статьи. [Conflict of interests. The authors declare no actual and potential conflict of interests which should be stated in connection with publication of the article.]

Участие авторов. Каторкин С.Е. – концепция и дизайн исследования, редактирование. Мышенцев П.Н., Личман Л.А. – сбор и обработка материала, написание текста. [Participation of authors. S.E. Katorkin – con-

cept and design of the study, editing. P.N. Myshencev, L.A. Lichman – acquisition and processing of the material, writing the text.]

Информация об авторах [Authors Info]

Каторкин Сергей Евгеньевич – к.м.н., доцент, заведующий кафедрой госпитальной хирургии ФГБОУ ВО Самарский государственный медицинский университет, Самара, Россия. [Sergey E. Katorkin – MD, PhD, Associate Professor, Head of the Department of Hospital Surgery, Samara State Medical University, Samara, Russia.] SPIN 7259-3894, ORCID ID 0000-0001-7473-6692, Researcher ID A-7606-2016.

Мышенцев Павел Николаевич – к.м.н., доцент, заведующий учебной частью кафедры госпитальной хирургии ФГБОУ ВО Самарский государственный медицинский университет, Самара, Россия. [Pavel N. Myshencev – MD, PhD, Associate Professor of the Department of Hospital Surgery, Samara State Medical University, Samara, Russia.] SPIN 9730-8813, ORCID ID 0000-0001-7564-8168, Researcher ID C-8509-2018.

***Личман Леонид Андреевич** – врач хирург хирургического отделения клиники госпитальной хирургии ФГБОУ ВО Самарский государственный медицинский университет, Самара, Россия. [Leonid A. Lichman – Doctor Surgeon of the Surgical Department of the Department of Hospital Surgery, Samara State Medical University, Samara, Russia.] SPIN 2380-0840, ORCID ID 0000-0002-4817-3360, Researcher ID C-3376-2018. E-mail: lichman163@gmail.com

Цитировать: Мышенцев П.Н., Каторкин С.Е., Личман Л.А. Случай успешного оперативного лечения пациента с лимфедемой нижних конечностей // Российский медико-биологический вестник имени академика И.П. Павлова. 2018. Т. 26, №2. С. 288-295. doi: 10.23888/PAVLOVJ2018262288-295.

To cite this article: Myshencev PN, Katorkin SE, Lichman LA. A case of successful surgical treatment of a patient with lymphedema of lower limbs. *I.P. Pavlov Medical Biological Herald*. 2018;26(2):288-95. doi: 10.23888/PAVLOVJ2018262288-295.

Поступила/Received: 25.06.2017
Принята в печать/Accepted: 31.05.2018