



## RUSSIA'S FIRST POEM IN THE TREATMENT OF ACHALASIA IN CHILDREN

© M.P. Korolev<sup>1</sup>, L.E. Fedotov<sup>2</sup>, A.L. Ogloblin<sup>1</sup>, A.L. Kopyakov<sup>1</sup>, Sh.D. Mamedov<sup>2</sup>, B.L. Fedotov<sup>2</sup>, D.G. Baranov<sup>1</sup>

<sup>1</sup>St Petersburg State Pediatric Medical University, Ministry of Healthcare of the Russian Federation, Russia;

<sup>2</sup>Saint Petersburg Mariinskiy Hospital, Saint Petersburg, Russia

For citation: *Pediatrician (St Petersburg)*, 2017;8(2):94-98

Received: 02.02.2017

Accepted: 07.03.2017

The article describes various methods of treatment of achalasia, for example, endoscopic balloon pneumatic dilation that extends the lower esophageal sphincter, injection of botulinum toxin that decreases cardia tone, minimally invasive endoscopic methods in combination with medicinal therapy, and surgical treatment of patients at the fourth stage of the disease that promotes good or satisfactory clinical results in 98.2% of patients. The present study also introduces an optimal algorithm for the examination of patients with suspected achalasiocardia. X-ray diagnostics and endoscopic examination were used to verify the diagnosis. All these methods ensure timely and correct diagnosis, determining also the stage of the disease development. Stage-wise diagnostics in Russia are mostly based on the classification suggested by B.V. Petrovsky in 1962. This classification is founded upon X-ray examination of the esophagus due to its simplicity and availability. The article also presents a completely novel approach for the treatment of achalasiocardia in Russia, that is, peroral endoscopic myotomy (POEM). This method of endoscopic operation has been used in our clinic since 2014 for adult patients, and in 2016, it has been for the first time in Russia performed on a child. A clinical example of achalasiocardia in a child is presented as well as diagnostic methods, medicinal treatment, and the use of balloon pneumatic dilation resulting in a recurrence that subsequently demanded peroral endoscopic myotomy. This minimally invasive endoscopic operation nowadays is highly effective and prospective for the treatment of achalasiocardia in both adults and children.

**Keywords:** achalasia in children; balloon dilatation; peroral endoscopic myotomy (POEM).

## ПЕРВАЯ В РОССИИ ПЕРОРАЛЬНАЯ ЭНДОСКОПИЧЕСКАЯ МИОТОМИЯ ПРИ ЛЕЧЕНИИ АХАЛАЗИИ КАРДИИ У РЕБЕНКА

© М.П. Королев<sup>1</sup>, Л.Е. Федотов<sup>2</sup>, А.Л. Оглоблин<sup>1</sup>, А.Л. Копяков<sup>1</sup>, Ш.Д. Мамедов<sup>2</sup>, Б.Л. Федотов<sup>2</sup>, Д.Г. Баранов<sup>1</sup>

<sup>1</sup>ФГБОУ ВО «Санкт-Петербургский государственный педиатрический медицинский университет» Минздрава России;

<sup>2</sup>СПб ГБУЗ «Городская Мариинская больница», Санкт-Петербург

Для цитирования: *Педиатр.* – 2017. – Т. 8. – № 2. – С. 94–98. doi: 10.17816/PED8294-98

Поступила в редакцию: 02.02.2017

Принята к печати: 07.03.2017

В статье рассмотрены различные методы лечения ахалазии кардии — эндоскопическая баллонная дилатация, направленная на расширение нижнего пищеводного сфинктера, введение ботулинического токсина, что способствует снижению тонуса кардии, малоинвазивные эндоскопические методики в сочетании с медикаментозной терапией, а также хирургическое лечение больных с IV стадией заболевания, которое позволяет получить хороший и удовлетворительный клинический результат лечения у 98,2 % больных. В данной статье также представлен оптимальный алгоритм обследования больных с подозрением на ахалазию кардии. Для установления диагноза использовали рентгенологический метод исследования, эндоскопический метод исследования. Все используемые методы позволяют своевременно и правильно установить диагноз и стадию развития заболевания. При стадировании заболевания в России пользуются преимущественно классификацией, предложенной Б.В. Петровским в 1962 г., основанной на рентгенологическом исследовании пищевода, в силу ее доступности и простоты интерпретации полученных результатов. Также в статье представлен совершенно новый в Россий-

ской Федерации эндоскопический метод лечения ахалазии кардии — пероральная эндоскопическая миотомия (ПОЕМ, *peroral esophageal myotomy*). В нашей клинике данный вид эндоскопической операции выполняется с 2014 г. взрослым и впервые в России в 2016 г. проведен ребенку. Описан клинический пример ахалазии кардии у ребенка, методы диагностики, медикаментозное лечение и лечение баллонной дилатацией, после чего у ребенка был рецидив заболевания. В дальнейшем ему выполнена пероральная эндоскопическая миотомия. Эта на сегодняшний день перспективная, эффективная, малоинвазивная эндоскопическая операция, в лечении ахалазии кардии как у взрослых, так и у детей.

**Ключевые слова:** ахалазия кардии у ребенка; баллонная дилатация; пероральная эндоскопическая миотомия (ПОЭМ).

## INTRODUCTION

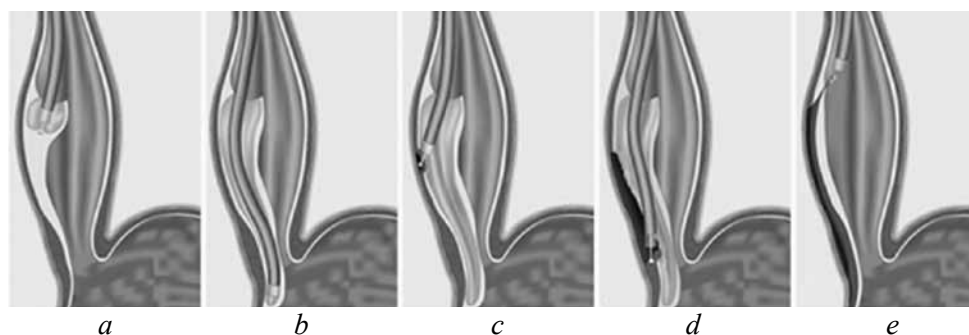
Achalasia is a congenital or acquired disorder of gastric motility, which is manifested by a blockage of food passage into the stomach as a result of an inadequate reflex opening of the lower esophageal sphincter during swallowing and an irregular peristalsis of overlying sections of the esophageal tube [1]. Clinically, this disorder is manifested by progressive dysphagia, regurgitation, and weight loss and can lead to the development of persistent organic stricture with decompensated expansion and S-shaped deformity of the esophageal lumen. Such an advanced stage of the disease not only significantly worsens the quality of life of patients but also leads to the need for surgical treatment. The etiology of this disease is unclear because of multidirectional and ambiguous approaches to its treatment. In Russia, the classification of achalasia that is most often used is that proposed by B. V. Petrovsky, which identifies four stages of the disease [2]. In its revision of 2011, the Chicago classification, which is globally common, distinguished three types of achalasia depending on the prevalence of certain motility disorders of the esophagus. Several methods exist for treating achalasia cardia. Drug therapy aims at reducing the tone of the lower esophageal sphincter using calcium channel inhibitors, nitrates, and myotropic antispasmodics. Drugs are used in combination with other methods of treatment. Endoscopic treatment includes injections of botulinum toxin and balloon dilatation of cardia. Surgical treatment includes E. Heller's surgery, which is performed using various kinds of fundoplication, and esophageal resection, which is performed at stage IV of the disease. However, the aforementioned treatment methods do not provide stable functional results [4, 5]. The development of intraluminal endoscopic surgery has inspired gastroenterologists and endoscopic surgeons to create a less-invasive but equally effective method for the treatment of achalasia cardia. For the first time, myotomy through the endoscope from submucosal access, which was essentially similar to E. Heller's surgery, was performed in an experiment by the Apollo group in 2007 as a part of the development of the concept of transluminal endoscopic surgery through natural openings in the human body [6]. The first clinical version of peroral endoscopic myotomy (POEM) in humans was developed and implemented on September 8, 2008 by H. Inoue.

After operating and carefully examining more than 200 patients, he proved the safety, efficacy, and good functional results of POEM in the treatment of achalasia [7]. The main advantage of POEM is the absence of risk of uncontrolled esophageal perforation, which can occur during balloon dilatation. In addition, this version of myotomy, in contrast to the E. Heller's surgery, can be performed at a greater length of the esophagus. POEM has demonstrated its relative safety with respect not only to the risk of infection but also to the violation of hemodynamics and respiratory and metabolic disorders. None of the myotomies were complicated by the development of such serious complications as mediastinitis or peritonitis [3]. Undoubtedly, such interventions should be performed with the use of modern technical equipments, with the availability of highly professional anesthesia services, and with careful postoperative monitoring of patients [8].

## MATERIALS AND METHODS

At the Department of General Surgery with the course of endoscopy of the Federal State Budgetary Educational Institution of Higher Education Saint Petersburg State Pediatric Medical University of the Ministry of Health of the Russian Federation, on the basis of Saint Petersburg public health facility City Mariinsky Hospital since 2014, POEM is performed on all patients diagnosed with achalasia of stages I-IV according to the classification of B. V. Petrovsky. Over this period, the technique was applied in 63 achalasia patients aged 18-91 years. In one of these patients, Heller's cardiomyotomy was performed in 1983; balloon dilation was previously performed in eight patients; in other patients, the diagnosis was established for the first time in their lives.

For performing POEM, endoscopes from Olympus (GIF1TQ 160) and Pentax (AG-299i) with a fixed distal transparent cap were used. For the supply of gas (CO<sub>2</sub>) through the endoscope channel, a UCRO Olympus CO<sub>2</sub> insufflator was used. After visually determining the increased tone of the esophagus at a distance of approximately 30-35 cm from upper incisors along the posterior wall, a solution of the preparation of the hydroxyethyl starch group — Tetraspan 10% (average molecular weight, 130,000 daltons) stained with indigo carmine to create a "cushion" — was injected into the submucosal



**Fig. 1.** Entry into the submucosal membrane of the esophagus (a); the formation of a submucosal channel (b); dissection of muscles of the esophagus, cardia, and stomach (c, d); suturing the entrance to the submucosal membrane of the esophagus using clips (e)

**Рис. 1.** Вход в подслизистый слой пищевода (a); формирование подслизистого канала (b); рассечение мышц пищевода, кардии и желудка (c, d); сшивание входа в подслизистый слой пищевода клипсами (e)

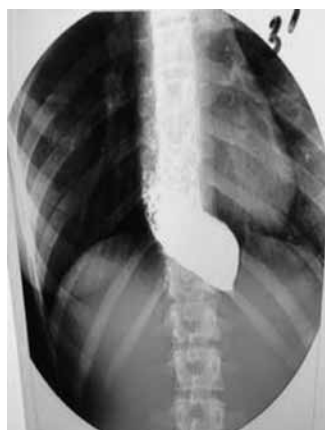layer. Using the cauterodyne triangle tip knife (or dual knife), the mucosa was then dissected for 1.5 cm, after which the endoscope was inserted into the submucosal layer of the organ and a channel started to form, which distally extended by 3.0-5.0 cm to the esophagogastric junction (43-45 cm from incisors). Then, 30-35 cm from the incisors, a portion of the circular muscle layer was dissected using a hook knife until longitudinal muscle fibers appeared along the entire submucosal channel. After the lower esophageal sphincter was dissected, the tunnel lumen extension was visually noted in the region of spasmodic segment of the esophagus. During the control examination, the apparatus freely passed through the esophagogastric junction. The mucosal defect, through which the apparatus was inserted into the submucosal membrane, was sutured using clips (Olympus HX-610-135L). The scheme of the surgery is shown in Fig. 1.

In December 16, 2016, for the first time in Russia in the clinic Federal State Budgetary Educational Institution of Higher Education Saint Petersburg State Pediatric Medical University of the Ministry of Health of the

Russian Federation, POEM was successfully performed in a child.

### CLINICAL EXAMPLE

Patient A, 16 years old, was admitted to the microsurgical department in December 13, 2016. It was known from anamnesis, that for the first time in February 2016, she noticed heaviness behind the sternum after a meal, periodic vomiting of food eaten the day before, cough at night, and weight loss; with a height of 158 cm and weight of 44 kg, her body mass index was 17.6; because of these observations, she sought medical help. EGDS was performed, which revealed the expansion of the esophageal lumen up to 6-7 cm, presence of residual liquid and solid food in the lumen of the organ, abundance of mucus, and closed cardia that was hardly traversed by the endoscope. Roentgenoscopy of the esophagus with contrast substance was performed (Fig. 2). According to results of anamnesis, clinics, and examinations, the following diagnosis was made: achalasia of stage III and dysphagia of three points. Conservative therapy, nitrates, calcium channel blockers, and manual therapy were prescribed, which showed a temporary effect. In September 2016, because of the resumption of complaints, she again sought medical help, and surgical treatment was recommended. All this time the patient was administered a liquid diet and Nutren enteral nutrition. In November 2016, the patient underwent an endoscopic balloon dilatation of the cardia using a 35 × 80 mm Olympus balloon, after which a slight positive effect was noted in the form of reduced regurgitation and cessation of coughing at night, and the patient began to eat grated food. In connection with the appearance of complaints regarding growing dysphagia, the patient was hospitalized again in the microsurgical department of the clinic. Considering the previous treatment and progression of the disease, it was decided to perform POEM. During the surgery on December 16,



**Fig. 2.** X-ray image of the esophagus prior to the surgery

**Рис. 2.** Рентгенограмма пищевода до операции

2016 and for 5 days afterward, ciprofloxacin and metronidazole were intravenously dripped at 200.0 mg per day. The postoperative period proceeded without complications; on the third day, the patient began to take liquid food. She was dismissed from the hospital on postoperative day 7. Four weeks after the surgery, a control X-ray examination of the esophagus with contrast agent (BaSO<sub>4</sub>) was performed (Fig. 3); the free flow of contrast agent through the esophagogastric junction into the stomach occurred without delay, and the appearance of a gastric air bubble was noted.

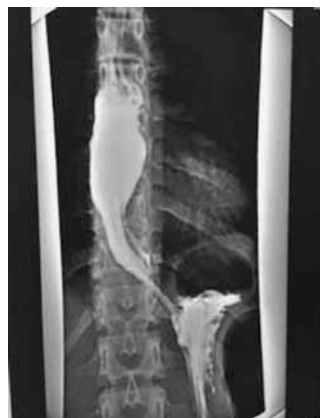Clinically, this patient indicated an improvement in well-being, cessation of coughing at night, and lack of dysphagia; currently, she eats solid and liquid food.

### CONCLUSION

Currently, POEM is the surgery of choice for the treatment of achalasia irrespective of the patient's age.

### REFERENCES

1. Денисов И.Н. Справочник-путеводитель практикующего врача. 2000 болезней от А до Я / И.Н. Денисов, Ю.Л. Шевченко. – М.: ГЭОТАР-Медиа, 2008. [Denisov IN. Spravochnik-putevoditel' praktikuyushchego vracha. 2000 bolezney ot A do Ya. Guide the practitioner. 2000 Diseases A to Z. Moscow: GEOTAR-Media; 2008. (In Russ.)]
2. Петровский Б.В. Кардиоспазм и его хирургическое значение. Труды 27-го Всесоюзного съезда хирургов. – М., 1962. – С. 162–173. [Petrovskiy BV. Kardiospazm i ego khirurgicheskoe znachenie. Trudy 27 Vsesoyuznogo s'ezda khirurgov. Moscow; 1962. P. 162-173. (In Russ.)]
3. Федоров Е.Д., Иноуе Х., Шаповальянц С.Г. и др. Пероральная эндоскопическая миотомия при ахалазии кардии – первый отечественный опыт. XVI Московский международный конгресс по эндоскопической хирургии: Сборник тезисов / Под ред. проф. Ю.И. Галлингера. – М., 2012. – С. 215–217. [Fedorov ED, Inoue Kh, Shapoval'yants SG, et al. Peroral'naya endoskopicheskaya miotomiya pri akhalazii kardii – pervyy otechestvennyy opyt. XVI Moskovskiy mezhdunarodnyy kongress po endoskopicheskoy khirurgii. Sbornik tezisov. Ed by prof. Yu.I. Gallinger. (conference proceedings) Moscow; 2012. P. 215-217. (In Russ.)]
4. Campos GM, Vittinghoff E, Rabl C, et al. Endoscopic and surgical treatments for achalasia. A systematic review and meta-analysis. *Ann Surg.* 2009;249:45-57.
5. Csendes A, Braghetto I, Burdiles P, et al. Very late results of esophagomyotomy for patients with achalasia: clinical, endoscopic, histologic, manometric, and acid reflux studies in 67 patients for a mean followup of 190 months. *Ann Surg.* 2006;243:196-203.
6. Inoue H, Minami H, Kobayashi Y, et al. Peroral endoscopic myotomy (POEM) for esophageal achalasia. *Endoscopy.* 2010;42:265-271.
7. Pasricha PJ, Hawari R, Ahmed I, et al. Submucosal endoscopic esophageal myotomy: a novel experimental approach for the treatment of achalasia. *Endoscopy.* 2007;39:761-764.
8. Pehlivanov N, Pasricha PJ. Achalasia: botox, dilatation or laparoscopic surgery in 2006. *Neurogastroenterol Motil.* 2006;18:799-804.



**Fig. 3. X-ray image of the esophagus 1 month after the surgery**

**Рис. 3. Рентгенограмма пищевода через месяц после операции**

#### ◆ Information about the authors

Mikhail P. Korolev – PhD, Professor, Chief, Department of General Surgery with the Course of Endoscopy. St Petersburg State Pediatric Medical University, Ministry of Healthcare of the Russian Federation, Saint Petersburg, Russia. E-mail: Korolevmp@yandex.ru.

#### ◆ Информация об авторах

Королев Михаил Павлович – д-р мед. наук, профессор, кафедра общей хирургии с курсом эндоскопии. ФГБОУ ВО «Санкт-Петербургский государственный педиатрический медицинский университет» Минздрава России, Санкт-Петербург. E-mail: Korolevmp@yandex.ru.

## ◆ Information about the authors

*Leonid E. Fedotov* — PhD, Professor, Department of General Surgery with the Course of Endoscopy. Saint Petersburg Mariinsky Hospital, Saint Petersburg, Russia. E-mail: Fedotov-Le@yandex.ru.

*Alexandr L. Ogloblin* — Associate professor, Ph.D, Department of General Surgery with the Course of Endoscopy. St Petersburg State Pediatric Medical University, Ministry of Healthcare of the Russian Federation, Saint Petersburg, Russia. E-mail: ogloblindoka@mail.ru.

*Alexander L. Kopyakov* — Associate professor, Department of Pediatric Surgery. St Petersburg State Pediatric Medical University, Ministry of Healthcare of the Russian Federation, Saint Petersburg, Russia. E-mail: Kopyakov@yandex.ru.

*Shokhrat D. Mamedov* — Assistant Professor, Department of General Surgery with the Course of Endoscopy. Saint Petersburg Mariinsky Hospital, Saint Petersburg, Russia. E-mail: Shohrat.mamedov1987@gmail.com.

*Boris L. Fedotov* — Assistant Professor, Department of General Surgery with the Course of Endoscopy. Saint Petersburg Mariinsky Hospital, Saint Petersburg, Russia. E-mail: fedotov-bl@mail.ru.

*Dmitriy G. Baranov* — Associate professor, Department of Pediatric Surgery. St Petersburg State Pediatric Medical University, Ministry of Healthcare of the Russian Federation, Saint Petersburg, Russia. E-mail: BaranovDG@mail.ru.

## ◆ Информация об авторах

*Леонид Евгеньевич Федотов* — д-р мед. наук, профессор, кафедра общей хирургии с курсом эндоскопии. СПб ГБУЗ «Городская Мариинская больница», Санкт-Петербург. E-mail: Fedotov-Le@yandex.ru.

*Александр Леонидович Оглоблин* — канд. мед. наук, доцент, кафедра общей хирургии с курсом эндоскопии. ФГБОУ ВО «Санкт-Петербургский государственный педиатрический медицинский университет» Минздрава России, Санкт-Петербург. E-mail: ogloblindoka@mail.ru.

*Александр Леонидович Копяков* — канд. мед. наук, ассистент кафедры детской хирургии. ФГБОУ ВО «Санкт-Петербургский государственный педиатрический медицинский университет» Минздрава России, Санкт-Петербург. E-mail: Kopyakov@yandex.ru.

*Шохрат Довлатович Мамедов* — ассистент, кафедра общей хирургии с курсом эндоскопии. СПб ГБУЗ «Городская Мариинская больница», Санкт-Петербург. E-mail: Shohrat.mamedov1987@gmail.com.

*Борис Леонидович Федотов* — ассистент, кафедра общей хирургии с курсом эндоскопии. СПб ГБУЗ «Городская Мариинская больница», Санкт-Петербург. E-mail: fedotov-bl@mail.ru.

*Дмитрий Геннадьевич Баранов* — кафедра детской хирургии. ФГБОУ ВО «Санкт-Петербургский государственный педиатрический медицинский университет» Минздрава России, Санкт-Петербург. E-mail: BaranovDG@mail.ru.