

# ATROPHIC NON-UNION WITH SEVERE OSTEOLYSIS OF THE RADIUS IN A HEALTHY CHILD: SUCCESSFUL RESCUE SURGERY. MANAGEMENT WITH FIBULAR ALLOGRAFT AND AUTOGRAFT GROWTH FACTORS IN A PAEDIATRIC PATIENT

© *D. Priano*<sup>1</sup>, *M. D'Errico*<sup>1</sup>, *L. Peretto*<sup>2</sup>, *A. Memeo*<sup>2</sup>

<sup>1</sup> University of Milan, Milano, Italy;

<sup>2</sup> G. Pini Institute, Milano, Italy

■ For citation: Priano D, D'Errico M, Peretto L, Memeo A. Atrophic non-union with severe osteolysis of the radius in a healthy child: Successful rescue surgery. Management with fibular allograft and autograft growth factors in a paediatric patient. *Pediatric Traumatology, Orthopaedics and Reconstructive Surgery*. 2020;8(4):461-466. <https://doi.org/10.17816/PTORS33929>

Received: 27.04.2020

Revised: 09.11.2020

Accepted: 07.12.2020

**Background.** Forearm fractures are the most frequent fractures in children and adolescents and they are more common in males than in females. In the last 20 years the increase of surgical indications have resulted in more complications, among them the non-unions, considered extremely rare and severe in children, have increased in incidence. We report a successful treatment of misdiagnosed forearm atrophic non-union with severe osteolysis using fibula allograft and autograft growth factors in a previously healthy 4-year-old child.

**Clinical case.** A 4 year-old boy presented to our hospital with massive bone loss and a negative bone biopsy for Gorham-Stout Syndrome, he also showed reactive bone tissue with abnormal vascularity, necrotic osteocartilaginous fragments and giant mononucleated cells. Other lab tests did not show any modifications, so all the causes of paediatric osteolysis were ruled out. He had already undergone a few surgeries on that fracture and we performed others before achieving a good result, obtained with an autologous fibula graft with medullary growth factors stabilized with Kirschner wire. At the follow up 28 months later, the patient showed total consolidation of the initial area of non-union, no neurovascular deficit and no joint deficiency.

**Discussion.** Non-union in paediatric patients is rare and therefore difficult to treat and diagnose. Since all of our tests ruled out the main causes of paediatric non-union, we managed the case with strategies usually applied to adult patients, carefully respecting the growth plates.

**Conclusion.** Although this is a single-case report, it underlines the importance of early diagnosis, the difficulty to rule out some pediatric causes of bone loss and the complications of a wrong diagnosis/treatment. It also shows that the use of allograft bone and autograft growth factors in a pediatric patient, who has undergone multiple surgeries, can lead to excellent results

**Keywords:** non-union; paediatric; fracture; clinical case; radius.

## АТРОФИЧЕСКОЕ НЕСРАЩЕНИЕ НА ФОНЕ ТЯЖЕЛОГО ОСТЕОЛИЗА ЛУЧЕВОЙ КОСТИ У ЗДОРОВОГО РЕБЕНКА: УСПЕШНАЯ ЭКСТРЕННАЯ ОПЕРАЦИЯ. ЛЕЧЕНИЕ С ПРИМЕНЕНИЕМ АЛЛОТРАНСПЛАНТАТА МАЛОБЕРЦОВОЙ КОСТИ И АУТОЛОГИЧНЫХ ФАКТОРОВ РОСТА У ДЕТЕЙ

© *Д. Приано*<sup>1</sup>, *М. Д'Эррико*<sup>1</sup>, *Л. Перетто*<sup>2</sup>, *А. Мемео*<sup>2</sup>

<sup>1</sup> Миланский университет, Милан, Италия;

<sup>2</sup> Институт Дж. Пини, Милан, Италия

■ Для цитирования: Приано Д., Д'Эррико М., Перетто Л., Мемео А. Атрофическое несращение на фоне тяжелого остеолита лучевой кости у здорового ребенка: успешная экстренная операция. Лечение с применением аллотрансплантата малоберцовой кости и аутологичных факторов роста у детей // Ортопедия, травматология и восстановительная хирургия детского возраста. – 2020. – Т. 8. – Вып. 4. – С. 461–466. <https://doi.org/10.17816/PTORS33929>

Поступила: 27.04.2020

Одобрена: 09.11.2020

Принята: 07.12.2020



Gorham-Stout Syndrome occurs in the form of osteolysis of a bone or a contiguous bone area close to the focus, without respecting the joint limits. It is a rare disease, of unknown aetiology, in which osteolysis begins through the proliferation of vascular structures originating in the bone tissue, thus causing the destruction of the bone matrix. This condition may present at any age, but is generally recognised in children and young adults [12]. Gorham-Stout Syndrome is a diagnosis of exclusion, and requires a combination of clinical, radiological, and histopathological findings to confirm the presence of the disease [13]. The radiographic presentation includes a radiolucent focus in the intramedullary or subcortical region of the bone involved, with slowly progressive atrophy, dissolution, fragmentation and the disappearance of a portion of bone followed by tapering of the remaining bone tissue (“sucked candy appearance”), and atrophy of the surrounding soft tissues. Microscopically there is non-malignant vascular proliferation, with anastomosing, thin-walled lymphatics and/or capillaries surrounded by a fibrous stroma coursing between residual bony trabeculae [13]. In selected cases, the bone loss and non-union can be treated conservatively with or without physical therapy. More frequently, this disease requires surgical treatment (with different techniques) especially if oligotrophic, atrophic or septic nonunion, or if a progressive fracture malalignment is noted during the follow-up, in particular in children over 10 years old [6].

We report a successful treatment of forearm atrophic non-union with severe osteolysis using fibula allograft and autograft growth factors in a previously healthy 4-year-old child, with a follow-up of 5 years.

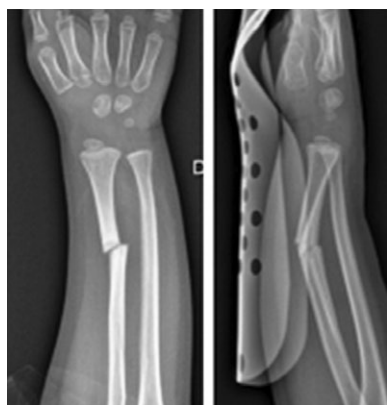## Clinical case

In December 2014 a 4 year-old boy presented to the emergency department after an accidental trauma to the right forearm showing deformity, pain and loss of function with no wound or neurovascular deficit. Diagnosis of distal diaphyseal fracture of the right radius was made. The fractured limb was immobilized with a cast. In January 2015 the fracture appeared in the process of consolidation and the cast was removed. One month later, after a new low-energy trauma, the patient arrived again in the emergency room with a diagnosis of recurrence fracture, but in that case he showed a displaced fracture of the distal third of the right radius (Fig. 1).

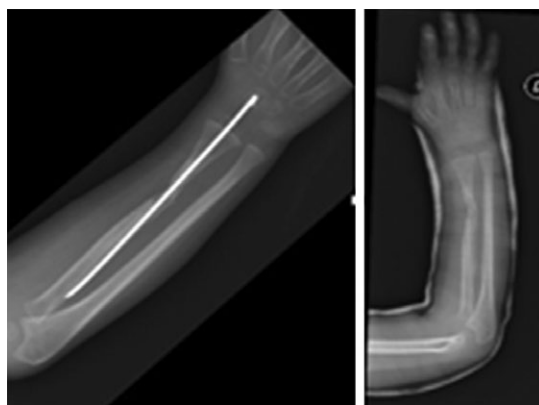
The fracture was treated in the operating room with Kirshner wires, but intra-operatively there was a complication with iatrogenic longitudinal fracture that was synthesized with cable cerclage. After about 3 months from the surgery, even if the x-rays showed slight signs of bone consolidation, the synthesis was removed and the forearm immobilized with a new cast (Fig. 2).

In June 2015 the bone near the fractures showed signs of local bone resorption, MRI was done and a rare disease expert was consulted due to a suspicion of Gorham-Stout Syndrome (Fig. 3).

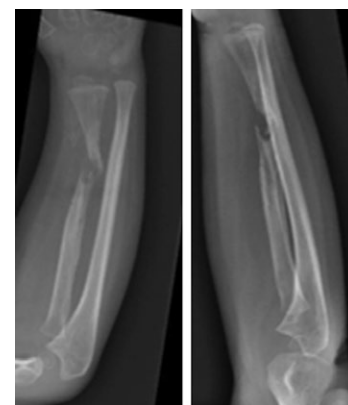
A bone biopsy was done and the results were negative for Gorham-Stout Syndrome according to two different Italian centres: it showed reactive bone tissue with abnormal vascularity, necrotic osteocartilaginous fragments, giant mononucleated cells. The patient presented to our hospital with these results and we decided to repeat the biopsy and the exclusion of Gorham-Stout Syndrome was



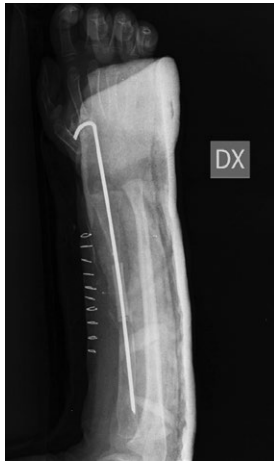**Fig. 1.** Re-fracture after 3 months



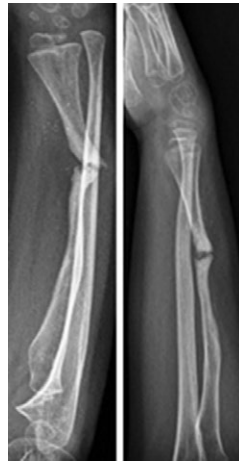**Fig. 2.** The x-rays showed slight signs of bone consolidation but the synthesis was removed and the forearm immobilized with a new cast



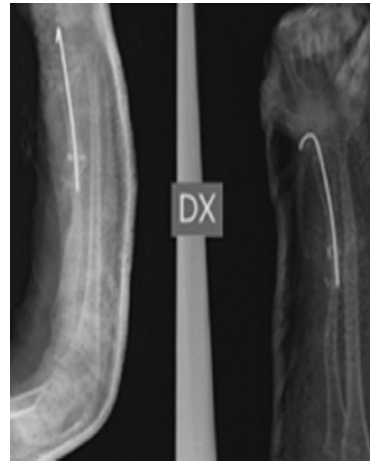
**Fig. 3.** The fractures showed signs of local bone resorption



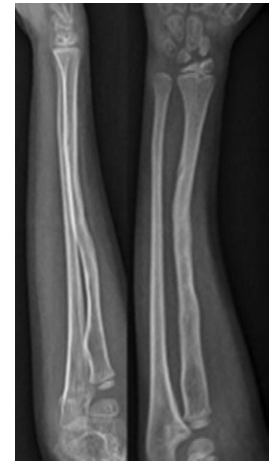**Fig. 4.** X-Ray pre and after tissue excision, autologous fibula with medullar growth factors stabilized with intramedullary Kirschner wire



**Fig. 5.** The x-rays showed no consolidation of the autologous fibula



**Fig. 6.** X-Ray post debridement of the focus of non-union and a bone transplant from cadaver with medullar growth factor, stabilized with a Kirschner wire



**Fig. 7.** X-Ray after Kirschner wire removal, at 28 months F.U.

confirmed. Afterward more laboratory tests were made and more specialist consulted to rule out all the causes that could lead to that massive osteolysis. Eleven months later from the last fractures, we performed a new surgery at the fracture site with tissue excision and implant of an autologous fibular allograft with medullar growth factors, stabilized with a Kirschner wire (Fig. 4).


After 10 days from hospital dimission, the patient returned to the emergency room with symptoms of fattening pain in the leg where the bone was taken. Tests confirmed a diagnosis of local hematoma caused by interosseous artery lesion. An emergency vascular surgery was thus performed to drain the hematoma and close the artery lesion. In February 2016, only 10 days after the last surgery, the

patient suffered from leg pain again. We decided to ask for advice to another institute that diagnosed a pseudo-aneurysm of the affected artery and consequently a new emergency vascular surgery was done. Meanwhile the x-rays showed no consolidation of the transplant in the forearm. After the failure of a new infiltration of medullar growth factors, in December 2016 a new surgery was performed with debridement of the focus of non-union and a bone transplant from cadaver with medullar growth factor, stabilized with a Kirschner wire (Fig. 5-6).

Clinically as well as according to the X-rays tests the patient began to show local improvement. Six months after the last transplant, the Kirschner wire was removed. At the follow-up 28 months later, the patient showed total consolidation of the initial area of non-union, no neurovascular deficit and no joint deficiency. The patient can be considered healed (Fig. 7-8).

## Discussion

We have presented the case of a patient from another hospital where he was initially treated conservatively with a cast and then with an open reduction and intramedullary fixation. Yeo J.H. et al. show that non-union rarely occurs in children under 8 years old. Since our patient is 4 year old, this case is particularly interesting, considering that non-union of closed distal radius fracture is an extremely rare occurrence and there are few studies among children in the literature [5]. We have no supporting evidence, but we could assert that treatments were probably not adequate in the first



**Fig. 8.** Clinical presentation at 28 months F.U.

place. In fact, according to De Raet et al. [3] the first cause of non-union is almost always iatrogenic due to the wrong mode of treatment, considering also that a healthy bone in children always heals also with conservative treatment and according to Pedrazzini et al., loss of reduction and malunion are common occurrence after insufficient closed reduction and cast immobilization [14]. At the time of the presentation at our hospital, the patient was already affected by a massive osteolysis of the radius, with a radiographic picture in agreement with a possible diagnosis of Gorham-stout Syndrome [12-13]. According to Choma N.D. et al., it can be very difficult to exclude this syndrome, so a second biopsy was performed, confirming further the exclusion of Gorham-stout Syndrome while endocrinological and genetic tests excluded the causes of secondary osteolysis as well [5, 12, 15]. As non-union in children has been universally accepted to be related to a pathologic condition of the bone or vascularity [16], we then proceeded to consider the case as an atrophic non-union and we treated it as such, although this disease is extremely rare and difficult to treat in paediatric age [6].

Bone atrophy and multiple surgeries create major problems for revision surgery. In fact, the reconstruction of a limb with severe bone loss and discrepancy in length requires precise planning [3, 5, 10, 17]. Kwa et al. in the first ever case reported had described a distal radius non-union treated exclusively by bone grafting and casting [8]. In our study growth factors combined with non-vascularized autograft bone were used to accelerate bone healing as it was documented in 2008 by Rampoldi et al. [18]. Moreover according to Christopher C. Bray et al. [19], autologous bone graft has a better osteo-inductive and osteo-conductive potential, and also autologous growth factors have a great osteo-inductive potential [19-20]. The reported union rate for traumatic large bone defect in non-vascularised fibula grafting is almost of 90% [20-21]. The disadvantage of fibula grafting is the donor site complications such as donor site infection, ankle instability, ankle valgus and rare tibia stress fracture [20-21]. A complication also occurred in our case: a pseudoaneurysm that required emergency surgical treatment. At the end of treatment, the donor site healed with full recovery of function. In consideration of the non-consolidation we did a second surgery, with an allograft stabilized with a Kirschner

wire. This treatment has allowed a healing of the area of injury and today the patient has fully recovered the function of the upper limb affected.

## Conclusion

Our case underline the importance of a early diagnosis and a correct early treatment to prevent more serious complications. Non-union in paediatric patients is rare and difficult to treat so we must prevent it, and where it is not possible, making an early diagnosis is necessary. It is also mandatory to exclude all causes of bone loss in the child, like the Gohram-Stout and the other idiopathic osteolysis. Finally, after years and multiple surgeries, we have achieved good results in patient satisfaction, range of motion and absence of pain. Although this is a single-case report, it suggests that the use of allograft bone and autograft growth factors in a pediatric patient who had undergone multiple surgeries can lead to excellent results. Attention must be paid to the complications of multiple surgeries, both at the main surgery site and at the donor site.

## Additional information

**Source of funding.** There is no funding source.

**Conflict of interests.** The authors declare that they have no conflict of interest.

**Ethical statement.** We have obtain the informed consent lawful representatives of our patient.

### Author contributions

*Daniele Priano* — conceptualized and designed the study, collected the data, contributed to the analysis and the interpretation of the data, drafted the initial manuscript reviewed, revised and approved the final manuscript as submitted.

*Mario D'Errico* — conceptualized and designed the study, collected the data, contributed to the analysis and the interpretation of the data, drafted the initial manuscript reviewed, revised and approved the final manuscript as submitted.

*Peretto Laura* — collected the data, drafted the initial manuscript, reviewed, revised and approved the final manuscript as submitted.

*Antonio Memeo* — conceptualized and designed the study, collected the data, contributed to the analysis and the interpretation of the data, drafted the initial manuscript, reviewed, revised and approved the final manuscript as submitted.

All authors made a significant contribution to the research and preparation of the article, read and approved the final version before publication.

## References

1. Song KS, Lee SW, Bae KC, et al. Primary nonunion of the distal radius fractures in healthy children. *J Pediatr Orthop B*. 2016;25(2):165-169. <https://doi.org/10.1097/BPB.0000000000000257>.
2. Saini P, Meena S, Shekhawat V, Kishanpuria TS. Nonunion of forearm fracture: A rare instance in a toddler. *Chin J Traumatol*. 2012;15(6):379-381. <https://doi.org/10.3760/cma.j.issn.1008-1275.2012.06.015>.
3. De Raet J, Kemnitz S, Verhaven E. Nonunion of a pediatric distal radial metaphyseal fracture following open reduction and internal fixation: A case report and review of the literature. *Eur J Trauma Emerg Surg*. 2008;34(2):173-176. <https://doi.org/10.1007/s00068-007-6168-8>.
4. Lyons RA, Delahunty AM, Kraus D, et al. Children's fractures: A population based study. *Inj Prev*. 1999;5(2):129-132. <https://doi.org/10.1136/ip.5.2.129>.
5. Yeo JH, Jung ST, Kim MC, Yang HY. Diaphyseal nonunion in children. *J Orthop Trauma*. 2018;32(2):e52-e58. <https://doi.org/10.1097/BOT.0000000000001029>.
6. Di Gennaro GL, Stilli S, Trisolino G. Post-traumatic forearm nonunion in healthy skeletally immature children: A report on 15 cases. *Injury*. 2017;48(3):724-730. <https://doi.org/10.1016/j.injury.2017.01.023>.
7. Sinikumpu JJ, Lautamo A, Pokka T, Serlo W. The increasing incidence of paediatric diaphyseal both-bone forearm fractures and their internal fixation during the last decade. *Injury*. 2012;43(3):362-366. <https://doi.org/10.1016/j.injury.2011.11.006>.
8. Kwa S, Tonkin MA. Nonunion of a distal radial fracture in a healthy child. *J Hand Surg*. 2016;22(2):175-177. [https://doi.org/10.1016/s0266-7681\(97\)80056-3](https://doi.org/10.1016/s0266-7681(97)80056-3).
9. Zura R, Kaste SC, Heffernan MJ, et al. Risk factors for nonunion of bone fracture in pediatric patients: An inception cohort study of 237,033 fractures. *Medicine (Baltimore)*. 2018;97(31):e11691. <https://doi.org/10.1097/MD.00000000000011691>.
10. Memeo A, Verdoni F, De Bartolomeo O, et al. A new way to treat forearm post-traumatic non-union in young patients with intramedullary nailing and plate-rich plasma. *Injury*. 2014;45(2):418-423. <https://doi.org/10.1016/j.injury.2013.09.021>.
11. Hardegger F, Simpson LA, Segmueller G. The syndrome of idiopathic osteolysis. Classification, review, and case report. *J Bone Joint Surg Br*. 1985;67(1):88-93. <https://doi.org/10.1302/0301-620X.67B1.3968152>.
12. El-Kouba G, de Araújo Santos R, Pilluski PC, et al. Gorham-Stout syndrome: Phantom bone disease. *Rev Bras Ortop*. 2010;45(6):618-622. [https://doi.org/10.1016/s2255-4971\(15\)30313-x](https://doi.org/10.1016/s2255-4971(15)30313-x).
13. Zacharia B, Chundarathil J, Meethal KC, et al. Gorham's disease of the fibula: A case report. *J Foot Ankle Surg*. 2009;48(3):347-352. <https://doi.org/10.1053/j.jfas.2009.01.004>.
14. Pedrazzini A, Bastia P, Bertoni N, et al. Distal radius nonunion after epiphyseal plate fracture in a 15 years old young rider. *Acta Biomed*. 2018;90(1-S):169-174. <https://doi.org/10.23750/abm.v90i1-S.7999>.
15. Choma ND, Biscotti CV, Bauer TW, et al. Gorham's syndrome: A case report and review of the literature. *Am J Med*. 1987;83(6):1151-1156. [https://doi.org/10.1016/0002-9343\(87\)90959-4](https://doi.org/10.1016/0002-9343(87)90959-4).
16. Cannata G, De Maio F, Mancini F, Ippolito E. Physeal fractures of the distal radius and ulna: Long-term prognosis. *J Orthop Trauma*. 2003;17(3):172-179; discussion 179-180. <https://doi.org/10.1097/00005131-200303000-00002>.
17. Zhen P, Lu H, Gao MX, et al. Successful management of atrophic nonunion of a severely osteoporotic femoral shaft in a child. *J Pediatr Orthop B*. 2012;21(6):592-595. <https://doi.org/10.1097/BPB.0b013e328352d546>.
18. Rampoldi M, Palombi D, Artale AM, Marsico A. Pseudartrosi dell'avambraccio: Sintesi interna rigida e innesto osseo autologo. *Giot*. 2008;34:77-85.
19. Bray CC, Walker CM, Spence DD. Orthobiologics in pediatric sports medicine. *Orthop Clin North Am*. 2017;48(3):333-342. <https://doi.org/10.1016/j.ocl.2017.03.006>.
20. Fioravanti C, Frustaci I, Armellini E, et al. Autologous blood preparations rich in platelets, fibrin and growth factors. *Oral Implantol (Rome)*. 2015;8(4):96-113. <https://doi.org/10.11138/orl/2015.8.4.096>.
21. Thevarajan K, Teo P. Free non-vascularized fibular graft for treatment of pediatric traumatic radial bone loss: A case report. *Malays Orthop J*. 2013;7(2):37-40. <https://doi.org/10.5704/MOJ.1307.003>.

## Information about the authors

**Daniele Priano** — MD, Resident at University of Milan, Istituto Ortopedico Gaetano Pini, Milan, Italy. <https://orcid.org/0000-0002-5123-4478>. E-mail: daniele.priano@gmail.com.

**Mario D'Errico\*** — MD, Resident at University of Milan, Milan, Italy. <https://orcid.org/0000-0003-4328-5344>. E-mail: marioderrico@gmail.com.

**Laura Peretto** — MD, Orthopaedic Surgeon, Department of Pediatric Orthopedic Surgery, Istituto Ortopedico Gaetano Pini, Milan, Italy. <https://orcid.org/0000-0001-5664-3687>. E-mail: laura.peretto@gmail.com.

**Antonio Memeo** — MD, Orthopaedic Surgeon, Chief of Department of Pediatric Orthopedic Surgery, Istituto Ortopedico Gaetano Pini, Milan, Italy. <https://orcid.org/0000-0002-9715-6989>. E-mail: antonio.memeo@asst-pini-cto.it.

**Даниэле Приано** — ординатор. Университет Милана, Институт ортопедии Дж. Пини, Милан, Италия. <https://orcid.org/0000-0002-5123-4478>. E-mail: daniele.priano@gmail.com.

**Марио Д'Эррико\*** — ординатор. Университет Милана, Милан, Италия. <https://orcid.org/0000-0003-4328-5344>. E-mail: marioderrico@gmail.com.

**Лаура Перетто** — хирург-ортопед, отделение детской ортопедии, Институт ортопедии Дж. Пини, Милан, Италия. <https://orcid.org/0000-0001-5664-3687>. E-mail: laura.peretto@gmail.com.

**Антонио Мемео** — хирург-ортопед, заведующий отделением детской ортопедии. Институт ортопедии Дж. Пини, Милан, Италия. <https://orcid.org/0000-0002-9715-6989>. E-mail: antonio.memeo@asst-pini-cto.it.