

SURGICAL TREATMENT OF THUMB ADDUCTION CONTRACTURE IN CHILDREN WITH INFANTILE CEREBRAL PALSY

Novikov V.A., Umnov V.V.

The Turner Institute for Children's Orthopedics, Saint Petersburg, Russian Federation

Purpose. To evaluate the effectiveness of different methods for the surgical treatment of thumb adduction contracture in children with infantile cerebral palsy.

Materials and methods. Children with infantile cerebral palsy and affected upper limbs were included in the study. The main criterion for selection was the presence of thumb adduction contracture, absence of significant positive outcome in patients after conservative treatment, inability to achieve active thumb abduction $> 30^\circ$, and instability of the first metacarpophalangeal joint. A total of 9 patients with spastic types of cerebral palsy were examined and treated.

Results and conclusions. We evaluated the results of the following types of surgical treatment: release of the adductor pollicis muscle, release of the adductor pollicis muscle and tendon shortening of m. abductor pollicis longus, release of the adductor pollicis muscle and tendon transfer of m. extensor indicis in the tendon m. abductor pollicis longus, and fixation of the first metacarpophalangeal joint extramedullary plate. We confirmed the effectiveness of the surgical treatment of thumb adduction contracture.

Keywords: infantile cerebral palsy, upper limb, spastic arm, thumb adduction contracture, surgical treatment.

Deformation of the thumb in children with cerebral palsy (CP) in the world literature is called "Thumb-in-Palm Deformity" ("finger in the palm of your hand"). [1] In the domestic literature, this deformity is most often described as an adduction or flexion-adduction contracture of the thumb. [2] The development of such contractures significantly limits hand function because an adducted and bent thumb is nonfunctional and interferes with the ability to grab objects with the entire hand. [2–5]

This syndrome is primarily caused by spasticity of the adductor muscle, the first dorsal interosseous muscle, and the long and short flexor muscles of the thumb as well as by the simultaneous weakening of the abductor and extensor muscle groups of the thumb. [6] According to House J.H., the presence of fixed contractures of the thumb almost always leads to changes in the first metacarpal of the thumb. [3] The thumb adductor contracture contributes to the deformity, mainly in the navicular-trapezoidal and trapezoidal-metacarpal joints. Thus, there is limited abduction of the first metacarpal bone. Flexion

contractures of the thumb leads to deformation of the metacarpophalangeal and interphalangeal joints that primarily interfere with the extension of the thumb. Treatment of this deformity includes surgery of the dynamic soft tissue and static bone.

Miller F. indicates that in children with spastic syndrome of the upper limb, muscle flexion-adduction spasm of the first finger occurs during infancy. [1] The development of contractures depends on the severity of the syndrome, the form of the disease, and the presence of additional pyramidal and extrapyramidal system (dystonia, hyperkinesia) symptoms. In children with moderate tetraplegia or severe hemiplegia, fixed contracture occurs at an average age of 5–10 years, and the forms of cerebral palsy that are more severe occurs at an average age of 1.5–5 years in early childhood. Most studies indicate that the course of this deformation is very malignant, particularly if left untreated. [1, 3, 7–9] Flexion-adduction deformity of the thumb, when age limits proper hygiene of the fingers and palm, leads to trophic

disorders of the hand, and long-term deformation contributes to secondary arthrosis with pain and instability in the metacarpophalangeal joint of the thumb. [10, 11]

The goals of surgery to treat flexor-adductor contracture deformity of the thumb may be reconstructive and palliative. In general, the majority of surgeons determine the following objectives of orthopedic treatment:

- removing flexor-adductor contracture of the thumb,
- strengthening weakened antagonist muscles,
- stabilizing the first ray joints.

The aim of our study was to evaluate the effectiveness of different surgical methods to treat flexion-adduction contracture deformities of the thumb.

Materials and methods

The present study is based on the results of examination and treatment of children with cerebral palsy with affected upper limbs who were admitted to the Turner Institute for Children's Orthopedics Saint-Petersburg, Russian Federation from 2010 to 2015. We examined and treated nine patients with cerebral palsy, aged 6–18 years.

The criteria for selection of patients to undergo surgery to treat flexion-adduction contractures of the thumb in our study were as follows:

- Lack of significant results of conservative treatment as well as botulinum toxin type-A treatment or radiofrequency ablation (RFA).
- Absence of active abduction of the thumb (or metacarpal bone in the presence of a dislocation in the metacarpophalangeal joint) up to 30°. We chose this abduction as the minimum necessary to obtain the release of the palm and gripping by the subject.
- Presence of a dislocation in the metacarpophalangeal joint of the thumb accompanied by discomfort or pain in this area.
- Inability to make full use of mechanical support because of the incorrect position of the thumb. The thumb is positioned in the palm of the hand, making it difficult to grip a support.

Despite the incorrect position of the thumb, if the child is able to use a cane or walker, the support is not on the eminence of the thumb

but on the adducted metacarpal bone. Children who move over long distances aided by a support can develop pain in the metacarpal bone of the thumb, which may represent a limiting factor in their ability to walk independently. Clinical evaluation was the main method employed in the present study. We considered the patient's ability to passively and actively retract and extend the thumb. The function of the hand was assessed objectively using the Box and Block Test as well as subjectively by administering a survey to patients and their parents. The patient's task in the Box and Block Test was to collect cubes on the surface of a table and place them in a box. The time required objectively determined the change in hand function because of treatment.

Because hand dysfunction affected the flexion position of the thumb as well as adduction, fixed flexion contracture was diagnosed. Patients actively extended the interphalangeal joint of the thumb, and the existing position of the extensor metacarpophalangeal joint was due to adductor contracture of the thumb. Based on the prevalence of the functional significance of adduction of the thumb on bending, we focused our attention on the elimination of adduction contractures of the thumb. To eliminate incorrect positioning of the thumb, we operated on nine patients. The ages of the patients were as follows:

- Children up to 7 years: one patient.
- Children aged 7–14 years: six patients.
- Children over 14 years: two patients.

Because the effect of eliminating flexion contracture on the function of the thumb has been noted, we assessed only the improvement of thumb abduction. Treatment outcomes were evaluated after patients completed the initial course of physiotherapy (on an average, 2 weeks after the beginning of the development of hand movements) and 3 months later. After analyzing the data for preoperative examination, we noted exacerbation of thumb contractures according to the age of the patient as well as a significant difference between active and passive movements as the patients aged. Passive abduction of the thumb with increasing age decreased less significantly compared with active abduction. Because surgery causes contractures of the thumb, we used the following three techniques:

- Release of the thumb adductor muscle.

- Release of the thumb adductor muscle and shortening of the M. abductor pollicis longus tendon.
- Release of the thumb adductor muscle and transfer of the tendon of the extensor of the second finger (M. extensor indicis) to the M. abductor pollicis longus tendon.
- Fixation of the first metacarpophalangeal joint to the extramedullary plate.

Results and Discussion

We performed surgery to release the thumb adductor muscle for four patients. Patients were anesthetized during the examination before surgery, and there was no increase in the passive range of motion of the thumb. Surgery improved intraoperative abduction of the thumb of all patients, reaching an angle of 70°. After 2 weeks of rehabilitation, passive abduction of the thumb of all patients increased (achieved on the operating table) by an average of 7.5°. The increase in the passive range of abduction averaged 32.5° compared with the initial value.

The clinical characteristics of active abduction of the thumb after surgery were as follows: 1) The range of active abduction of the thumbs of two patients decreased by 5°, 2) A rocking motion of the thumb was achieved by one patient, and 3) Active abduction of 10° was gained by one patient.

Analysis of the results 3 months after surgery showed that the amplitude of passive abduction decreased in all patients by an average of 15° compared with the previous results. Active abduction of the thumb increased by 10°–20° (average, +13°) (Table 1).

Analysis of the data presented in Table 1 shows that this type of surgery increased the range of passive abduction of the thumbs of all patients. We did not detect a correlation between the increase in the range of passive abduction of the thumb after surgery and the patients' ages. In contrast, the range of active movement was clearly age-dependent. Thus, younger patients exhibited a greater range of active abduction after surgery.

Despite surgical outcomes, we achieved a positive change in the range of motion of the thumb, although no significant changes in hand function were experienced by the patients or observed by us. Analysis of hand function before and after surgery using the Box and Block Test reflected a temporary deterioration of hand function 2 weeks after starting physiotherapy and a return to the original values in 3 months (Table 2).

Despite the lack of functional changes, the outcomes of surgery were judged positive by all patients, which was primarily because of some improvement in the appearance of the hand as well as the elimination of discomfort when using splints.

Table 1

Dynamics of the average values of active and passive abduction of the thumb after the release of the thumb adductor muscle

	Before surgery	After 2 weeks of physiotherapy	3 Months after surgery
Passive abduction of the thumb	45°	77.5°	62.5°
Active abduction of the thumb	15°	12°	25°

Table 2

Analysis of the average time dynamics of the Box and Block Test in patients after thumb adductor release

	Box and Block test
Before surgery	93 s
After 2 weeks of physiotherapy	145 s
3 months after surgery	92 s

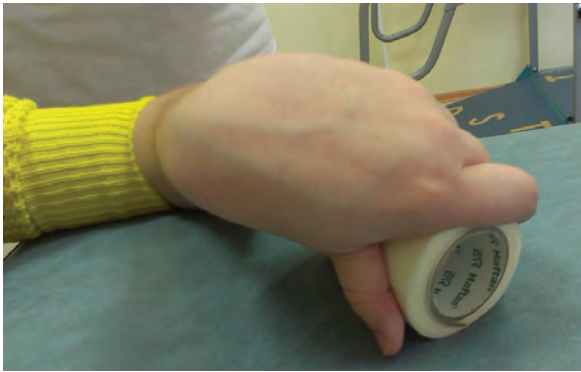

Figure 1. Patient O., 17 years old. Attempt to grab an object.

All patients simultaneously noticed after surgery that the use of a dynamic (tenodesis) splint that abducts the thumb facilitated the use of the hand. This outcome was studied using the Box and Block Test, and the average results were as follows: 92 s without a splint and 76 s with a dynamic splint. These results showed a significant increase in the speed of execution of the test by patients who used a dynamic splint. Although this improvement was achieved using an orthosis and not surgery, there was a correlation between the results of treatment and the Box and Block Test. Patients had difficulty using dynamic splints before surgery, and the time of use was strongly limited by pain. Release of the thumb adductor muscle removed the time restriction on the use of orthoses for the hand.

To summarize, we evaluated the outcome of this type of surgery of the thumb adductor contracture as unsatisfactory. Although all patients had an increased range of motion of passive

abduction of the thumb, the effect of surgery on active abduction (e.g., hand function) was insufficient.

To increase the range of active thumb abduction, in addition to the release of the thumb adductor muscle, we shortened the tendon of the long abductor muscle (*M. abductor pollicis longus*) of two patients. The purpose of increasing the extent of surgical intervention was to eliminate the functional weakness of the *M. abductor pollicis longus*. We believe that the weakening of the *M. abductor pollicis longus* was because of overstretching due to the prolonged incorrect adductive position of the thumb. The results of this type of surgery were as follows: the range of passive abduction of the thumb after surgery = 65°, the range of active abduction = 20°.

Thus, the results of the modified initial surgery were similar to that of the release of an isolated thumb adductor muscle. Although we noticed the active movements of the thumb much earlier after modified surgery, the results after 3 months were the same. Surgery did not achieve an additional increase in the range of active thumb abduction. Findings of the analysis of hand function using the Box and Block Test were similar as follows: before surgery, 92 s; after surgery, 96 s; and after 3 months, 90 s.

To summarize this type of treatment, despite the expansion of surgical intervention, the outcome of surgery was identical to the release of the thumb adduction muscle.

We achieved an increase in the range of active thumb abduction in two patients with the addition of transfer of the tendon of the second

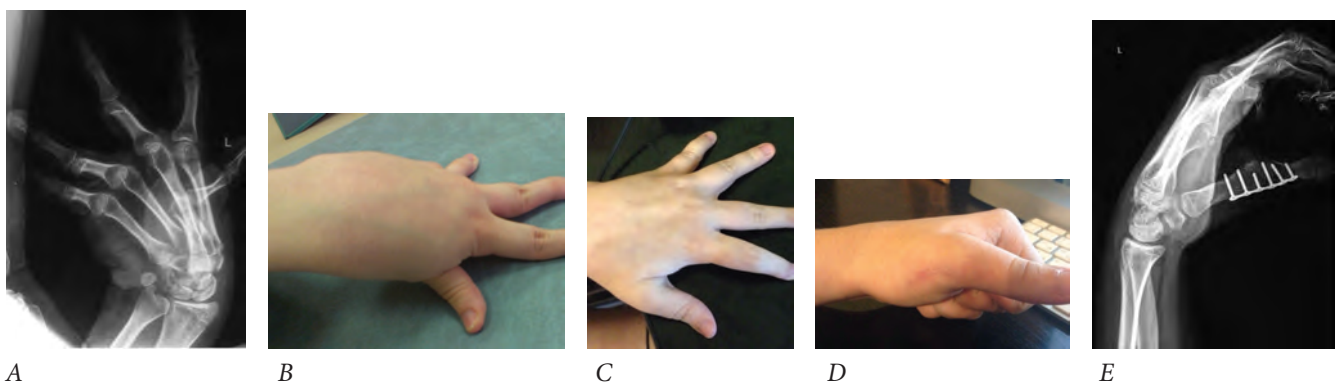


Figure 2. Patient O., 17 years old. A: Frontal projection of an X-ray image of the patient's hand. Dislocation of the metacarpophalangeal joint, adduction of the first metacarpal bone. B: Position of the patient's hand before surgery. C and D: Position of the patient's hand 10 months after surgery. E: Lateral projection of the X-ray image of the patient's hand after surgery

finger extensor muscle (*M. extensor indicis*) to the *M. abductor pollicis longus* to release the thumb adductor muscle. The first patient (8 years of age) gained passive abduction of 22°, whereas active abduction increased in 2 weeks by +10° and in 3 months by +30°. The second patient (16 years of age) achieved an increase in passive abduction of the thumb by 20°. Active abduction of the thumb during 2 weeks remained at the preoperative level, and after 3 months, we noted an increase in movement by +25°. Surgery did not cause difficulties in the active extension of the second finger.

Comparison of the effectiveness of this type of surgery and isolated release of the thumb adductor muscle demonstrated the lack of an effect of second finger extensor transplantation on the dynamics of passive thumb abduction, although the active abduction of the thumb more than doubled. We also found a direct correlation between the increase in the range of active abduction of the thumb and improved performance of tests of function. Unfortunately, despite the obvious age-dependence of the results obtained in the latter group of patients, we were unable to draw conclusions on the basis of only two outcomes. Nevertheless, we evaluated the results of this type of surgery as good.

Fixation of the metacarpophalangeal joint to the extramedullary plate was performed once. The patient was 17 years old at the time of surgery. While leaning on her hand, she complained of severe hand dysfunction due to the incorrect position of the thumb as well as pain in the metacarpophalangeal joint. Because this girl moved independently using a cane, pain limited her upper-limb function as well as her ability to walk.

Before surgery, active abduction of the thumb was achieved only by hyperextension of the metacarpophalangeal joint, which was extremely difficult. Grabbing an object with the hand was accomplished by pressing the object with the second and third fingers to the head of the first metacarpal bone (Figure 1). Concurrently, the initial independent abduction of the thumb outside of the palm was impossible and was performed using the other hand or with a support and subsequent pressure on the thumb.

Thus, despite good overall hand motor ability, the patient used the left limb only as a “paperweight.” Therefore, we were not able to administer the Box and Block Test to this patient because she was unable to grab a cube.

Physiotherapy started 7 days after surgery, and there were immediate improvements in the child's hand condition (Figure 2).

The range of passive abduction remained the same after surgery, but active abduction was now possible (Table 3). The patient was followed for 10 months after surgery. During this time, there were no changes in the dynamics of the range of motion of the thumb. Fixation of the metacarpophalangeal joint was stable, and the patient did not complain of pain or discomfort.

The results of the functional test «Box and Block Test» are shown in Table 4.

Analysis of the results of the functional test shows that hand activity started almost immediately after fixation of the metacarpophalangeal joint. Further training during the next 3 months significantly improved the results of the test. No further improvements in the performance of the Box and Block Test may indicate that the patient's hand reached its maximum function.

Table 3

Dynamics of thumb abduction range of movement of patient O

	Before surgery	After 2 weeks of physiotherapy	3 months after surgery
Passive thumb abduction	40°	40°	50°
Active thumb abduction	0°	25°	40°

Table 4

Dynamics of the results of the Box and Block Test of patient O

	Box and Block Test
Before surgery	N/A
2 weeks after surgery	72 s
3 months after surgery	35 s
10 months after surgery	32 s

After surgery, we noted the rapid positive effect of conservative medical treatment on the overall condition of this patient's upper limb. However, 6 months of conservative treatment before surgery, which was designed to stabilize the metacarpophalangeal joint, was not effective. The success of restorative surgery can be explained only by the elimination of a "limiting factor," which, in our opinion, was the instability of the first metacarpophalangeal joint. We rated the outcome of this type of surgery as good.

Conclusion

Our preliminary data presented here indicates that thumb adductor muscle release, which is performed in isolation or in combination with shortening of the M. abductor pollicis longus tendon, was ineffective. We noted an improvement in the cosmetic appearance of the hand and easier use of splints. However, in most cases, we did not observe a significant improvement in active thumb abduction and hand function. Release of the thumb adductor muscle, together with the transplant of the M. extensor indicis tendon to the M. abductor pollicis longus not only made it possible to increase passive and active abduction of the thumb but also significantly affected hand function. This type of surgery is promising; therefore, it requires further study.

Fixation of the first metacarpophalangeal joint to the extramedullary plate as well as any other kind of arthrodesis allows full resolution of the instability of the joint. Because an incorrect position of the metacarpophalangeal joint significantly

limits the general functions of the hands and upper extremities, such surgery is generally successful. We show here the promise of such surgical interventions to treat adolescent patients. The development of a surgical procedure is required that will not lock the metacarpophalangeal joint, but at the same time, will limit the overextension of the joint.

References

1. Miller F. Cerebral palsy / F. Miller. – N.Y., 2005. – P. 387-432.
2. Ненько А. М. Хирургическое лечение контрактур и деформаций верхней конечности у детей с церебральными параличами. – СПб., 1992. [Nenko AM. Khirurgicheskoe lechenie kontraktur i deformatsii verkhnei konechnosti u detei s tserebralnymi paralichami. Saint-Petersburg, 1992. (In Russ).]
3. House JH, Gwathmey F, Fidler M. A dynamic approach to the thumb-in-palm deformity in cerebral palsy. *J. Bone Joint Surg.* 1981;63:216-225.
4. Sakellarides HT, Mital MA, Matza RA, Dimakopoulos P. Classification and surgical treatment of the thumb-in-palm deformity in cerebral palsy and spastic paralysis. *J. Hand. Surg.* 1995;20-A:428-459.
5. Van Heest AE. Surgical management of wrist and finger deformity. *Hand. Clin.* 2003;19:657-722.
6. Hoffer MM, Perry J, Melkonian GJ. Postoperative electromyographic function of tendon transfers in patients with cerebral palsy. *Dev. Med. Child. Neurol.* 1990;32:789-791.
7. Özkan T, Tunçer S. Tendon transfers for the upper extremity in cerebral palsy. *Acta. Orthop. Traumatol. Turc.* 2009;43:135-183.

8. Tonkin MA, Hatrick NC, Eckersley JR, et al. Surgery for cerebral palsy part 3: classification and operative procedures for thumb deformity. *J. Hand. Surg.* 2001;26-B:465-535.
9. Arner M, Eliasson AC, Nicklasson S, et al. Hand function in cerebral palsy. Report of 367 children in a population-based longitudinal health care program. *J. Hand. Surg.* 2008;33:1337-1347.
10. Feys H, Eyssen M, Jaspers E, et al. Relation between neuroradiological findings and upper limb function in hemiplegic cerebral palsy. *Eur. J. Paediatr. Neurol.* 2010;14:169-177.
11. Van Zelst BR, Miller MD, Russo R, et al. Activities of daily living in children with hemiplegic cerebral palsy: a cross-sectional evaluation using the assessment of motor and process skills. *Dev. Med. Child. Neurol.* 2006;48:723-727.

Information about the authors

Novikov Vladimir Alexandrovich — MD, research associate of the department of infantile cerebral palsy. The Turner Scientific and Research Institute for Children's Orthopedics.

Umnov Valery Vladimirovich — MD, PhD, professor, head of the department of infantile cerebral palsy. The Turner Scientific and Research Institute for Children's Orthopedics. E-mail: umnovvv@gmail.com.