

# ANALYSIS OF THE SURGICAL TREATMENT OF STENOTIC LIGAMENTITIS OF FINGERS IN CHILDREN

Govorov A.V., Zavarukhin V.I.

The Turner Institute for Children's Orthopedics, Saint-Petersburg, Russian Federation

**Purpose of the study.** Clinical analysis of the surgical treatment of stenotic ligamentitis of fingers in children.

**Materials and methods.** A retrospective analysis of data examining 140 children and surgical treatment of 105 children with the diagnosis of "constrictive ligamentitis of fingers" was performed in the G. I. Turner Research Institute for Children's Orthopedics in the period from 2011 to 2013. We considered gender and age of patients, the symptoms of the disease and patient complaints, and nature of the preferential affection of one or both hands and fingers as well as the family history.

**Results.** Regarding gender, the patients were evenly distributed: 54 girls (51%) and 51 boys (49%). The largest number of children in need of surgical treatment (89) belonged to the age group of 1–4 years (85%). The prevalence of pre-emptive affection of fingers of one of the limbs has not been noted. The disease was mostly diagnosed on the first finger (131 cases). Recurrence of deformity in the long term was not noted.

**Conclusion.** Conservative treatment may contribute to the progression of deformity. The applied surgical treatments permitted the maximum functional and cosmetic result.

**Keywords:** constrictive ligamentitis of fingers, surgical treatment, children.

## Introduction

Stenotic ligamentitis of fingers is a disorder caused by the differentiation of the tendomuscular system [1, 2]. This disorder was first documented by the French physician A. Notta in the journal *Archives of General Medicine* in 1850. This article described the treatment of four adult patients who had a node on a deep finger flexor tendon preventing the normal movement of the finger [3].

The disorder is rather widespread in children, with 3.3% of 1000 newborns affected [4]. The first finger is affected in most children (up to 89%), with the effect often being ambilateral. This disorder is also found in triphalangeal fingers [1, 5].

Documented treatment modalities are conservative or surgical. Conservative treatment mostly involves physiotherapeutic procedures. Electrophoresis with lydazum and hydrocortisone is used in most cases. However, efficacy is only documented at the initial presentation of the disorder [1]. Thermal procedures and massage may exacerbate progression [1]. Corticosteroid injections have proven to be effective and have been recommended before surgical treatment by a number of authors [6]. However, a significant number and variety of complications associated with this therapy bring its advisability into question. The most common complications include skin atrophy in the area of

injection, subcutaneous fat necrosis, and skin hypopigmentation [6]. Occasionally, corticosteroid injections may cause tendon rupture [7].

A method of percutaneous dissection of the first annular ligament has been described and widely used as an alternative to surgical treatment. This method was first documented by J. Lorthior in 1956 [8]. Other authors have developed special instruments for this operation. However, complications still occur in 30% of cases. D. Gulabi et al. described the clinical treatment of 60 patients. The most common complications are partial tendon injury, temporary sensory anesthesia, and incomplete reversal of deformity [9, 10].

Open surgical treatment allows for the careful dissection or excision of the annular ligament and revision of the tendon and its sheath. Many different dissection designs are documented that provide surgical exposure of the first ligament. They are subdivided into three categories: longitudinal, transverse, and combined. The use of longitudinal dissections in the median line of the arm with transition to the area of the metacarpophalangeal joint causes aching surgical scars, and finger flexion contracture develops in the long term [1].

The purpose of this research was to analyze the results of the surgical treatment of stenotic ligamentitis of fingers in children.

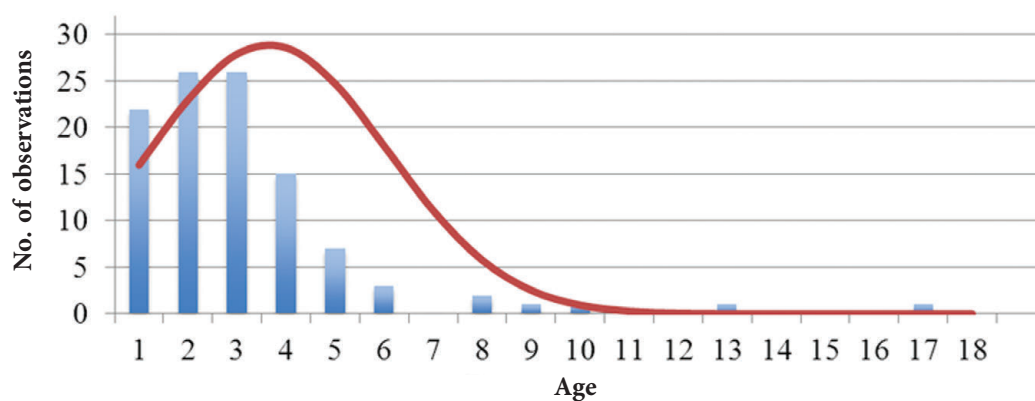


Fig. 1. Distribution of children according to age and number of examinations

## Material and methods

From 2011 through 2013, we analyzed the results of the examination of 140 children diagnosed with stenotic ligamentitis of fingers, who presented to the Consultation and Diagnostic Center at the Turner Scientific Research Institute of Children's Orthopedics. Of these children, 105 were admitted for surgical treatment. The collected data were retrospectively analyzed, including sex and age of the children, symptoms of the disorder and complaints of the children, nature of the predominant effect of one or both hands and fingers, and hereditary history.

## Results

Of the 140 children referred for consultation, 132 were newly admitted. Eight children required medical attention due to the relapse of the deformity: seven after prior percutaneous ligamentotomy and one after surgical treatment. Relapse occurred at 2 to 5 months (average  $2.7 \pm 1.2$  months). The treatment was performed according to the place of residence. A total of 105 children (75%) with 137 finger disorders were admitted to the Hand Surgery and Reconstructive Microsurgery Clinic for surgical treatment. Of 35 children not admitted for surgical treatment, 11 presented to other hospitals, while 24 (17%) experienced recession of stenotic ligamentitis. In terms of sex, the children were evenly distributed: 54 girls (51%) and 51 boys (49%). The age of the children ranged from 1 to 17 years (average  $3.1 \pm 2.4$  years; Fig. 1). There were no newborns in the group.

Most children who required surgical treatment (89, or 85%) were 1 to 4 years old, while 22 (21%) were 1 year old. Surgical treatment was performed in 16 children who were more than 5 years old. No

predominant effect of the fingers of one hand was observed. Stenotic ligamentitis occurred in the left hand in 39 children (37%), right hand in 34 (32%), and bilaterally in 32 (31%). In most children (131), the disorder was diagnosed on the first finger. One child had ambilateral stenotic ligamentitis of the fifth finger, while four had stenotic ligamentitis of the third and fourth fingers. In no child was the second finger affected.

The analysis of disorder development history showed that the parents of most children (64, or 61%) noticed on their own that the affected finger's movement was limited. Some parents associated the deformity with trauma (8, or 8%). The deformity was also diagnosed by a surgeon or an orthopedic traumatologist during preventive examination (33, or 31%). This disorder had never previously occurred in any of the families.

During clinical examination, joint hypermobility was diagnosed according to Carter's criterion. By the end of the examination, 47 children (45%) were diagnosed with significant joint hypermobility. One of the diagnostic characteristics was determining the blanching rash at pressure, which occurred in all children with the first finger affected.

During treatment, special attention was paid to the intraoperative examination of flexor tendons and the presence of nodes on them. A node on the tendon of the long first finger flexor was found in 81 children (77%). In two children, changes in the tendon of the flexor of the third or fifth finger caused limited movement after the excision of the first annular ligament. Spindle resection of the central portion of the tendon node reduced its size, allowing complete restoration of the fingers' range of movement. In one child, an edge defect of the

long first finger flexor tendon was observed after percutaneous ligamentotomy.

Three months postoperatively, the children were invited for a control examination to evaluate the results of the treatment. All children completely recovered full range of movement of the metacarpophalangeal and interphalangeal joints. No child experienced pain syndrome or a click when moving the finger, which would indicate disorder relapse. The surgical scar was barely noticeable and did not cause any functional disorders.

The clinical examples given below illustrate the features of diagnosis and stages of surgical treatment of children diagnosed with stenotic ligamentitis of the first and fifth fingers. Different topographic/anatomic locations of the first annular ligaments of the first and long fingers determined different approaches and tactics for surgical treatment.

The parents of two 4-year-old children presented their children to the Consultation and Diagnostic Center with complaints of limited movement of the first finger of the right hand and fifth finger of both hands. While taking the history, a gradual development of the disorder was determined. Six months before presentation to the hospital, the parents noticed rigidity of the fingers, particularly in the morning. The first finger unbent with a click without pain, which would resolve by evening. After a massage course, the first finger became less mobile. It became impossible to fully unbend the first finger, and trying to do so was painful. The child diagnosed with stenotic ligamentitis received no conservative treatment. First finger stenotic ligamentitis diagnosis was confirmed: a round mass that was 5 mm in diameter was visible in the annular ligament. It was mobile and not glomerate with the surrounding tissues and with positive blanching rash at pressure. The flexion contracture in the interphalangeal joint could not be passively removed (Fig. 2). The differential diagnostics was camptodactyly in the child diagnosed with a deformity of the fifth finger. An X-ray image of the fifth finger in the lateral projection revealed no sign of changes in the bone-joint structure. No soft tissue deficiency on the palmar surface was determined during physical examination.

The chosen dissection design was a transverse incision in the projection of the first annular ligaments made in skin folds. The access provided good visualization of the deformed ligament and

neurovascular bundles and allowed for tendon revision. The child diagnosed with stenotic ligamentitis of the first finger had a node on the tendon (Fig. 4) that required spindle excision of the central portion of the tendon (Fig. 5). No obvious changes in the fifth finger's deep flexor tendon were seen. The result of the treatment was intraoperatively determined and involved the complete recovery of movement (Fig. 6, 7). There was no relapse 3 months postoperatively.

## Discussion

Stenotic ligamentitis in children is a disorder with several stages of development [1]. It is most common in 1–4-year-old children, which was noted by other authors as well [1, 5, 11]. We did not observe children under 6 months old, probably due to the rather narrow selection criteria of children.

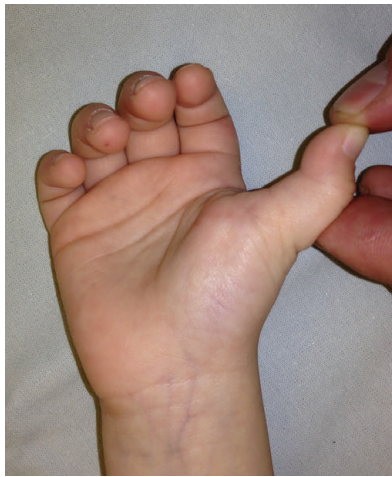This research showed that the exclusion of mechanical stimuli, such as massage and movement workouts, may lead to the regression of stenotic ligamentitis, as confirmed by other authors [1, 5]. If movements persist in the involved finger, observation is recommended. Flexion contracture requires surgical treatment.

A high deformity relapse rate after percutaneous ligamentotomy signifies a low efficacy of the method. This also was noted by several authors who performed a comprehensive examination of patients who received treatment via this method. Special attention should be paid to changes in tendon diameter because of its gradual growth and node formation, thus requiring surgical correction in 99% of cases. This gives us reason to consider percutaneous ligamentotomy to be even less effective as it makes tendon revision and correction impossible.

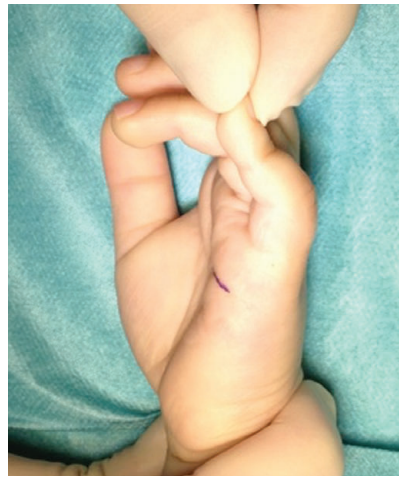Although some authors suggest using longitudinal incisions to avoid damage to neurovascular bundles [5], transverse incisions provide good visualization of anatomical structures and are more physiological and cosmetic.

The execution of all components of surgical treatment, excision of the first annular ligament, tendon revision, and correction, allows for the avoidance of deformity relapse. If, during surgical treatment, only the excision of the first annular ligament is performed, including a revision and, if needed, correction of the ligament, then deformity persistence and early relapse occur in only 4% of cases [4].

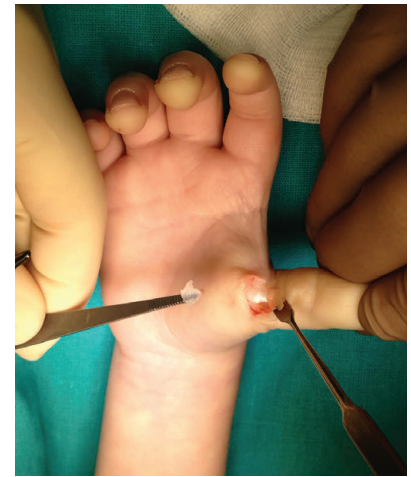



**Fig. 2.** External appearance of the hand in a child diagnosed with stenotic ligamentitis of the first finger of the right hand



**Fig. 3.** External appearance of the hand in a child diagnosed with stenotic ligamentitis of the fifth finger of the right hand



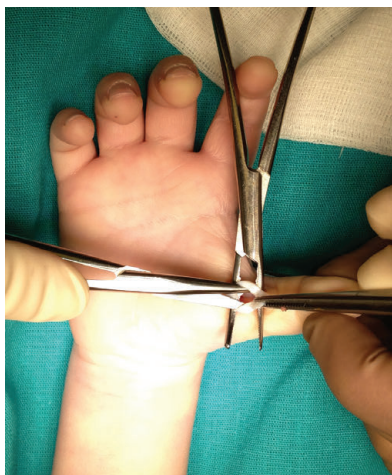**Fig. 4.** Surgery stage: annular ligament is excised, and a node on the long first finger flexor tendon is determined

## Conclusions

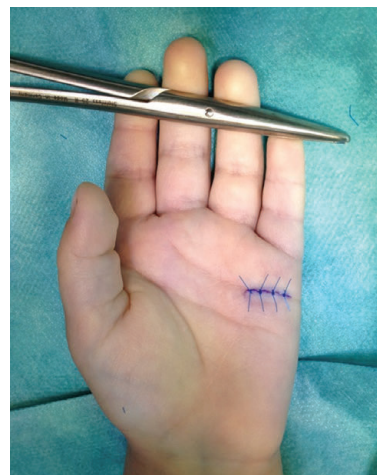Stenotic ligamentitis in children mostly affects the first finger and is often ambilateral. Treatment tactics should depend on the disorder state. Observation, excluding thermal procedures, massage, or workouts, is recommended for newly-admitted patients and those without flexion contracture. Finger flexion contracture requires surgical treatment. Dissections providing access to the first annular ligament must be transverse, going along skin folds. In any case, tendon revision and correction are required. The execution of all components of surgery allows for the recovery of the complete range of movement and reduces the risk of relapse.

## References

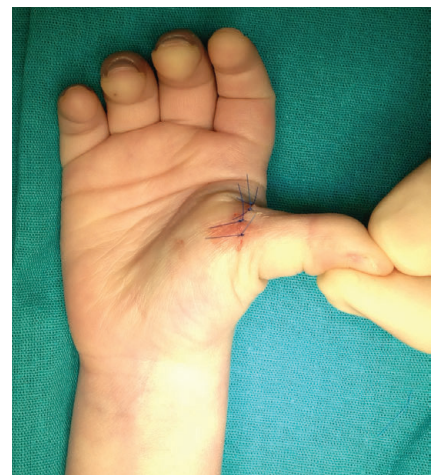1. Печора Т.А. Клиника и лечение стенозирующего лигаментита пальцев кисти у детей: дис. ... канд. мед. наук. – Л., 1988. [Pechora TA. Klinika i lechenie stenoziruyushchego ligamentita paltsev kisti u detei [dissertation]. Leningrad; 1988. (In Russ).]
2. Ezaki M. Trigger thumb. In: Herring JA (ed). *Pediatric Orthopaedics* (3<sup>rd</sup> ed) Vol. 1. Philadelphia: WB Saunders Co; 2002;445.
3. Notta A. Recherches sur une affection particuliere des gaines tendineuses de la main. *Arch Gen Med.* 1850;24:142.
4. Leung OY, Ip FK, Wong TC, Wan SH. Trigger thumbs in children: results of surgical release. *Hong Kong Med J.* 2011;17(5):372-375.
5. Shah AS, Bae DS. Management of Pediatric Trigger Thumb and Trigger Finger. *J Am Acad Orthop Surg.* 2012;20(4):206-13. doi: 10.5435/jaaos-20-04-206.



**Fig. 5.** Surgery stage: spindle resection of the central portion of the long first finger flexor tendon



**Fig. 6.** Result of the surgery: deformity removed



**Fig. 7.** Result of the surgery: deformity removed

6. Makkouk AH, Oetgen ME, Swigart CR, Dodds SD. Trigger finger: etiology, evaluation, and treatment. *Curr Rev Musculoskelet Med.* 2007;1(2):92-6. doi: 10.1007/s12178-007-9012-1.
7. Taras JS, Iiams GJ, Gibbons M, Culp RW. Flexor pollicis longus rupture in a trigger thumb: a case report. *J Hand Surg Am.* 1995;20(2):276-277. doi: 10.1016/S0363-5023(05)80024-3.
8. Lorthioir J. Subcutaneous surgery in trigger finger. *Acta Chir Belg.* 1956;55(3):246-252.
9. Gulabi D, Cecen GS, Bekler HI, et al. A study of 60 patients with percutaneous trigger finger releases: clinical and ultrasonographic findings. *J Hand Surg (Eur Vol).* 2014;39(7):699-703. doi: 10.1177/1753193413517992.
10. Ryzewicz M, Wolf JM. Trigger digits: principles, management, and complications. *J Hand Surg Am.* 2006;31(1):135-146. doi: 10.1016/j.jhsa.2005.10.013.
11. Schaverien MV, Godwin Y. Paediatric trigger finger: Literature review and management algorithm. *J Plast Reconstr Aesthet Surg.* 2011;64(5):623-31. doi: 10.1016/j.bjps.2010.09.011.

## АНАЛИЗ ХИРУРГИЧЕСКОГО ЛЕЧЕНИЯ СТЕНОЗИРУЮЩЕГО ЛИГАМЕНТИТА ПАЛЬЦЕВ КИСТИ У ДЕТЕЙ

© *Говоров А.В., Заварухин В.И.*

ФГБУ «НИДООИ им. Г. И. Турнера» Минздрава России, Санкт-Петербург

**Цель исследования.** Клинический анализ результатов хирургического лечения стенозирующего лигаментита пальцев кисти у детей.

**Материалы и методы.** Проведен ретроспективный анализ результатов обследования 140 детей и оперативного лечения 105 детей с диагнозом «стенозирующий лигаментит пальцев кисти», обратившихся в НИДООИ им. Г. И. Турнера, в период с 2011 по 2013 год. Рассматривались пол и возраст пациентов, симптомы заболевания и жалобы больных, характер преимущественного поражения одной или обеих кистей, а также пальцев, уточнялся наследственный анамнез.

**Результаты.** Прооперированные пациенты были распределены равномерно: 54 девочки (51 %) и 51 мальчик (49 %). Наибольшее количество детей, нуждающихся в оперативном лечении (89), относилось к возрастной группе от 1 года до 4 лет (85 %). Преимущественного преобладания поражения пальцев кисти одной из конечностей не отмечалось. Наиболее часто данное заболевание диагностировалось на первом пальце (131 случай). Рецидива деформации в отдаленном периоде не отмечалось.

**Заключение.** Консервативное лечение может способствовать прогрессированию деформации. Применяемая методика оперативного лечения позволяет получить максимальный функциональный и косметический результат.

**Ключевые слова:** стенозирующий лигаментит пальцев кисти, хирургическое лечение, дети.

### *Information about the authors*

**Govorov Anton Vladimirovich** — MD, PhD, research associate of the department of reconstructive microsurgery and hand surgery. The Turner Scientific and Research Institute for Children's Orthopedics. E-mail: agovorov@yandex.ru.

**Zavarukhin Vladimir Ivanovich** — MD, research associate of the department of reconstructive microsurgery and hand surgery. The Turner Scientific and Research Institute for Children's Orthopedics. E-mail: zavarukhin.md@gmail.com.

**Говоров Антон Владимирович** — к. м. н., научный сотрудник отделения реконструктивной микрохирургии и хирургии кисти ФГБУ «НИДООИ им. Г. И. Турнера» Минздрава России. E-mail: agovorov@yandex.ru.

**Заварухин Владимир Иванович** — научный сотрудник отделения реконструктивной микрохирургии и хирургии кисти ФГБУ «НИДООИ им. Г. И. Турнера» Минздрава России. E-mail: zavarukhin.md@gmail.com.