

## MALIGNANT TUMORS OF THE STERNUM IN PEDIATRIC PATIENTS: REPORT OF TWO CASES AND LITERATURE REVIEW

© *A.S. Maletin, V.I. Zorin, V.A. Gileva, T.A. Novitskaya, A.Yu. Mushkin*

Saint-Petersburg State Research Institute of Phthisiopulmonology, Saint Petersburg, Russia

Received: 10.04.2017

Accepted: 08.08.2017

Destructive changes in the bones are rarely observed in daily practice of pediatric orthopedic surgeons. Clinical and X-ray signs of destructive changes in the bone tissue are characteristic of tumoral, infectious, and inflammatory damages of bones. These signs do not always correspond to a specific disease, and differential diagnostics without histological evaluation is difficult. This is especially true for tumors of the sternum, 85% of which are malignant.

Two rare clinical cases of primary malignant sternal neoplastic lesions in pediatric patients, and a detailed analysis of their clinical, radiologic, and morphologic data are presented. The importance of early histological verification for determining the choice of treatment is demonstrated. A short literature review is also presented.

**Keywords:** sternum malignant tumor, Hodgkin's lymphoma, children, chondrosarcoma.

## ЗЛОКАЧЕСТВЕННЫЕ ОПУХОЛИ ГРУДИНЫ У ДЕТЕЙ (РЕДКИЕ КЛИНИЧЕСКИЕ НАБЛЮДЕНИЯ И КРАТКИЙ ОБЗОР ЛИТЕРАТУРЫ)

© *А.С. Малетин, В.И. Зорин, В.А. Гилева, Т.А. Новицкая, А.Ю. Мушкин*

ФГБУ «СПбНИИ фтизиопульмонологии» Минздрава России, Санкт-Петербург

Статья поступила в редакцию: 10.04.2017

Статья принята к печати: 08.08.2017

Деструктивные поражения осевого скелета встречаются относительно редко в повседневной практике детского травматолога-ортопеда. Вместе с тем, клиничко-лучевая симптоматика деструктивных изменений костной ткани характерна для опухолевых и инфекционно-воспалительных поражений костей. Данная симптоматика не всегда четко указывает на конкретную нозологическую единицу, а дифференциальная диагностика без исследования биологического материала из патологической зоны сложна. Данные утверждения особенно актуальны для поражений грудины, опухолевые процессы которой в 85 % имеют злокачественный характер.

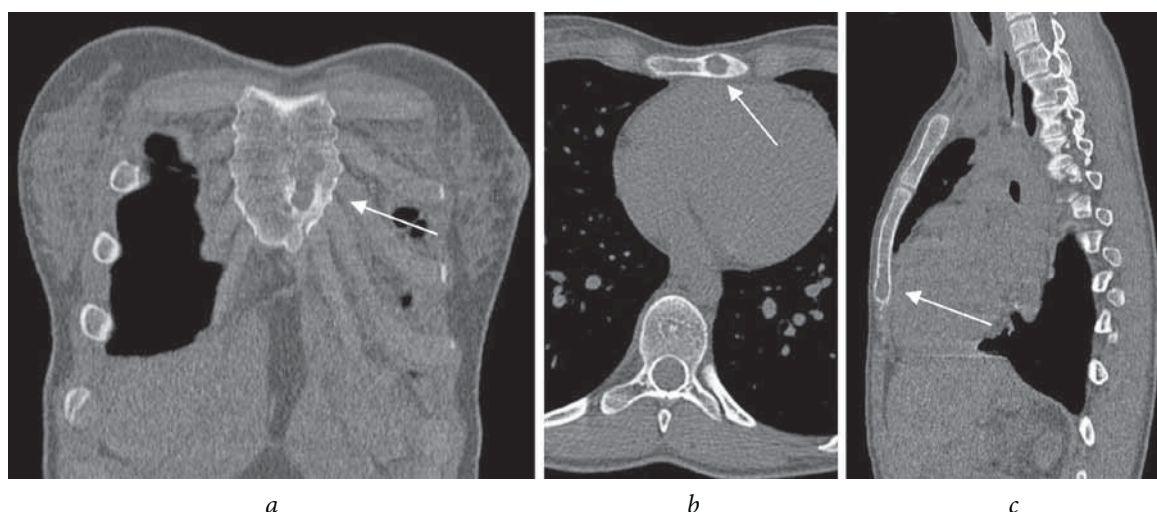
В статье представлены два редких клинических наблюдения детей с первичным злокачественным новообразованием грудины. Проведен анализ клиничко-лучевых и патоморфологических данных. Показана важность ранней гистологической верификации процесса для определения тактики и выбора адекватного лечения. Проведен краткий обзор литературы, посвященной злокачественным опухолям грудины у детей.

**Ключевые слова:** поражение грудины, лимфома Ходжкина, дети, хондросаркома.

Chronic destructive lesions of the skeleton are relatively rarely observed in the clinical setting by pediatric surgeons and orthopedists. This is probably the reason why every such case becomes critical; such cases involve long-term observation, late diagnosis, and often unjustified and repeated surgical interventions. As a rule, the differential series of such destruction is limited to infectious (more often, tuberculosis) and tumoral processes, and although the former occur more frequently, onco-

logical alertness allows early tumor diagnoses, primarily with the use of radiation and morphological methods.

Sternal lesions occupy a prominent position among chronic destructors, the diagnosis of which in tuberculosis lesions remains unclear [1]. Further, cases of malignant manifestation of the primary sternal lesion in children are extremely rare; thus, we have described two such cases here.



**Fig. 1.** Patient P., 17 years old. Computed tomography sections of the chest (bone regimen): *a* – frontal, *b* – axial, and *c* – sagittal. The arrows indicate the cavity of destruction in the body of the sternum

**Aim:** We aimed to present the clinical and radiation signs of manifestation of malignant sternal lesions in children that enable us to reduce the risk of missing out on such a pathology and the principled stance of early morphological verification.

All patients signed voluntary informed consent forms to participate in the study and/or for the use of their personal data.

### Clinical case 1

Patient P., who was 17 years old, was admitted to the clinic with complaints of painless induration in the sternum. According to the patient, the induration was determined during the previous 2 months without visible dynamics. An examination revealed an unchanged general state of the sternum; in the projection of rib 4, on the left, there was an indurated space-occupying lesion without inflammatory changes of the skin. The only remarkable laboratory finding was the increase in the C-reactive protein level to 53 mg/L; the remaining parameters were noted to be within the normal ranges.

The patient was referred to Saint-Petersburg State Research Institute of Phthisiopulmonology on suspicion of tuberculous osteitis of the body of the sternum, based on the results of chest computed tomography that revealed a destructive cavity  $21 \times 11 \times 10$  mm in size in the distal part of the body of the sternum with a clear, partially sclerous contour in the lower part and intact surrounding soft tissues (Fig. 1).

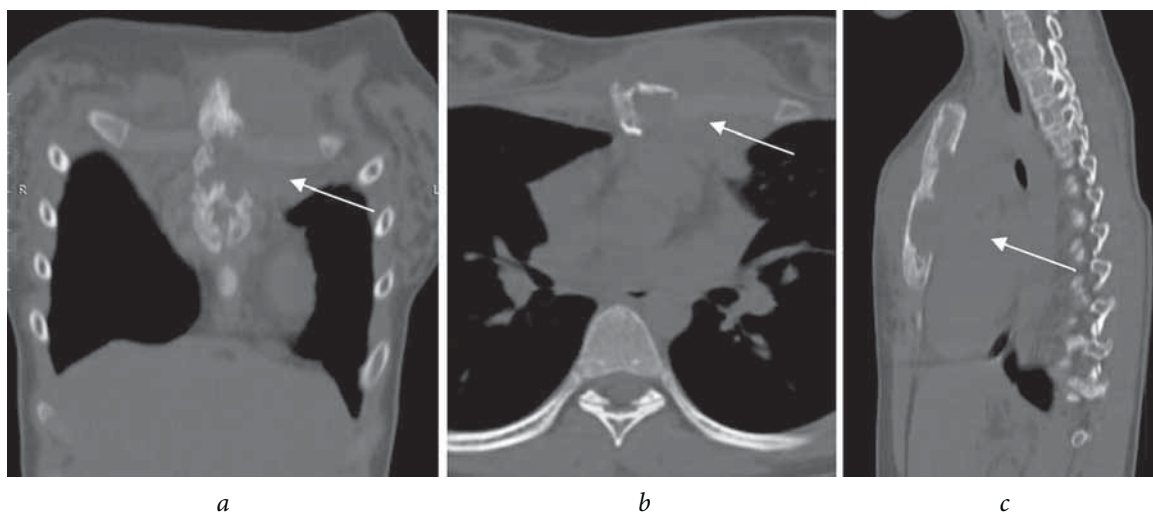
Taking into consideration the clinical and radiological data for verifying the diagnosis, it

was decided that an open resection biopsy of the sternum should be performed. During the surgery (June 30, 2015), a bone cavity with sclerous margins with dimensions of  $30 \times 15$  mm was observed; it spanned across the entire bone thickness, was located to the left of the central line in the lower part of the sternum, and was filled with brown granulating and necrotic tissue. The pathological tissues were completely removed, and the walls of the cavity were treated with bone scrapers. The wound was tightly sutured, layerwise. The postoperative period was uneventful. Wound healing was by the first intention.

The bacteriological study of the surgical material involved inoculation for nonspecific microflora; the molecular, genetic, and cultural studies for *Mycobacterium tuberculosis complex* yielded negative results. According to the histological study of the surgical material, chondrosarcoma of the sternum was suspected; the diagnosis was confirmed during a review by oncomorphologists. Antitumor therapy was commenced in a specialized children's oncology department of a federal research institute. However, at the age of 18 years, the patient was transferred under the supervision of the oncological service to a primary care facility; thus, follow-up was not possible.

### Clinical case 2

Patient G., who was 12 years old, was admitted to the clinic with complaints of a tumor-like lesion with a purulent discharge in the sternum. Based on patient history, the lesion first appeared 6 months previously after trauma due to a fall from the height,

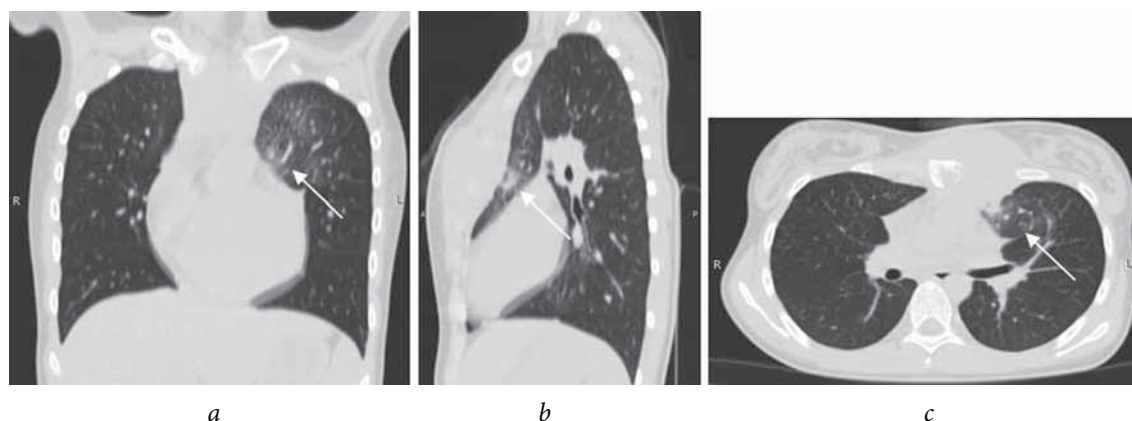


**Fig. 2.** Patient G., 12 years old. Computed tomography sections of the thorax (bone regimen): *a* – frontal, *b* – axial and *c* – sagittal. The arrows indicate the area of the sternum destruction

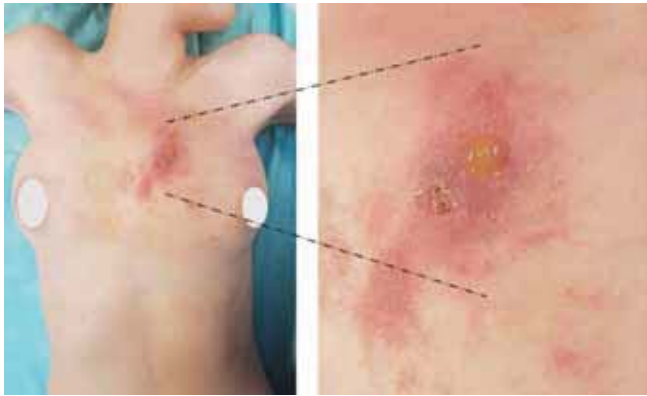but was not accompanied by local inflammatory phenomena. When the patient was presented at the hospital, the situation was considered a chest injury, and local treatment was performed with physiotherapy (high-frequency therapy No. 7) and application of anti-inflammatory ointments (non-steroidal anti-inflammatory drugs [NSAIDs], bepanten, and akriderm) without positive changes. Later, there were periodic temperature rises, hyperemia, and local edema of the tissues in the area of the lesion. During a follow-up visit with the surgeon, a chest abscess was diagnosed; this was opened and drained. As per the description, pus and pathological masses regarded as “caseous” were obtained. According to the result of the cytological examination of a smear, no acid-fast bacteria were detected. A course of nonspecific antibacterial therapy (ceftriaxone, metragyl, amikacin, and gentamycin) was administered, during which a fistula with scanty mucous discharge was formed.

Computed tomography of the thoracic organs revealed destruction in the manubrium and body of the sternum with a parasternal liquid component (Fig. 2) and infiltrative changes in segment 3 of the left lung (Fig. 3).

The patient was hospitalized at the Saint-Petersburg State Research Institute of Phthisiopulmonology with suspected tuberculosis of the sternum. On examination, the pronounced edema was defined in the sternum on the left; the zone of hyperemia was up to 10 cm in diameter with a fistula of up to 1 cm in diameter in the center (Fig. 4) with the presence of scanty seropurulent discharge. The general blood test results revealed an increase in the number of leukocytes ( $15.3 \times 10^9/L$ ) without the formula shift, hemoglobin level of 103 g/L, and erythrocyte sedimentation rate of 46 mm/h. The biochemical blood analysis showed an increase in the C-reactive protein level up to 93.8 mg/L, while the fibrinogen level increased up to 5.312 g/L. Inoculation of the



**Fig. 3.** Patient G., 12 years old. Computed tomograms of the chest (pulmonary regimen): *a* – frontal section, *b* – sagittal section, *c* – axial section. The arrows indicate the zone of infiltrative changes in the  $S_3$ -segment on the left

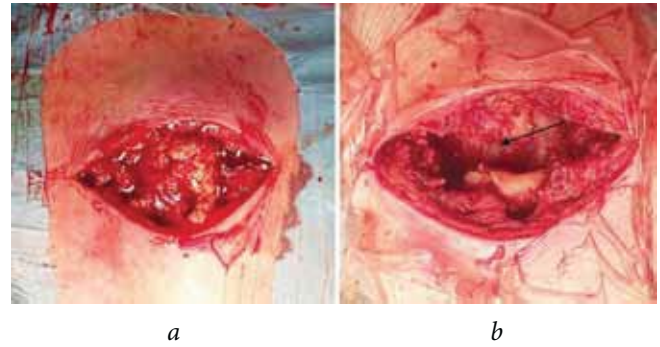


**Fig. 4.** Appearance of patient G., 12 years old: tumor-like lesion in the sternum with fistula

fistula discharge for nonspecific flora did not induce growth.

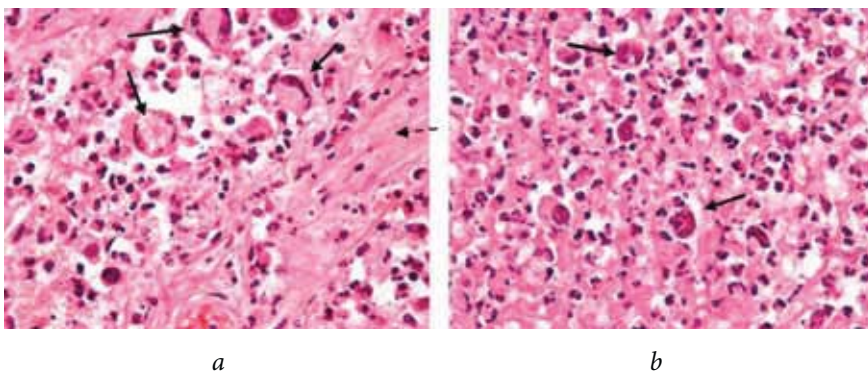
**Fibrobronchoscopy:** On the right, there was a compression stenosis of the middle lobe bronchus of the 1 deg. (up to 1/2 the diameter), mucosal edema. Inoculation of the swab for flora revealed no growth; no mycobacteria were detected on luminescent microscopy.

On December 27, 2016, surgery was performed in the volume of fistula-abscess-necrectomy as a therapeutic and diagnostic step, considering the prevalence of the lesion and its complications. At intervention, the subtotal destruction of the body

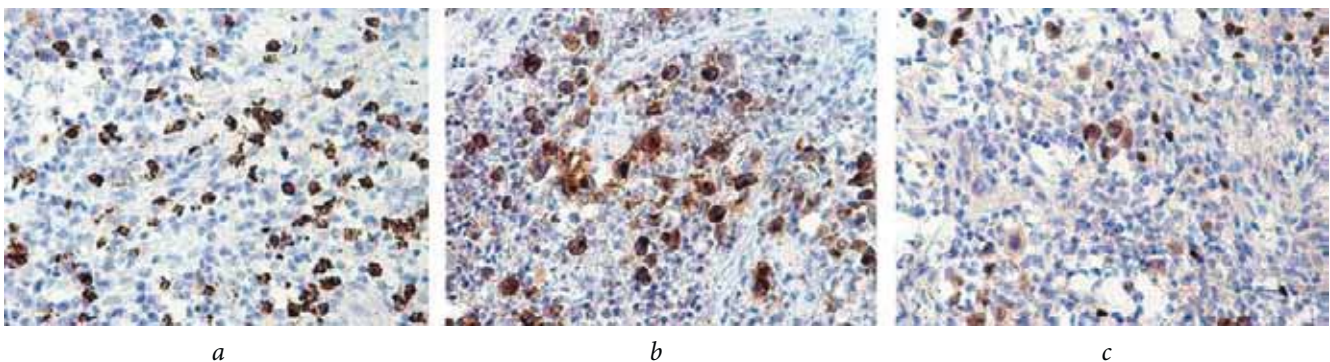


**Fig. 5.** Appearance of the surgical wound: *a* – cavity of destruction filled with granulation and necrotic tissue, *b* – appearance of cavity after osteonecrectomy. The bottom of the cavity (indicated by the arrow) is the pericardium

and the manubrium of the sternum were revealed; the cartilaginous end of rib 3 was located freely; the parasternal pathological tissues contained liquid pus, granulation and necrotic detritus (Fig. 5, *a*). After necrectomy, the cavity dimensions were 100 × 40 × 30 mm, and the bottom of the cavity was the pericardium (Fig. 5, *b*). The wound was sutured under conditions of soft tissue deficiency with their tension; consequently, on post-op day 7, there was partial suture disruption with abundant serous discharge (sterile inoculation). During local treatment, second wound healing was achieved on postoperative day 20.



**Fig. 6.** Morphological preparations (staining with hematoxylin and eosin, ×400): *a, b* – among the vast areas of necrosis (intermittent arrow) – Hodgkin and Reed-Sternberg giant multinucleate cells (solid arrows), lymphocytes, macrophages, and eosinophilic leukocytes



**Fig. 7.** Immunohistochemical study (IHC) of specimens of the patient G., 12 years old: *a* – expression of CD15 (occurs in Hodgkin's disease, with some chronic B-lymphoblastic leukemias); *b* – CD30 expression (marker of Reed-Sternberg cells in Hodgkin's lymphoma); *c* – reference IHC preparation in the classical version of Hodgkin's lymphoma: tumor cells have phenotype of PAX 5<sup>+</sup>, CD45<sup>-</sup>, CD15<sup>+</sup>, and CD30<sup>+</sup>

Bacteriological study of the surgical material for nonspecific microflora (inoculation) and for *Mycobacterium tuberculosis complex* (molecular and genetic study) yielded negative results.

Histological conclusion: "The material is represented as a tumor tissue consisting of large cells, including multinucleate cells, some with light cytoplasm; the bulk of the material is in the form of necrotic tissue, and the lymphoid tissue is practically absent" (Fig. 6).

Immunohistochemical study results (Fig. 7) showed a positive reaction in the tumor on CD30, Pax5, and CD15 and negative reaction on CD45, CD20, CD3, CKAE1/AE3, CD1a, s100, myf4, and desmin. The Ki index was 67%–90%. Conclusion: Hodgkin's lymphoma. The most probable nodular sclerosis NS2 (the material was subtotally necrotic).<sup>1</sup>

The material was reviewed in three independent pathomorphological laboratories with coincidence of the conclusion. The patient was then transferred to the Department of chemotherapy of oncohematological diseases and bone marrow transplantation for children of the Almazov National Medical Research Centre where she is currently undergoing treatment.

## Discussion

Attempts to compare our observations with the literature data proved to be challenging, primarily because very few reports have been published on primary tumor lesions of the sternum in children owing to the rarity of this disease [2]. This was also challenging because in systemic lymphoproliferative diseases such as non-Hodgkin's lymphoma and Hodgkin's lymphoma [3-5], typically observed in this age group, the lesion of the sternum very rarely represents the main manifestation. However, it should be noted that that 0.2%-2% of all human malignant tumors are primary tumors of the thoracic wall. [6], and among all tumors of the sternum, 85% of the lesions are malignant, a considerable proportion of which are chondrosarcomas and malignant lymphomas [7-9].

<sup>1</sup>The histological gradation of nodular sclerosis was proposed by the British Group for the study of lymphoma with division for the type I (NSI) and the type II (NSII). The type NSII is characterized by an increase in the number and degree of atypia of tumor cells, the appearance of signs of syncytial growth. At present, there are no distinct clinical and morphological correlations revealed. The definition of the category of nodular sclerosis is considered expedient in the framework of data accumulation for further studies.

Lack of specificity of the clinical manifestations of the sternum tumors, often absent or moderate pain syndrome, appearance of local hyperemia, and slowly progressing space-occupying lesions increasing to a significant size, together with the rarity of the pathology and the lack of sufficient awareness among doctors (pediatric surgeons and orthopedists) leads to late diagnoses and prolonged, inadequate treatment [2, 5, 10, 11]. Active surgical tactics have two principal advantages:

- The bacteriological study of the surgical material enables the exclusion of the infectious etiology of the process, and morphological study enables tumor verification. Thus, the presence of detritus that appears pathognomonic for a specific tuberculosis process should not lead to the abandonment of these studies. In the second observation, when pathological tissues were regarded as caseous and necrotic were detected, the doctors unreasonably abandoned these studies, leading to a delayed diagnosis of Hodgkin's lymphoma.
- Early medical and diagnostic intervention with limited sternum destruction enables easier resolution and closure of the bone defect, while enhancing the restoration of the carcass of the chest, using different versions of grafting and metal osteosynthesis [8, 12, 13].

The experience of more than 100 surgeries performed on children with destructive lesions of the sternum in our clinic to date indicates that a large majority of them presented as infectious diseases, primarily tuberculous infections. Nevertheless, despite the extreme rarity of tumor lesions, oncological alertness is warranted in each case.

## Conclusion

In our opinion, the clinical observations presented here are interesting from several points of view:

- The clinical and radiation picture of destructive lesions of the sternum has low specificity; thus, the diagnosis based on these data can only be considered preliminary, requiring further clarification.
- Complete bacteriological and morphological studies of the substrate from the bone destruction area should be performed as soon as possible to reduce the diagnostic delay and initiate appropriate, timely treatment.

- In the presence of destruction of the sternum in children, despite the overwhelming predominance of infectious (tuberculous) lesions, oncological alertness should always be present.

### Information on funding and conflict of interest

The authors of the article declare no conflicts of interest.

The study received no external funding.

### References

1. Джанкаева О.Б., Мушкин А.Ю., Ильина Н.А., и др. Клинические особенности и лучевая диагностика туберкулеза грудины у детей // Туберкулез и болезни легких. – 2009. – № 9. – С. 36–40. [Dzhankaeva OB, Mushkin AY, Ilyina NA, et al. The clinical features of sternal tuberculosis and its diagnosis in children. *Tuberkulez i bolezni legkikh*. 2009;(9):36-40. (In Russ.)]
2. Jain A, Gupta N. Primary Hodgkin's Lymphoma of the Sternum: Report of a Case and Review of the Literature. *Journal of clinical and diagnostic research*. 2016;10(6):7-10. doi: 10.7860/jcdr/2016/19666.8065.
3. Егорова Е.К., Габеева Н.Г., Мамонов В.Е. Первичные лимфатические опухоли костей: описание двух случаев и обзор литературы // Онкогематология. – 2008. – № 4. – С. 5–9. [Egorova EK, Gabeeva NG, Mamonov VY, et al. Primary lymphatic tumors of bones: two case reports and a review of literature. *Oncohematology*. 2008;(4):5-9. (In Russ.)]
4. Borg MF, Chowdhury AD, Bhoopal S, Benjamin CS. Bone involvement in Hodgkin's disease. *Australasian Radiology*. 1993;37(1):63-6. doi: 10.1111/j.1440-1673.1993.tb00011.x.
5. Langley CR, Garrett SJ. Primary multifocal osseous Hodgkin's lymphoma. *World Journal of surgical oncology*. 2008;6:34. doi: 10.1186/1477-7819-6-34.
6. Давыдов М.И., Алиев М.Д., и др. Хирургическое лечение злокачественных опухолей грудной стенки // Вестник РОНЦ им. Н.Н. Блохина РАМН. – 2008. – Т. 19. – № 1. – С. 35–38. [Davydov MI, Aliyev MD, Sobolevsky VA, Ilyushin AL. Surgical treatment of malignant tumors of the chest wall. *Journal of N.N. Blokhin Russian Cancer Research Center RAMS*. 2008;19(1):35-38. (In Russ.)]
7. Богдаев Ю.М., Цховребов Е.Е., Беляков С.В. Хирургическое лечение местнораспространенной хондросаркомы грудины с метастазами в подключичных лимфатических узлах // Онкологический журнал. – 2014. – Т. 8. – № 4. – С. 72–80. [Bogdaev JM, Tskhoverbov EE, Belyakov SV, Zhukovets AG. Surgical treatment of locally advanced chondrosarcoma of the sternum with metastases in the subclavian lymph nodes. *Oncological journal*. 2014;8(4):72-80. (In Russ.)]
8. Зацепин С.Т. Опухоли грудины. Оперативное лечение и восстановление каркасности грудной клетки // Международный медицинский журнал – 2003. – № 1. – С. 99–103. [Zatsepin ST. Sternal tumors, surgery and restoration of the chest framework. *International medical journal*. 2003;(1):99-103. (In Russ.)]
9. Toussirot E, Gallinet E, Augé B. Anterior chest wall malignancies. A review of ten cases. *Revue du rhumatism*. English Edition. 1998;65(6):397-405.
10. Graziadio M, Medina N, Amato M, et al. Primary bone lymphoma with multicentric involvement. *Medicina*. 2012;72(5):428-30.
11. Winkel ML, Lequin MH, de Bruyn JR. Self-limiting sternal tumors of childhood (SELSTOC). *Pediatr Blood & Cancer*. 2010;55(1):81-4. doi: 10.1002/pbc.22454.
12. Нохрин А.В., Чеботарь А.В., Особенности хирургического лечения местнораспространенных опухолей грудной стенки с поражением грудины // Вестник Санкт-Петербургского университета. Серия 11. Медицина. – 2012. – Вып. 4. – С. 140–151. [Nokhrin AV, Chebotar AV, Drukin EY, Karaseva NA. Specific features of surgical treatment of locally advanced chest wall tumors with sternal lesion. Series 11 "Medicine" of the Journal "VestnikSPbGU". 2012;(4):140-151. (In Russ.)]
13. Sunil I, Bond SJ, Nagaraj HS. Primitive neuroectodermal tumor of the sternum in a child: resection and reconstruction. *Journal of Pediatric Surgery*. 2006;41(11):5-8. doi: 10.1016/j.jpedsurg.2006.07.013.

### Information about the authors

**Alexey S. Maletin** — MD, children's surgeon of pediatric surgery clinic of the Saint-Petersburg State Research Institute of Phthisiopulmonology. E-mail: maletin\_aleksei@mail.ru.

**Vyacheslav I. Zorin** — MD, PhD, orthopedic and trauma surgeon of pediatric surgery clinic of the Saint-Petersburg State Research Institute of Phthisiopulmonology.

**Valeria A. Gileva** — MD, radiologist of the Saint-Petersburg State Research Institute of Phthisiopulmonology.

**Tatyana A. Novitsky** — MD, PhD, pathologist of the Saint-Petersburg State Research Institute of Phthisiopulmonology.

**Alexander Yu. Mushkin** — MD, PhD, professor, head of extrapulmonary tuberculosis department, head of pediatric surgery clinic of the Saint-Petersburg State Research Institute of Phthisiopulmonology.

**Алексей Сергеевич Малетин** — врач, детский хирург детской хирургической клиники ФГБУ «СПб НИИФ» Минздрава России. E-mail: maletin\_aleksei@mail.ru.

**Вячеслав Иванович Зорин** — канд. мед. наук, врач травматолог-ортопед детской хирургической клиники ФГБУ «СПб НИИФ» Минздрава России.

**Валерия Алексеевна Гилева** — врач-рентгенолог ФГБУ «СПб НИИФ» Минздрава России.

**Татьяна Александровна Новицкая** — канд. мед. наук, врач-патологоанатом ФГБУ «СПб НИИФ» Минздрава России.

**Александр Юрьевич Мушкин** — профессор, руководитель отдела внелегочного туберкулеза, руководитель детской хирургической клиники ФГБУ «СПб НИИФ» Минздрава России.