

## TENS FOR THE SURGICAL MANAGEMENT OF FEMORAL SHAFT FRACTURES IN 6-14 YEARS AGE GROUP CHILDREN

© Mohit Khanna<sup>1</sup>, Jitendra Wadhvani<sup>1</sup>, Amit Batra<sup>1</sup>, Sidharth Yadav<sup>1</sup>, Sarfraz Iman<sup>2</sup>, Sumedha Vashishth<sup>1</sup>

<sup>1</sup> Pt.B.D.S. PGIMS, Rohtak, Haryana, India;

<sup>2</sup> Tezpur Medical College, Assam, India

Received: 02.03.2017

Accepted: 19.05.2017

**Background.** Fracture shaft of femur in pediatric age group is one of the most common leading emergencies. Children in the age group of 6-14 years are treated with either traction, hip spica, flexible/elastic stable retrograde intramedullary nail, or external fixators. We conducted a clinical prospective study on the use of Titanium Elastic Nailing System (TENS) for the treatment of femoral shaft fractures in children.

**Methods.** The prospective study included 45 cases of fresh femoral shaft fractures. The Inclusion Criteria were a) Age group of 6-14 years, b) Recent fracture of femur shaft c) Transverse, short oblique, minimally comminuted fractures.

**Results.** The clinical results were evaluated using Flynn's criteria of scoring as, Excellent in 40 patients (88.89 %), Satisfactory in 5 patients (11.12 %) and poor in none. Radiological criteria for fracture union were assessed by using Anthony et al scale. Nine patients developed bursitis at entry point of the nail. Three patients had superficial infection due to bursitis. Full weight bearing was possible in mean time of 8.7 weeks (range; 7-12 weeks).

**Conclusion.** TENS is very effective in management of paediatric shaft femur fractures in the age group of 6-14 years with advantages of early union, early mobilization and manageable complications.

**Keywords:** Paediatric fractures, Femur, TENS, Flynn's criteria.

## TENS, ИСПОЛЬЗУЕМЫЕ В ХИРУРГИЧЕСКОМ ЛЕЧЕНИИ ПЕРЕЛОМОВ В ОБЛАСТИ ДИАФИЗА БЕДРЕННОЙ КОСТИ У ДЕТЕЙ В ВОЗРАСТЕ 6–14 ЛЕТ

© Мохит Кханна<sup>1</sup>, Джитендра Вадхвани<sup>1</sup>, Амит Батра<sup>1</sup>, Сидхарт Ядав<sup>1</sup>, Сарфраз Иман<sup>2</sup>, Сумедха Вашишт<sup>1</sup>

<sup>1</sup> Pt.B.D.S. PGIMS, Рохтак, Харьяна, Индия;

<sup>2</sup> Медицинский колледж Тезпур, Ассам, Индия

Статья поступила в редакцию: 02.03.2017

Статья принята к печати: 19.05.2017

**Актуальность.** Перелом диафиза бедра один из наиболее распространенных переломов, встречающихся в детском возрасте. Как правило, дети в возрастной группе 6–14 лет лечатся с помощью скелетного вытяжения, интрамедуллярного остеосинтеза либо аппаратами внешней фиксации. Мы провели клинические исследования, в которых использовали только TENS (титановая эластичная стержневая система) при лечении переломом диафиза бедренной кости у детей.

**Методы.** В данное исследование вошли 45 случаев переломов диафиза бедренной кости. Мы использовали следующие критерии: а) возраст 6–14 лет; б) свежие переломы диафиза бедра; в) поперечные, короткие косые, минимальные множественные переломы.

**Результаты.** Клинические результаты были оценены по шкале критериев Flynn: отличные результаты были достигнуты у 40 пациентов (88,89 %), удовлетворительные — у 5 пациентов (11,12 %); плохих результатов не отмечалось. Рентгенологическая оценка сращения переломов проводилась по шкале Antony. У 9 пациентов в области введения TENS возник бурсит. Из этих 9 пациентов у троих зафиксирована инфекция мягких тканей. Полная нагрузка на нижнюю конечность была разрешена в среднем через 8,7 недели (7–12 недель).

**Выводы.** TENS очень эффективны при лечении переломов диафиза бедренной кости в возрасте 6–14 лет. Преимуществами данного метода являются раннее сращение перелома, иммобилизация лишь у немногих пациентов, минимальные осложнения.

**Ключевые слова:** детские переломы, бедренная кость, TENS, критерии Flynn.

## Introduction

Fracture shaft of femur in pediatric age group is one of the most common leading emergencies due to urbanization, improving socioeconomic status and increase in road traffic accident [1]. Although they represent 1–2% of all fractures in the pediatric population, management options are variable with respect to the age, type of injury, associated injuries, the location, and type of the fracture. But surgeon's preference for the management of these fractures has remained an issue for this variation [1,2]. Children younger than six years have high potential for healing and thus they can be managed conservatively with early reduction and traditional POP spica cast [3,4]. Young adolescents more than 15 years old are treated with intramedullary interlocking nail. Children in the age group of 6 to 14 years are treated with either traction, hip spica, flexible/ elastic stable retrograde intramedullary nail, or external fixators in cases of open fractures [5]. The management of the femoral shaft fracture in children of this age group remains a topic of debate [6]. *Titanium Elastic Nailing System* (TENS), as a surgical procedure in pediatric femoral shaft fractures has various advantages such as early union due to repeated micromotion at the fracture site which promotes callus formation, less chance of physeal damage, early mobilization, early weight bearing, small scar, less injury to the surrounding soft tissue, better patient compliance, ease of removal and high patient satisfaction [7-9]. We conducted a clinical prospective study on the use of TENS for the treatment of femoral shaft fractures in children with aim to assess the result and role of TENS in management of femoral shaft fractures in the age group of 6-14 years.

## Materials and methods

the prospective study included 45 cases of fresh femoral shaft fractures (32 males, 13 females) out of which 42 were closed and 3 were compound fractures (two- Grade I compound and one-Grade II compound) which were operated with Titanium Elastic Nail System (TENS) (SYNTHES, Switzerland) between 2013-2016. The Inclusion Criteria were a) Age group of 6-14 years, b) Recent fracture of femur shaft c) Transverse, short oblique, minimally comminuted fractures. The Exclusion Criteria were

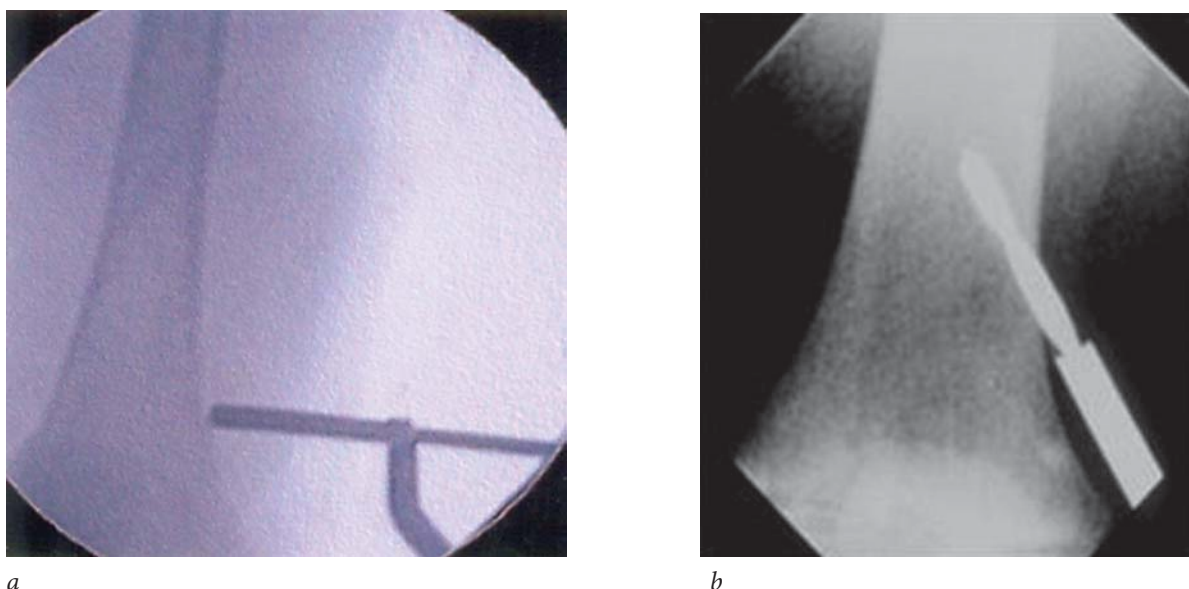
a) Long oblique, long spiral, multifragmentary fractures b) Grade III open fractures, c) Pathological fractures, d) Patient below 6 years and above 14 years of age group. No control group was used.

The mean age was 9.67 years with Right side more commonly affected ( $n = 29$ , 64.4%) than left. Most common mode of injury was road traffic accidents ( $n = 31$ , 68.89%). Associated injuries occurred in 9 patients (20%). 35 patients (77.78%) had fracture of middle third, 6 (13.34%) had fracture of proximal third and 4 (8.89%) had fracture of distal third of femoral shaft. 31 patients (68.89%) had transverse fracture, 12 (26.67%) had short oblique fracture and 2 (4.45%) had minimally comminuted fracture. Majority of patients ( $n = 41$ , 91.1%) underwent surgery within one week and rest ( $n = 4$ , 8.89%) were operated within two weeks of trauma. All patients were evaluated and treated for life and limb threatening injuries. Displaced fractures were immobilized using skin traction with Thomas splint till the date of surgery. In open fractures, local irrigation was done with normal saline and povidone-iodine solution and immediate I.V. antibiotics were injected after negative skin test.

## Surgical technique

Before planning closed titanium elastic nailing, radiograph of the whole length of the bone was carefully evaluated both in AP and lateral view. Careful assessment of fracture geometry and width of the medullary canal was done. All patients were prepared for surgery under general anaesthesia. The standard technique of titanium elastic nailing in femur is Retrograde (ascending). The position of the patient is supine on the fracture table with a traction boot. Perineal post was well padded to avoid any injury to the nearby structures. Image intensifier was positioned on the affected femur for AP and lateral views of the leg from knee to hip. Image intensifier was used to locate the placement of skin incision for making entry hole in the metaphysis by viewing distal femur in AP and lateral planes to insert the nails in retrograde fashion. The entry point was 2.5-3 cm above the physis. The entry points were at the same level both medially and laterally.

Two longitudinal incisions were made on the lateral and medial aspect of the distal femur, starting 3 cm above the physis and extending distally for



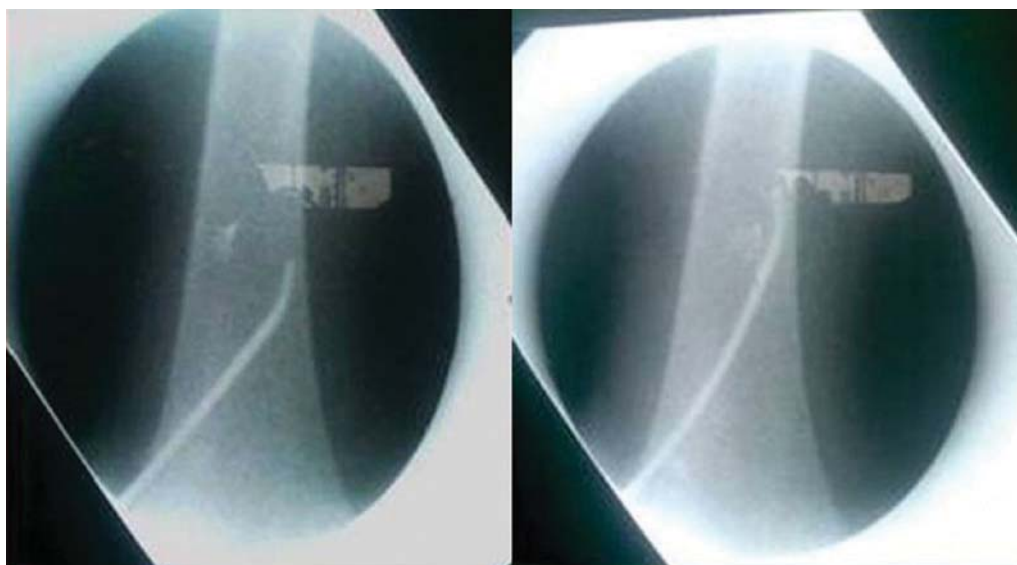
**Fig. 1.** *a* — Identification of nail entry site in image intensifier 2.5-3 cm above the physis; *b* — Nail entry made with drill bit at an oblique angle of 45°

2.5 cm. Fascia was dissected along the line of incision and blunt dissection was carried out till the periosteum was reached. Medullary canal was opened using an awl or drill bit. The next largest drill bit size relative to the diameter of nail was selected. The drill bit was started perpendicular to the bone surface, 2.5 cm to 3.0 cm proximal to the physis then slowly angulated to 45° in relation to axis of shaft and 10° anteriorly (Fig. 1).

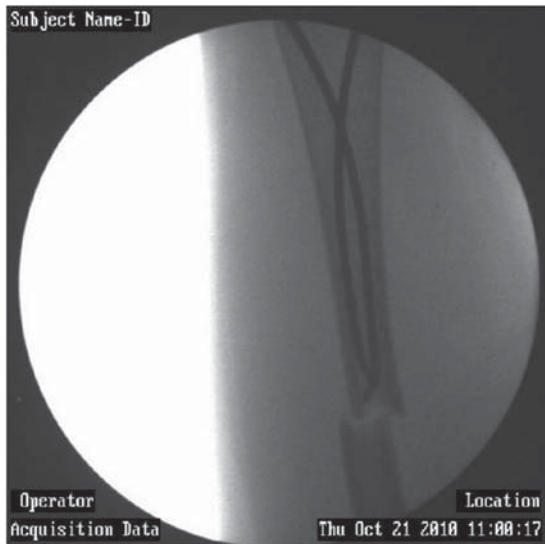
Then the drill bit was advanced at this angle until it reaches the medullary canal. The two nails of the same diameter were selected so that the bending forces are equal, avoiding malalignment. The proper nail diameter should not be more than

forty percent (40%) of the width of the canal [10]. Hence both the nails of equal size should be filling 80% of the isthmus region of the medullary canal [10]. The opening was made slightly larger than the selected nail diameter. The traumatic tip is formed as a skip, which guarantees better gliding inside the cortex.

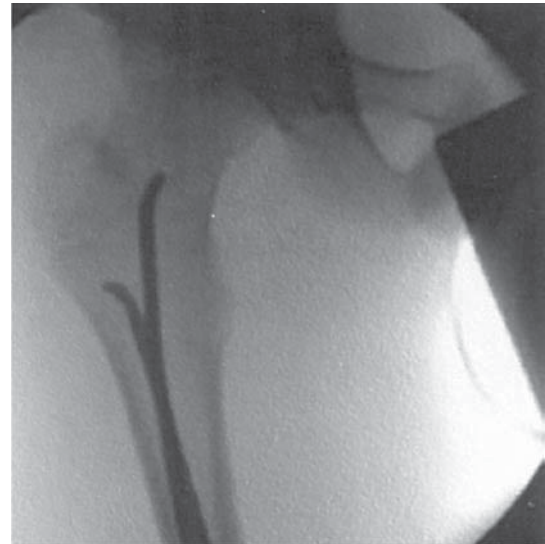Both the nails were contoured into a bow shape by hand with the nail tip positioning to the concave side of the bowed nail. Whole length of the nail was precontoured so that apex of the bow rested at the level of fracture site. This shape allows the nail to generate optimal resistance to malaligning forces. The bow in each nail should be similar for



**Fig. 2.** Nail tip made convex to glance off the far cortex



**Fig. 3.** Both nails advanced to the fracture site in divergent manner superiorly



**Fig. 4.** Divergent nails in proximal femur with one extending to neck and other kept distal to greater trochanteric physis

a balanced effect. Contouring was done to 3 times the diameter of the medullary canal. After removing the awl or drill bit, the entry point was located and maintained with finger tip. The first nail to be introduced was on the side where the fragment was overlapped, so that fracture could be better reduced. Using fluoroscopy, the nail tip was aligned so that convex side of the nail glanced off the far cortex (Fig 2).

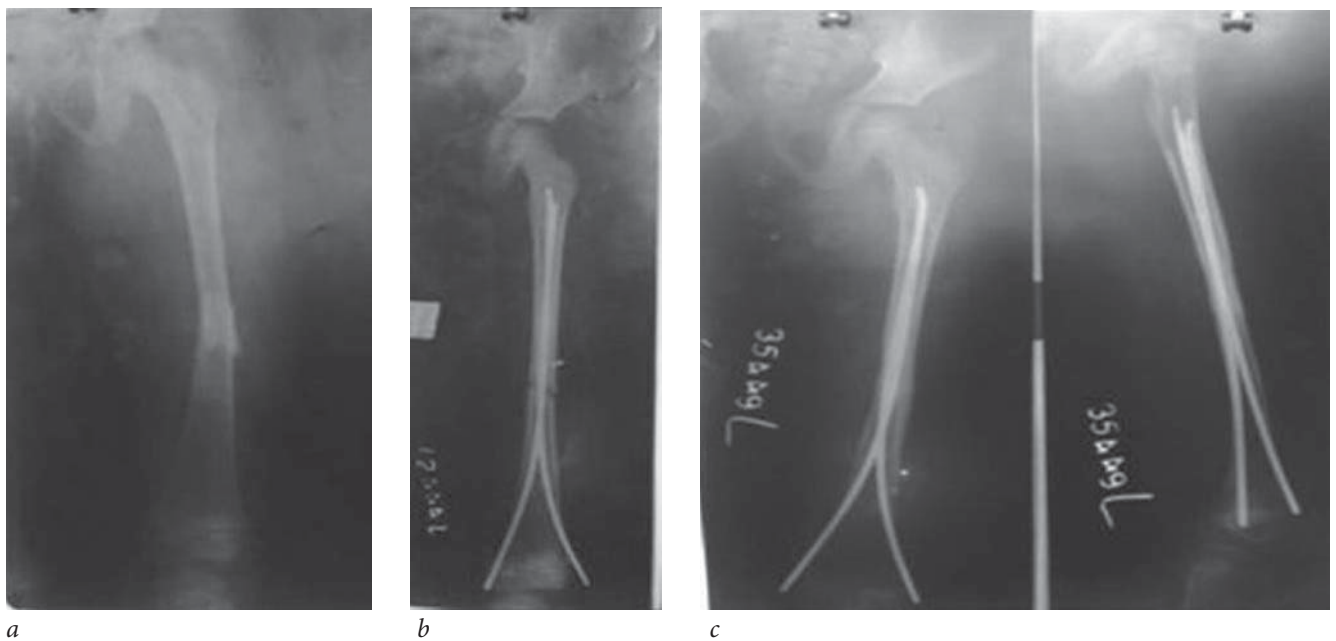
The nail was advanced by hand as far as possible. In the similar manner second nail was inserted, so that both nail diverged superiorly and advanced to the level of fracture site (Fig. 3).

At this point reduction was done under fluoroscopic guidance by using traction or external manipulation using small F- tool was carried out or leverage was done by one nail. Fracture was reduced closed in almost all the cases. Two cases required open reduction because of soft tissue interposition. Reduction was held in position and the nail which was easy to pass across the fracture site was driven approximately 2-3 cm beyond the fracture site under the guidance of image intensifier. Similarly second nail was driven across the fracture site. The traction was released at this point, so that distraction disappeared and the fracture end collapsed. Then nails were advanced till the nail tips get anchored in the metaphysis. One nail was driven towards the neck and the other was towards greater trochanter till 1 cm distal to the physis (Fig. 4).

The length of nail was cut to final length intraoperatively.

The nails were pulled back approximately 2 cm and cut to the desired length using jumbo cutting plier, leaving at least 1-2 cm outside the entry hole. The nails were again driven back to its original position. Position of the nail was verified using fluoroscopy regarding the divergence, sitting of nail tips and apex of bows of the nails also the nail ends. Wound closure was done in layers and dressing done. Before waking the patient up, the knee was bent to 90° to sink the nail into the fibers of vastus medialis and vastus lateralis and to avoid stiffness of the knee joint.

Patients were not immobilized routinely. But in three cases, due to instability of fracture because of comminution, and spiral fracture pattern, and inadequate reduction (varus and valgus malalignment), immobilization was done. Operated leg was elevated and rested on a pillow. Post-operative radiographs were taken to assess the reduction of fracture, nail tips and nail ends. Static quadriceps exercises were advised as soon as post-operative pain and edema subsided which was usually on second and third post-operative day. On 5<sup>th</sup> post op day active knee extension and non weight bearing crutch walking was encouraged. Partial weight bearing was started at 4 weeks post operatively and full weight bearing was allowed at 8 weeks for transverse fracture and at 8 weeks for oblique and minimally comminuted fractures once external callus was visible on radiograph at the fracture site (Fig 5, 6).



**Fig. 5.** *a* — Anteroposterior Radiograph of left thigh of 7 years old girl showing fracture of femoral shaft in middle one third region; *b* — Immediate post operative anteroposterior radiograph of left thigh of the same patient showing 2 Titanium elastic nails of same size inserted in retrograde manner in femoral shaft; *c* — Anteroposterior and lateral radiographs of left thigh of the same patient showing completely healed femoral shaft fracture with callus bridging the fracture site at 7 months follow up



**Fig. 6.** Clinical photographs of the patient showing full range of motion of both lower limbs at final follow up

Follow up every 4 weeks – till consolidation of fractures thereafter every 2 months. Parameters studied were clinical and radiological features of union, mal-alignment, range of motion of the affected side knee, limb length discrepancy and

any other complications found during the study. Nails were removed 6-8 months post surgery when fracture line was no longer visible on x-ray provided patients were asymptomatic.

## Results

The diameter of nail chosen varied from 2-4 mm. The diameter of nail chosen varied according to Flynn et al's formula [10] (*Diameter of nail = width of narrowest point of medullary canal x 0.4 mm*). All fractures were stabilized with two titanium elastic nails of same diameter. Length of nail is 45 cm, which was cut to required length accordingly during operation. The mean duration of surgery was 36 minutes (range; 25-60 min). Postoperative immobilization was used in three patients (hip spica in one and pop long leg slab in two patients). The period of hospital stay was ranged from 5-18 days depending on patient condition, fixation of the fracture, associated injuries and complication. The average duration of hospital stay was 9.15 days. All patients were mobilized as soon as post operative pain and edema subsided. Isometric exercises were begun as soon as possible. Between 3rd and 5th

day active knee extension was encouraged. Full weight bearing was possible in mean time of 8.7 weeks (range; 7-12 weeks). Two patients had valgus angulation (10° and 15°) and one patient had varus angulation (12°) postoperatively and were due to inadequate reduction and instability of fracture pattern. But these malalignment were remodelled with time and mobility of the patient leading to favourable outcome. Limb length discrepancy of 1-2 cm was found in two patients. All patients achieved full range of motion by 8 weeks with average of 7.4 weeks. Absence of pain on walking was the clinical indicator of union. The **clinical results were evaluated using Flynn's criteria of scoring** [11] (Table 1).

Results were Excellent in 40 patients (88.89%), Satisfactory in 5 patients (11.12%) and poor in none of the patients. Radiological criteria for fracture union were assessed by using Anthony et al scale [12] of grading callus formation (Table 2).

Table 1

Assessment of results according to Flynn et al's Scoring Criteria

Criteria	Excellent	Satisfactory	Poor
Limb length discrepancy	< 1 cm	1-2 cm	> 2 cm
Malalignment (degree)	<5°	5°-10°	> 10°
Pain	Absent	Absent	Present
Complication	Absent	Mild	Major complication and /or extended period of resolvable morbidity
Number of Patients (n = 45)	n = 40	n = 5	n = 0

Table 2

Anthony et al scale for grading callus formation

<b>Grade 0</b>	No identifiable fracture healing
<b>Grade 1</b>	Primary bone healing with little or no periosteal new bone formation
<b>Grade 2</b>	Periosteal new bone formation on two sides of the femur
<b>Grade 3</b>	Periosteal new bone formation on three or four sides of the femur

Table 3

Complication in the study

COMPLICATION	No of Cases (n = 45)
Entry site irritation/bursitis	9
Deep infection	0
Superficial infection	3
Limb length discrepancy 1-2 cm	2
Varus/Valgus angulation	3

The Radiological union was achieved in all the cases in 8.4 weeks (range; 7-11 weeks). Nine patients developed bursitis at entry point of the nail. Three

patients had superficial infection due to bursitis which resolved on treatment. None of the patient developed deep infection or any other complication (Table 3).

Nails were removed after an average of 7.5 month (range; 6-8 months). No complication occurred in nail removal surgery. Mean period of follow up was 72 weeks.

## Discussion

Paediatric femoral shaft fractures have remained a matter of debate since long between orthopaedic surgeons especially treatment in the age group of 6-14 years. Over the past few decades, management of pediatric femoral fractures has shifted more towards operative intervention because of quicker recovery, shorter rehabilitation period, less immobilization, and less psychological impact to the children [5]. Children in the age group of 6 to 14 years are treated with either traction, hip spica, flexible/elastic stable retrograde intramedullary nail, compression plates or external fixators in cases of open fractures. The classical POP spica cast works good in children younger than 6 years [5]. Plate osteosynthesis is still widely used. It is associated with a large exposure, relatively longer duration of immobilization and the risks of delayed union, infection and a large dissection for plate removal [13, 14]. Interlocking nail has been widely used in skeletally matured children. But avascular necrosis of femoral head, coxa valga are the reported complications in skeletally immature patients with use of interlocking nails [15,16]. External fixation has been associated with problems of pin track infection and re-fractures through the pin tracks, but has advantage of good stability and early mobilization [17,18]. TENS (Titanium Elastic Nail System) seems advantageous over other surgical methods specially in the age group of 6-14 years because it is a load-sharing internal splint that does not violate open physis, maintains alignment and allows early mobilization. Micromotion conferred by TENS is an advantageous factor for the fracture as it promotes external bridging callus across the fracture site. The periosteum is not disturbed as compared to plate osteosynthesis and being a closed procedure, thereby less risk of infection. It also combines the advantages of titanium such as more strength, light weight, corrosion resistance and MRI compatibility. Similar to our study flexible nailing for paediatric femoral shaft fractures has yielded predictably

excellent union across the literature. Ligier et al, treated 123 femoral shaft fractures with elastic stable intramedullary nail [19]. Flynn et al studied the outcomes of 49 fractures treated with TENS found it to be advantageous over hip spica in treatment of femoral shaft fractures in children [20]. All fractures united with good final outcome. Similarly, Narayanan et al. found good outcome in 79 femoral fractures stabilized with TEN [8]. Fracture geometry plays an important role in the management of paediatric femoral shaft fractures, Transverse, short oblique and minimally comminuted fractures are suitable for TEN [11]. Titanium elastic nail is incapable of providing adequate stability in comminuted long oblique or spiral fractures and some other alternative apart from TENS should be considered in such cases.

Malreduction was the cause of malalignment postoperatively in three patients which resolved due to remodeling with time and mobility of the patient. Malalignments which do not remodel should be corrected if significant to cause clinical symptoms or cosmetic deformity after union of the fracture. We did not require any corrective surgery in our series. Postoperative immobilisation has been variably used after internal fixation with flexible nails. Ligier et al [19] did not use any postoperative immobilisation in contrast to selective use of spica cast or knee immobilisers by Flynn et al [11] (41/58). We used postoperative immobilisation in 3 patients only since adequate fracture stability was achieved in all other cases. A frequent complication in this study was skin irritation and bursitis at nail insertion site leading to limited range of knee movement which resolved completely after nail removal. Similarly other studies have also reported this complication [8]. We found that bursitis and skin irritation at entry site was significantly associated with long and prominent nail end. Limb length discrepancy was a frequent but clinically insignificant complication as most fractured limbs were within 1 cm in length of the contralateral normal limb. However, shortening of > 1 cm was observed in 4 patients. We did not find shortening of > 2 cm in any of our patients. Although lesser degree of limb length discrepancy is fairly common, however most published articles have reported very less frequency of clinically significant shortening [8,11]. Overall complication rate was 37.78% (17 patients) in our series.

Our results are compatible with 100% union, no implant failure or refracture after nail removal. The most common complication is entry site irritation and pain which can be minimized by advancing the nail ends till they lie against the supracondylar flare of the femur. Nail removal is usually needed for this reason but should not be done till fracture is solidly united to prevent refracture. The limitations of the study were absence of any control group and no comparison from the other treatment options available. No cases lost to follow up builds the strength of our study.

## Conclusion

TENS (Titanium Elastic Nailing System) is very effective in management of paediatric shaft femur fractures in the age group of 6-14 years with advantages of early union, early mobilization and minimum complications. The complications can be avoided by strictly following the surgical technique. It overall yields excellent results in majority of the patients.

## Ethical and humane considerations

All patients gave written informed consent to be included in this study, and the study was authorized by the local ethical committee carried out in accordance with the World Medical Association Declaration of Helsinki.

## Conflict of interests

The authors declare that there is no conflict of interests regarding the publication of this paper. No financial support was taken from any organization.

## References

- Loder RT, O'Donnel PW, Finberg JR. Epidemiology and mechanism of femur fracture in children. *J Pediatr Orthop.* 2006;26(5):561-566. doi: 10.1097/01.bpo.0000230335.19029.ab.
- Beaty JH. Operative treatment of femoral shaft fractures in children and adolescents. *Clin Orthop Relat Res.* 2005;434:114-22. doi: 10.1097/01.blo.0000163463.05141.1c.
- Buckley SL. Current trends in the treatment of femoral shaft fractures in children and adolescents. *Clin Orthop Relat Res.* 1997;338:60-73. doi: 10.1097/00003086-199705000-00009.
- Gwyn DT, Olney BW, Dart BR, Czuwala PJ. Rotational control of various pediatric femur fractures stabilized with Titanium Elastic Nails. *J Pediatr Orthop.* 2004;24:172-7. doi: 10.1097/00004694-200403000-00007.
- Canale ST. Fracture and dislocation in children. In: Canale ST, Beaty JH, et al. *Campbell's Operative Orthopaedics.* 11th ed. Philadelphia: Mosby; 2007: 1651-1661.
- Lee YH, Lim KB, Gao GX, et al. Traction and spica casting for closed femoral shaft fractures in children. *J Orthop Surg (Hong Kong).* 2007;15(1):37-40. doi: 10.1177/230949900701500109.
- Flynn JM, Skaggs DL, Sponseller PD, et al. The operative management of pediatric fractures of the lower extremity. *J Bone Joint Surg Am.* 2002;84(12):2288-300. doi: 10.2106/00004623-200212000-00025.
- Narayanan UG, Hyman JE, Wainwright AM, et al. Complications of elastic stable intramedullary nail fixation of pediatric femoral fractures and How to avoid them. *J Pediatr Orthop.* 2004;24(4):363-9. doi: 10.1097/01241398-200407000-00004.
- Bhaskar A. Treatment of long bone fractures in children by flexible titanium nails. *Indian J Orthop.* 2005;39(3):166-8. doi:10.4103/0019-5413.36715.
- Flynn JM, Skaggs DL, Sponseller PD, et al. The surgical management of pediatric fractures of the lower extremity. *Instr Course Lect.* 2003;52:647-59.
- Flynn JM, Hresko T, Reynolds RA, et al. Titanium elastic nails for pediatric femur fractures: a multicenter study of early results with analysis of complications. *J Pediatr Orthop.* 2001;21(1):4-8. doi: 10.1097/01241398-200101000-00003.
- Stans AA, Morrissey RT, Renwick SE. Femoral shaft fracture treatment in patients age 6 to 16 years. *J Pediatr Orthop.* 1999;19(2):222-228. doi: 10.1097/00004694-199903000-00017.
- Reeves RB, Ballard RI, Hughes JL, Jackson. Internal fixation versus traction and casting of adolescent femoral shaft fractures. *J Pediatr Orthop.* 1990;10(5):592-5. doi: 10.1097/01241398-199009000-00004.
- Ward WT, Levy J, Kaye A. Compression plating for child and adolescent femur fractures. *J Paediatr Orthop.* 1992;12(5):626-32. doi: 10.1097/01241398-199212050-00012.
- Beaty JH, Austin SM, Warner WC, et al. Interlocking intramedullary nailing of femoral-shaft fractures in adolescents: Preliminary results and complications. *J Pediatr Orthop.* 1994;14(2):178-83. doi: 10.1097/01241398-199403000-00009.
- Letts M, Jarvis J, Lawton L, Davidson D. Complications of rigid intramedullary rodding of femoral shaft fractures in children. *J Trauma.* 2002;52(3):504-16. doi: 10.1097/00005373-200203000-00015.
- Aronson J, Tursky EA. External fixation of femur fractures in children. *J Pediatr Orthop.* 1992;12(2):157-63. doi: 10.1097/01241398-199203000-00003.



18. Krettek C, Haas N, Walker J, Tschorne H. Treatment of femoral shaft fractures in children by external fixation. *Injury*. 1991;22(4):263-66. doi: 10.1016/0020-1383(91)90002-v.
19. Ligier JN, Metaizeau JP, Prevot J, Lascombes P. Elastic stable intramedullary nailing of femoral shaft fractures in children. *J Bone Joint Surg Br*. 1988;70:74-7.
20. Flynn JM, Luedtke LM, Theodore J, et al. Comparison of titanium elastic nails with traction and a spica cast to treat femoral fractures in children. *J Bone Joint Surg Am*. 2004;86(4):770-7. doi: 10.2106/00004623-200404000-00015.

---

### *Information about the authors*

---

**Mohit Khanna** — Assistant Professor, Department of Orthopaedics, Pt.B.D.S. PGIMS, Rohtak, Haryana, India.

**Jitendra Wadhvani** — Senior Resident, Department of Orthopaedics, Pt.B.D.S. PGIMS, Rohtak, Haryana, India. E-mail: drjitendra28.03@gmail.com

**Amit Batra** — Associate Professor, Department of Orthopaedics, Pt.B.D.S. PGIMS, Rohtak, Haryana, India.

**Sidharth Yadav** — Senior Resident, Department of Orthopaedics, Pt.B.D.S. PGIMS, Rohtak, Haryana, India.

**Sarfraz Iman** — Assistant Professor, Department of Orthopaedics, Tezpur Medical College, Assam, India.

**Sumedha Vashishth** — Junior Resident, Department of Anaesthesia, Pt.B.D.S. PGIMS, Rohtak, Haryana, India.

**Мохит Кханна** — доцент отделения ортопедии, Pt.B.D.S. PGIMS, Рохтак, Харьяна, Индия.

**Джитендра Вадхвани** — старший ординатор отделения ортопедии, Pt.B.D.S. PGIMS, Рохтак, Харьяна, Индия. E-mail: drjitendra28.03@gmail.com

**Амит Батра** — доцент отделения ортопедии, Pt.B.D.S. PGIMS, Рохтак, Харьяна, Индия.

**Сидхарт Ядав** — старший ординатор отделения ортопедии, Pt.B.D.S. PGIMS, Рохтак, Харьяна, Индия.

**Сарфраз Иман** — доцент отделения ортопедии, медицинский колледж Тезпур, Ассам, Индия.

**Сумедха Вашишт** — младший ординатор отделения анестезиологии, Pt.B.D.S. PGIMS, Рохтак, Харьяна, Индия.