

## ERRORS OF DIAGNOSIS AND THE INITIATION OF CONSERVATIVE TREATMENT IN CHILDREN WITH CONGENITAL HIP DISLOCATION

© *I.Yu. Pozdnikin, V.E. Baskov, S.Yu. Voloshin, D.B. Barsukov, A.I. Krasnov, M.S. Poznovich, P.I. Bortulev, T.V. Baskaeva, O.V. Bortuleva*

The Turner Scientific Research Institute for Children's Orthopedics, Saint Petersburg, Russia

Received: 30.03.2017

Accepted: 20.05.2017

**Background.** Dysplasia of hip joints and congenital hip dislocation are common impaired developments in newborns. Currently, there are common cases of late detection of the disease, failure in treatment, and development of complications, which is not adequately reflected in the modern literature.

**Aim of the study.** This study aimed to identify the most common errors during diagnosis and treatment onset in children with congenital hip dislocation during the first year of life.

**Materials and methods.** This study is based on a retrospective analysis of the anamnesis history, which is the history of diagnosis and previous treatment, as well as on clinical, sonographic, radiation, and magnetic resonance examinations of 250 patients aged 5 months to 2 years. The patients were admitted to the specialized Department of Hip Joint Pathology of the Turner Scientific and Research Institute for Children's Orthopedics with a diagnosis of congenital hip dislocation between 2005 and 2015.

**Results and Conclusion.** The most common causes of errors during diagnosis of congenital hip dislocation in children are the lack of examination of the newborn by an orthopedist in the maternity hospital and sonographic screening as well as an error in its implementation. At the onset of treatment, the use of structures that did not provide the optimal position for repositioning the femoral head was noted as well as late indications for primary surgical treatment in cases of unreducible hips.

**Keywords:** congenital hip dislocation, dysplasia of hip joints, diagnosis, treatment.

## ОШИБКИ ДИАГНОСТИКИ И НАЧАЛА КОНСЕРВАТИВНОГО ЛЕЧЕНИЯ ДЕТЕЙ С ВРОЖДЕННЫМ ВЫВИХОМ БЕДРА

© *И.Ю. Поздникин, В.Е. Басков, С.Ю. Волошин, Д.Б. Барсуков, А.И. Краснов, М.С. Познович, П.И. Бортулёв, Т.В. Баскаева, О.В. Бортулёва*

ФГБУ «НИДОИ им. Г.И. Турнера» Минздрава России, Санкт-Петербург

Статья поступила в редакцию: 30.03.2017

Статья принята к печати: 20.05.2017

**Актуальность.** Дисплазия тазобедренных суставов и врожденный вывих бедра — часто встречающаяся аномалия развития у новорожденных. По-прежнему не редки случаи позднего выявления заболевания, неудачи в лечении и развитие осложнений, что не находит должного отражения в современной литературе.

**Цель исследования** — выявить наиболее распространенные ошибки на этапах диагностики и начала лечения детей первого года жизни с врожденным вывихом бедра.

**Материалы и методы.** Работа основана на ретроспективном анализе данных анамнеза: истории диагностики и предшествующего лечения, а также клинического, сонографического, лучевого, магнитно-резонансного методов обследования 250 пациентов от 5 мес. до 2 лет, поступивших в специализированное отделение патологии тазобедренного сустава ФГБУ «НИДОИ им. Г.И. Турнера» с диагнозом «врожденный вывих бедра» в 2005–2015 гг.

**Результаты.** Наиболее распространенными причинами ошибок на этапе диагностики врожденного вывиха бедра у детей являются отсутствие осмотра новорожденного ортопедом в роддоме и проведения сонографического скрининга, а также погрешности в его выполнении. При начале лечения отмечалось использование конструкций, не обеспечивающих оптимальное положение для вправления головки бедра, а также поздняя установка показаний к первичному хирургическому лечению в случаях невраваемых вывихов бедра.

**Ключевые слова:** врожденный вывих бедра, дисплазия тазобедренных суставов, диагностика, лечение.

## Introduction

Dysplasia of hip joints (DHJ) and congenital hip dislocation (CHD) are common development abnormalities in newborns and two of the main causes of early coxarthrosis and disability of patients [1-4].

DHJ includes a wide range of anatomical changes that arise from disorder of normal hip development during embryonic, intrauterine, and infant growth periods [5-7]. The incidence rate varies from 1.7 to 35 cases per 1000 newborns and depends, *inter alia*, on age at the time of the study and application of diagnostic methods. It is believed that the “true” prevalence of DHJ requiring treatment is 5–10 cases per 1000 newborns [8-10].

The problem of diagnosis and treatment of children with DHJ and CHD is given much attention in modern scientific literature. It is indisputable that long-term treatment success for children with hip dislocation depends on early diagnosis of the condition and maintenance of concentric repositioning in the first weeks and months of a child's life [4, 10-16].

Nevertheless, cases of late pathology detection, treatment failure, and complication development are still common, which, however, is not adequately reflected in modern literature.

**The aim of the study** was to identify the causes of the most common errors at the stages of diagnosis and treatment initiation in children with CHD in the first year of life.

## Materials and methods

The work was based on a retrospective analysis of the history data: the history of diagnosis and previous treatment as well as clinical, sonographic, radiation, and magnetic resonance methods of examination of 250 patients ranging in age from 5 months to 2 years. These patients were admitted in the specialized department of the hip joint pathology of the Turner Scientific and Research Institute for Children's Orthopedics with CHD diagnosis in 2005–2015 from various regions of the Russian Federation. All patients required surgical treatment. In a detailed analysis of the history and previous examination of children as well as our own intraoperative data, we tried to establish the factors that resulted from the failure of conservative measures at the prehospital stage.

## Results and discussion

For the convenience of presenting the material, we considered the data obtained in accordance with the order of scheduled orthopedic examinations of a child in the first year of life.

### 1. The neonatal period

In typical “dysplastic” hip dislocation cases, the main diagnostic problems at this stage were the following. Early detection of hip joint pathology in children in the first month of life was often performed not by orthopedists but by neonatologists and pediatricians, who are not always sufficiently aware of the problem's complexity. In the maternity hospital, only 5 (2%) children were examined by an orthopedic surgeon. When performing a planned examination of a newborn to exclude orthopedic pathology, insufficient attention was paid to children from the risk groups. According to modern data, the most significant factors that cause an increased risk of DHJ and CHD are burdened familial history (hip joint disorders in close relatives), pelvic presentation, female sex, first child, large fetus (weight >4000 g), hypamnion, toxicosis, intrauterine growth retardation, symptomatic torticollis, and clubfoot [5, 17-23].

Clinical examination of the hip joints of a newborn was often not performed or was limited only to the assessment of hip abduction (75%). Newborns with a suspicion of instability or dislocation of the hip, even with a clear clinical symptom in the form of a “click” symptom and restriction of hip abduction (56 children, 22.4%), were sent to a scheduled consultation with an orthopedist or a surgeon with a diagnosis of DHJ, not at once but at the age of 1 or even 3 months of life. That is, there was a loss of time, a tactical error, because treatment in this “golden period” was not performed.

The most significant clinical signs of the condition that can be detected in a child in the neonatal period are positive results of Ortolani and Barlow tests. In this case, it was precisely the provocative Barlow maneuver that helped to assess the stability of the femoral head position in the cavity [24]. As a rule, the limitation and asymmetry of hip abduction, as well as relative shortening of the limb and excessive rotation of the hips, prevail only later. Even in the absence of clinical symptoms in

children with a combination of several risk factors for DHJ and CHD, we considered it necessary to perform a repeated one-two-time examination (ultrasound, X-ray) of the hip joints in the first half year of life. Diagnosis of high hip dislocation cases present at the time of birth, as a rule, does not cause difficulties, given the characteristic clinical pattern of the condition.

## 2. Diagnosis and treatment in the period of 1–3 months

The clinical picture in a child with CHD during this period becomes clearer: the restriction of hip abduction, limb shortening, and increase in internal and/or external hip rotation.

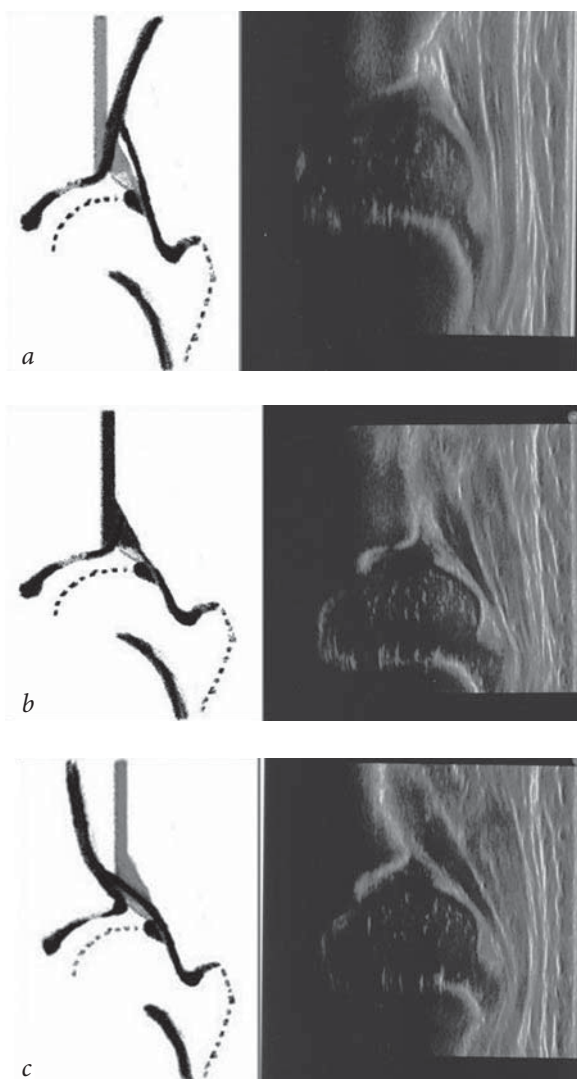
In recent years, due to the propagation of early sonographic screening of the hip joints, it became

possible to diagnose CHD in a timely and reliable manner. Sonographic examination together with a clinical examination in the child in the first weeks of life with CHD enables, in most cases, identification of pathology and start early treatment [25-30]. Sonography according to the method by R. Graf (1984) is an accurate method of diagnostics, only if the author's recommended technique of the study and evaluation of the results were strictly observed.

In our study, 56 children (22.4%) did not undergo a sonographic screening examination. Common errors in diagnosis in this age group were the errors in performing a planned ultrasound examination (47%). In estimation of the presented sonograms, it was found that errors in the examination technique were most often noted as incorrect placement and position of the sensor, such as inclination in the ventrodorsal or craniocaudal direction and incorrect visualization of anatomical landmarks, which made it impossible to correctly measure the angular parameters of the hip joint (Fig. 1). In this case, the deviation of the baseline from the vertical leads to errors in measuring the angles of alpha and beta.

Orak et al. (2015) describe an interesting observation; they analyzed the examination data of the hip joints of one child, which was performed by four different specialists. As a result of the study, contradictory conclusions about the development of the joint were obtained. The values of the alpha angle were 71, 57, 68, and 72 degrees; the values of the beta angle were 52, 49, 55, and 54 degrees [31]. Differences in the figures obtained resulted in the establishment of a different sonographic type of joint, requiring treatment in one case and follow-up in another.

Therefore, sonograms taken in violation of the examination technique should not be subjected to analysis, because this leads to underdiagnosis or overdiagnosis of the condition. This unjustifiably prescribed treatment in itself can cause complications [26, 31, 32]. In approximately a third of our observations, the results of ultrasound examination of the hip joints were presented only descriptively, without measuring the angular parameters and classification of the hip joint type. Insufficient training of the orthopedist and specialist performing the examination resulted in the fact that the final conclusion about the degree of violation of the ratio in the hip joint and, accordingly, the determination of the treatment tactics were postponed until the



**Fig. 1.** Differences in the sonographic pattern, depending on the position of the sensor in the study of the hip joint: *a* — anterior inclination of the sensor; *b* — correct position of the sensor; *c* — posterior inclination of the sensor

radiography was performed after 3–4 months of age. Therefore, CHD was diagnosed in only 82 children (32.8%) in the first 3 months of life.

The most common mistake in treatment of children with hip dislocation in this age group was the use of therapeutic measures that were inadequate to the nature of the pathology (105 children, 42%), in particular:

(1) the use of massage, gymnastics, physiotherapy, and chromotherapy without fixing the lower limbs with orthopedic structures in established congenital subluxation or dislocation of the hip, which naturally led to the progression of anatomical changes in the joint;

(2) the use of removable structures that did not provide the optimal position for repositioning (bending in the hip joint was 95–105 degrees, dosed abduction was 45–60 degrees), such as the Vilensky splint, the Lange bandage-spreader, and the Frake soft pillow.

### 3. Diagnosis and treatment in the period of 3–6 months

As a rule, in children of this age group, an X-ray examination enables to unequivocally answer the question of the nature of violations of the hip joint ratios [33, 34]. For the X-ray diagnosis of violations of the hip joint ratios, the Hilgenreiner scheme (Hilgenreiner N., 1925) is widely used (Fig. 2).

Further, the modified Tönnis scheme (2015) is simple and easily reproducible in practical terms. It enables determination of the radiographic type of

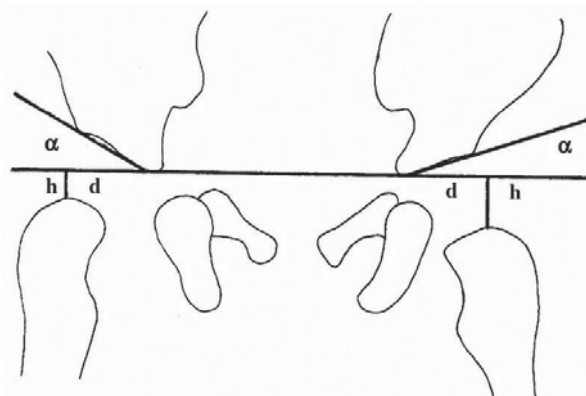


Fig. 2. Hilgenreiner scheme. Determination of the acetabular index and height,  $h$

the hip joint in the absence of a focus of ossification of the femoral head epiphysis [35] (Fig. 3).

The basic errors in performing the radiographic examination were skewed pelvis and external rotation of the lower limbs.

In analyzing the ongoing treatment, as well as treatment of children in the 1–3-months age group, most often we noted the use of orthopedic structures and procedures that are inadequate to the nature of pathology.

At the time of admission to the institute, 135 (54%) children had symptoms of femoral head dystrophy of varying severity, according to the Kalamchi and MacEwen classification [36]. Impaired blood circulation in the femoral head and neck causes postposition avascular necrosis of the femoral head (ANFH). This complication can occur with any treatment method of CHD; according to the literature, its frequency is 3%–70% [5, 36, 37].

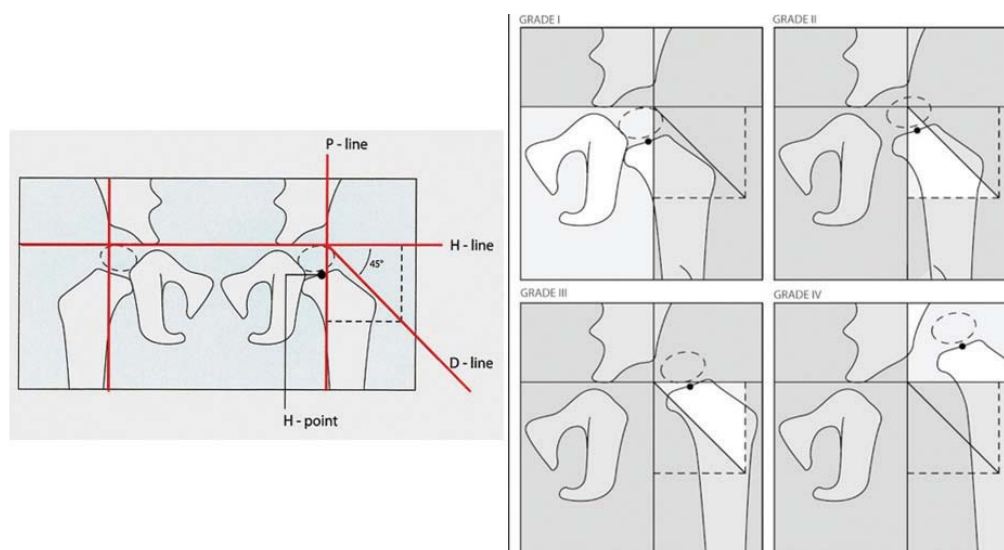


Fig. 3. Modified Tönnis scheme. Determination of the radiographic type of the hip joint, depending on the location of the point of the femoral head center (H-point)



Damage to the growth zones of the proximal femur in the child, because of ischemia or necrosis in the hip joint, leads to shortening of the neck and limb, as a whole, and multiplanar deformities of the proximal femur. This causes the development of early deforming arthrosis of the hip joint and sharply worsens the disease prognosis [3, 5, 25, 36, 38].

In our observations, the main reasons for ANFH development in the conservative treatment of children with CHD were the following: (1) absence of pre-reposition preparation; (2) one-stage attempts at closed hip repositioning; (3) fixation in the orthopedic structure with excess abduction in the hip joints, close to 90 degrees [37, 39]; (4) prolonged fixation in orthopedic structures in the absence of the femoral head repositioning; and (5) multiple attempts at closed hip abduction.

It is necessary to focus on the early clinical signs of the possible development of aseptic necrosis of the femoral head with conservative treatment. In the first two to three days after the installation of the orthopedic structure, the child appears anxious for several hours, refuses food, and has signs of painful contracture (lack of active limb movements, soreness of passive movements, swelling of the joint area, discoloration of the skin). In such cases, it is necessary to remove the structure, prescribe painkillers and non-steroid anti-inflammatory medications, and use warm baths several times a day and relaxing massages [37, 40, 41].

If such clinical manifestations have occurred, despite the pre-reposition preparation and in provision of an optimal position for repositioning, we consider it advisable to refrain from further attempts at closed repositioning.

#### **4. Diagnosis and treatment at the age of 6–12 months**

The main problem in the treatment of children in this age group is late diagnosis and treatment. Anatomical reasons for the impossibility of repositioning in the dysplastic hip joint are well known and are caused by a complex of soft-tissue formations in the lower parts of the cavity: the capsule of the joint and the tendon of the lumboinguinal muscle; the transverse ligament of the cavity and the round ligament of the hip; and the shortening of the muscles with a high displacement of the femoral head. Without treatment, the listed

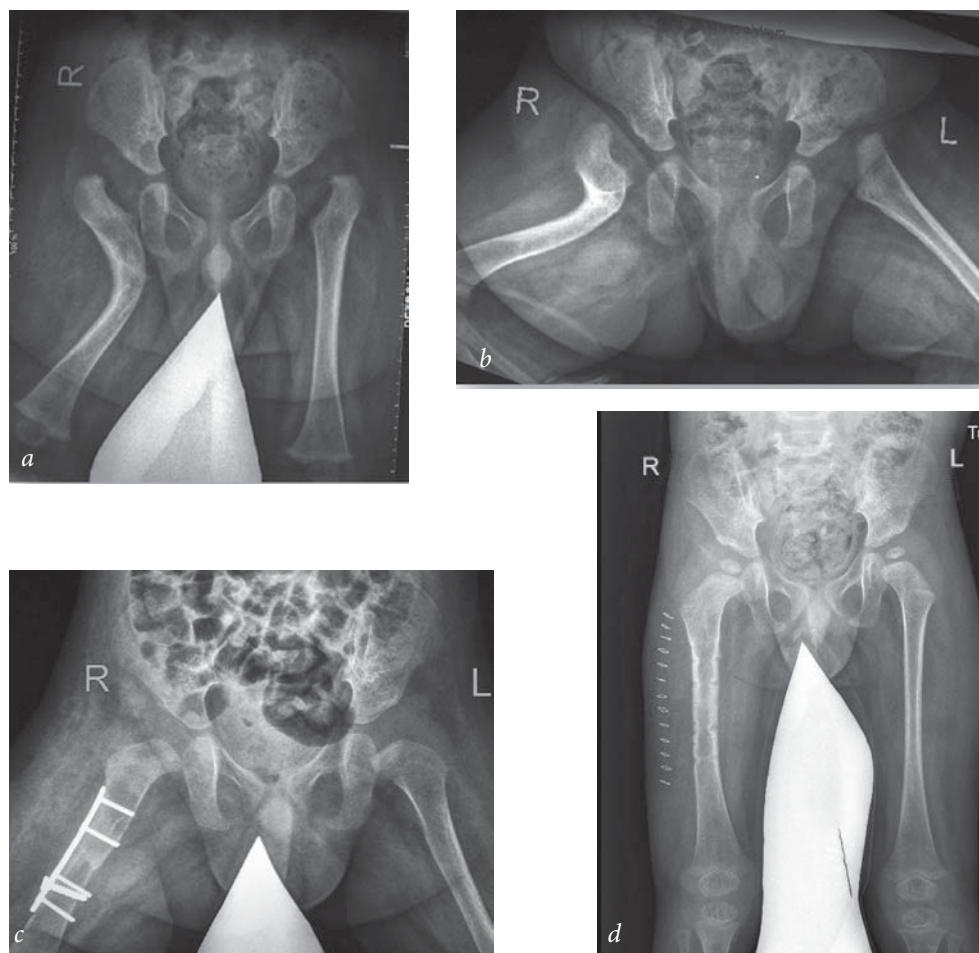
anatomical changes are aggravated with the growth of the child.

An important aspect of the problem is the issues of differential diagnosis of the disease, namely, the early detection of hip dislocations of non-dysplastic nature [38, 42, 43].

In our observations of 32 children (12.8 %), as a result of the examination and taking into account intraoperative data, it was found that the violation of the hip joint ratio and femoral head displacement were not associated with a typical underdevelopment of the acetabulum. A number of pathological conditions in children in the first months of life can be mistakenly regarded as congenital dysplastic hip dislocation. The most common of these are congenital teratogenic hip dislocation (13 children) and hip dislocation due to the consequences of septic arthritis (hematogenous osteomyelitis, 19 children).

The formation of teratogenic (embryonic) hip dislocations occurs in the early intrauterine period. Such dislocations are characterized by a significant limitation of hip abduction and a sharp tension of the hip adductors, marked contractures, and shortening of the muscles. Often dislocations can be bilateral and combined with other malformations. Diagnosis of cases of high teratogenic hip dislocations present at the time of birth, as a rule, does not cause difficulties, given the characteristic clinical picture of the disease. A more complex problem is the diagnosis of hip dislocations in arthrogryposis-like diseases, when contractures and deformities of other joints, particularly in a child in the first year of life, are absent or expressed minimally. According to the literature, hip joint damage in these cases is observed in 28%–90% of cases [44]. Hip dislocation is accompanied by various hip joint contractures; the muscles surrounding the joint are shortened and fibrously regenerated. The acetabulum is usually small, and the femoral neck is shortened. The early neoarthrosis formation is typical [45].

Given the described changes in soft tissues, conservative treatment of such patients, aimed at achieving repositioning, is ineffective. ANFH after closed hip repositioning is observed in 60%–100% of cases; relaxation and stiffness are frequent. The use of conservative procedures in such situations can be aimed only at prevention of the contraction aggravation and preparation for surgical treatment.



**Fig. 4.** Radiographs of patient P, age 5 months: *a, b* — before surgery (multiplanar hip deformity on the right, hip dislocation on both sides); *c* — after surgery; *d* — 1 year after the onset of surgical treatment

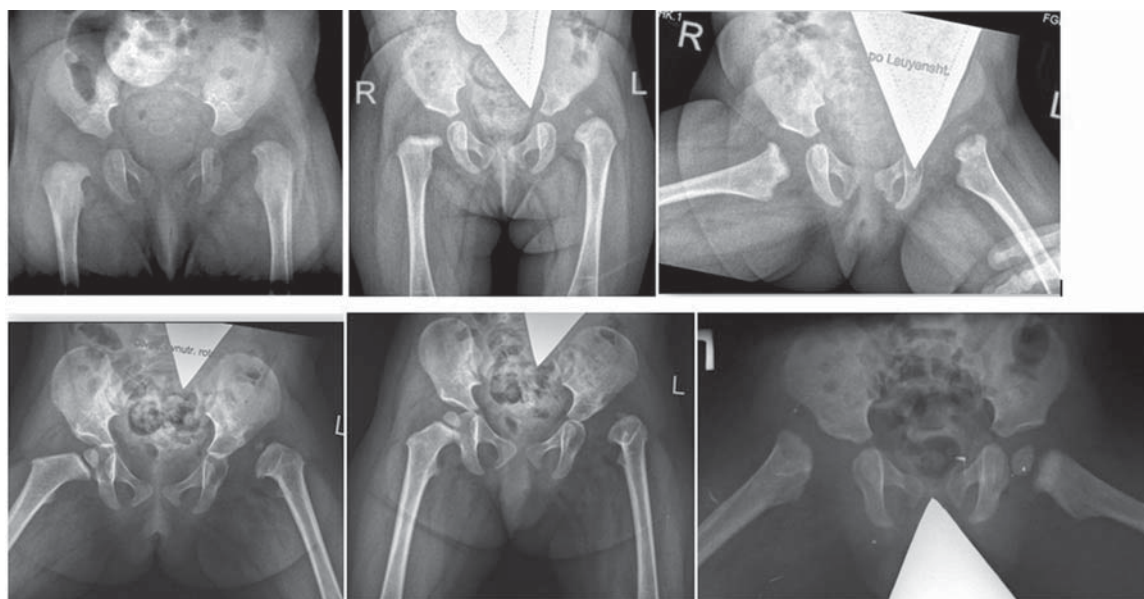
One of the observations is provided below.

Fig. 4 displays the radiographs of a patient P, who came to us at age 5 months with an X-ray pattern of bilateral hip dislocation and a multiplanar deformity of the right femur on the right (caused due to fracture of the femur as a result of unsuccessful attempts at closed repositioning) (Fig. 4, *a, b*). The restriction of movement in the hip joints was clinically defined (abduction and rotation of the hips). No contractures and deformities of other joints were revealed. We started surgical treatment on the left (open hip repositioning) at 7 months of age. (Fig. 4, *c*). Intraoperatively, by the characteristic changes in soft tissues and the regeneration of muscles, the non-dysplastic nature of hip dislocation was confirmed. To restore the femoral head in the center of the cavity, it was necessary to perform an extensive capsulotomy and tenotomy of subspinal muscles and external rotators. On the right, an open hip repositioning was performed in combination with corrective osteotomy of the hip and intervention on soft

tissues (Fig. 4, *d*). We associated complications of conservative treatment methods, particularly, with the impossibility of hip repositioning using these conservative methods.

In the case of pathological “distensible” hip dislocation (caused due to hematogenous osteomyelitis), exudate accumulates in the joint cavity, which leads to a stretching of the capsule, an increase in intra-articular pressure, and displacement of the femoral head from the cavity. If decompression, sanitation of the purulent focus, and evacuation of the exudate are not performed in a timely manner, and there are no orthopedic measures, then a full, “established” pathological dislocation of the hip occurs. In the joint cavity, an interponate is created in the form of synchiae and extensive cicatricial proliferation.

In some cases, when the condition is inapparent in young children, the diagnosis may be difficult, because typical symptoms and signs of the condition, as well as obvious destructive changes in the proximal femur, may be absent. Such a



**Fig. 5.** Radiographs of patients with pathological hip dislocation. Foci of bone tissue destruction and deformity of the proximal femur are shown

pathological hip dislocation can be mistakenly regarded as congenital.

A thorough history of these patients can reveal references to massive antibiotic therapy in the first days of the child's life because of pneumonia, otitis, umbilical sepsis, or acute epiphyseal hematogenous osteomyelitis. In such situations, in the acute period, edema, restriction, and soreness of active and passive movements in the hip joint are noted locally, particularly internal hip rotation and the adduction-flexion contracture in the hip joint.

On the radiographs of the hip joints, which must be performed in at least two projections (frontal, according to Lauenstein), besides hip dislocation, it is possible to detect the periosteal stratifications, osteoporosis, and foci of bone tissue destruction. The focus of ossification appears late and is deformed. The cervical hip is thickened and deformed. The development of the acetabulum is often intact, and the acetabular index is slightly altered.

Fig. 5 shows the radiographs of children who had received long-term conservative treatment in a primary care facility with no effect and who were admitted to the institute with a diagnosis of CHD. From patient history and functional radiographs, pathological hip dislocation was diagnosed.

As a result of the inflammatory process in the joint cavity, an interponate is created in the form of synchiae and extensive cicatricial proliferation.

The intra-articular obstructions formed do not allow conservative implementation of concentric hip repositioning. In such cases, primary surgical treatment is indicated.

The term "unreducible hip dislocation" in the literature implies the impossibility of achieving concentric repositioning of the femoral head into the cavity using conservative methods even at a relatively early onset of treatment. According to the literature, this condition occurs in 2-5%–15% of cases [1, 5-7, 12, 43, 44]. According to our observations, in the group of unreducible hip dislocation, the dislocations of the non-dysplastic nature account for at least 20% of cases.

From a practical point of view, early detection of unreducible hip dislocations is necessary to not only avoid unnecessary loss of time in conservative treatment but also prevent complications, particularly ANFH.

Further, the "paramedical" aspect of the problem of conservative treatment in children with CHD should be mentioned. According to our observations, due to the poor knowledge of the child's parents about the severity of the pathology or other causes, in approximately 20%–25% of cases, certain violations of the prescribed recommendations on the mode of wearing orthopedic structures were noted [40]. As a result, the repositioning was not achieved or was unstable, and negative treatment dynamics were noted.



## Conclusion

The most common causes of errors in CHD diagnosis in children are the lack of examination of the newborn by an orthopedist in the maternity unit and sonographic screening as well as the error in its implementation. At the beginning of treatment, the use of structures was noted, which did not provide the optimal position for repositioning the femoral head as well as the late setting of indications for primary surgical treatment in cases with unreducible hip dislocations. The analysis of the main errors in diagnosis and treatment of children with a hip dislocation will be useful for practicing orthopedists. Reducing the frequency of diagnostic errors will enable improve the results of patient treatment.

## Funding and conflict of interestt

The work was performed on the basis of and with the support of the Turner Scientific and Research Institute for Children's Orthopedics of the Ministry of Health of Russia. The authors declare no obvious and potential conflicts of interest related to the publication of this article.

## References

1. Гончарова М.Н., Бровкина Т.А. Ранняя диагностика и функциональные методы лечения врожденного вывиха бедра у детей. – Л.: Медицина, 1968. – 145 с. [Goncharova MN, Brovkina TA. Rannyyaya diagnostika i funktsional'nye metody lecheniya vrozhdenного vyviiha bedra u detej. Leningrad: Medicina; 1968. 145 p. (In Russ).]
2. Jacobsen S, Sonne-Holm S. Hip dysplasia: a significant risk factor for the development of hip osteoarthritis. A cross-sectional survey. *Rheumatology (Oxford)*. 2005;44(2):211-218. doi: 10.1093/rheumatology/keh436.
3. Harris WH. Etiology of osteoarthritis of the hip. *Clin Orthop Relat Res*. 1986;213:20-33. doi: 10.1097/00003086-198612000-00004.
4. Shipman SA, Helfand M, Moyer VA, Yawn BP. Screening for developmental dysplasia of the hip: a systematic literature review for the US Preventive Services Task Force. *Pediatrics*. 2006;117(3):e557-76. doi: 10.1542/peds.2005-1597.
5. Weinstein SL. Natural history of congenital hip dislocation (CHD) and hip dysplasia. *Clin Orthop*. 1987;225:62-76. doi: 10.1097/00003086-198712000-00007.
6. Weinstein SL. Developmental hip dysplasia and dislocation. In: Morrissy RT, Weinstein SL, editors. *Lovell and Winter's pediatric orthopaedics*. 4th ed. Philadelphia: Lippincott-Raven; 1996:903-43.
7. Tachdjian MO. Congenital dysplasia of the hip. In: Tachdjian MO, editor. *Pediatric orthopedics*. 2nd ed. Vol 1. Philadelphia: WB Saunders; 1990:297-526.
8. Gosvig KK, Jacobsen S, Sonne-Holm S, et al. Prevalence of malformations of the hip joint and their relationship to sex, groin pain, and risk of osteoarthritis: a population-based survey. *J Bone Joint Surg Am*. 2010;92(5):1162-1169. doi: 10.2106/JBJS.H.01674.
9. Ortiz-Neira CL, Paolucci EO, Donnon T. A meta-analysis of common risk factors associated with the diagnosis of developmental dysplasia of the hip in newborns. *Eur J Radiol*. 2012;81(3):e344-351. doi: 10.1016/j.ejrad.2011.11.003.
10. Баиндурашвили А.Г., Камоско М.М., Краснов А.И. и др. Дисплазия тазобедренных суставов (врожденный вывих, подвывих бедра) — диагностика и лечение у детей младшего возраста. Пособие для врачей. – СПб., 2011. – 36 с. [Baindurashvili AG, Kamosko MM, Krasnov AI, et al. Displaziya tazobedrennyh sustavov (vrozhdennyj vyvih, podvyvih bedra) – diagnostika i lechenie u detej mladshogo vozrasta. Posobie dlya vrachej. Saint Petersburg; 2011. 36 p. (In Russ).]
11. Pavlik A, Peltier LF. The functional method of treatment using a harness with stirrups as the primary method of conservative therapy for infants with congenital dislocation of the hip. 1957. *Clin Orthop Relat Res*. 1992;281:4-10. doi: 10.1097/00003086-199208000-00002.
12. Grill F, Bensahel H, Canadell J, et al. The Pavlik harness in the treatment of congenital dislocating hip: report on a multicenter study of the European Paediatric Orthopaedic Society. *J Pediatr Orthop*. 1988;8(1):1-8. doi: 10.1097/01241398-198801000-00001.
13. Ömeroğlu H, Köse N, Akceylan A. Success of Pavlik Harness Treatment Decreases in Patients  $\geq$  4 Months and in Ultrasonographically Dislocated Hips in Developmental Dysplasia of the Hip. *Clin Orthop Relat Res*. 2015;474(5):1146-52. doi: 10.1007/s11999-015-4388-5.
14. Gage JR, Winter RB. Avascular necrosis of the capital femoral epiphysis as a complication of closed reduction of congenital dislocation of the hip. A critical review of twenty years' experience at Gillette Children's Hospital. *J Bone Joint Surg Am*. 1972;54(2):373-88. doi: 10.2106/00004623-197254020-00015.
15. Malvitz TA, Weinstein SL. Closed reduction for congenital dysplasia of the hip. Functional and radiographic results after an average of thirty years. *J Bone Joint Surg Am*. 1994;76(12):1777-92. doi: 10.2106/00004623-199412000-00004.
16. Баиндурашвили А.Г., Волошин С.Ю., Краснов А.И. Врожденный вывих бедра у детей грудного возраста: клиника, диагностика, консервативное лечение. – СПб.: Спец. Лит, 2012. – 95 с. [Baindurashvili AG, Voloshin SY, Krasnov AI. Vrozhdennyj vyvih bedra u detej grudnogo vozrasta: klinika, diagnostika, konservativnoe lechenie. Saint Petersburg: Spec. Lit; 2012. 95 p. (In Russ).]
17. Mulpuri K, Schaeffer EK, Andrade J, et al. IHDI Study Group. What Risk Factors and Characteristics Are



- Associated With Late-presenting Dislocations of the Hip in Infants? *Clin Orthop Relat Res.* 2016;474(5):1131-7. doi: 10.1007/s11999-015-4668-0.
18. de Hundt M, Vlemmix F, Bais JM, et al. Risk factors for developmental dysplasia of the hip: a meta-analysis. *Eur J Obstet Gynecol Reprod Biol.* 2012;165(1):8-17. doi: 10.1016/j.ejogrb.2012.06.030.
  19. Ortiz-Neira CL, Paolucci EO, Donnon T. A meta-analysis of common risk factors associated with the diagnosis of developmental dysplasia of the hip in newborns. *Eur J Radiol.* 2012;81(3):e344-51. doi: 10.1016/j.ejrad.2011.11.003.
  20. Garvey M, Donoghue VB, Gorman WA, et al. Radiographic screening at four months of infants at risk for congenital hip dislocation. *J Bone Joint Surg Br.* 1992;74(5):704-7.
  21. Jones DA, Powell N. Ultrasound and neonatal hip screening. A prospective study of "high risk" babies. *J Bone Joint Surg Am.* 1990;72(3):457-9.
  22. Marks DS, Clegg J, Al-Chalabi AN. Routine ultrasound screening for neonatal hip instability. Can it abolish late-presenting congenital dislocation of the hip? *J Bone Joint Surg Br.* 1994;76(4):534-8.
  23. Tredwell SJ, Bell HM. Efficacy of neonatal hip examination. *J Pediatr Orthop.* 1981;1(1):61-65. doi: 10.1097/01241398-198101010-00009.
  24. Barlow TG. Early diagnosis and treatment of congenital dislocation of the hip. *J Bone Joint Surg Br.* 1962;44:292-301.
  25. Камоско М.М., Краснов А.И., Басков В.Е., и др. Система лечения дисплазии тазобедренного сустава у детей // Ортопедия, травматология и восстановительная хирургия детского возраста. – 2013. – Т. 1. – № 1. – С. 26–35. [Kamosko MM, Krasnov AI, Baskov VE, et al. The system of treatment of hip dysplasia in children (conception of Srico n.a. H.I. Turner). *Pediatric Traumatology, Orthopaedics, and Reconstructive Surgery.* 2013;1(1):26-35. (In Russ.)] doi: 10.17816/PTORS1126-35.
  26. Graf R. Fundamentals of sonographic diagnosis of infant hip dysplasia. *J Pediatr Orthop.* 1984;4(6):735-40. doi: 10.1097/01241398-198411000-00015.
  27. Dorn U, Neumann D. Ultrasound for screening developmental dysplasia of the hip: a European perspective. *Curr Opin Pediatr.* 2005;17(1):30-3. doi: 10.1097/01.mop.0000151554.10176.34.
  28. Rosendahl K, Toma P. Ultrasound in the diagnosis of developmental dysplasia of the hip in newborns. The European approach. A review of methods, accuracy and clinical validity. *Eur Radiol.* 2007;17:1960-7.
  29. Lehmann HP, Hinton R, Morello P, Santoli J. Developmental dysplasia of the hip practice guideline: technical report. Committee on Quality Improvement, and Subcommittee on Developmental Dysplasia of the Hip. *Pediatrics.* 2000;105(4):e57. doi: 10.1542/peds.105.4.e57.
  30. Goldberg M. Early detection of developmental hip dysplasia: synopsis of the AAP Clinical Practice Guideline. *Pediatr Rev.* 2001;22(4):131-4. doi: 10.1542/pir.22-4-131.
  31. Orak MM, Onay T, Cagirmaz T, et al. The reliability of ultrasonography in developmental dysplasia of the hip: How reliable is it in different hands? *Indian J Orthop.* 2015;49(6):610. doi: 10.4103/0019-5413.168753.
  32. Mahan ST, Katz JN, Kim Y-J. To Screen or Not to Screen? A Decision Analysis of the Utility of Screening for Developmental Dysplasia of the Hip. *The Journal of Bone and Joint Surgery American volume.* 2009;91(7):1705-1719. doi: 10.2106/JBJS.H.00122.
  33. Dornacher D, Cakir B, Reichel H, Nelitz M. Early radiological outcome of ultrasound monitoring in infants with developmental dysplasia of the hips. *J Pediatr Orthop B.* 2010;19(1):27-31. doi: 10.1097/pb.0b013e328330335e.
  34. Tonnis D. Normal values of the hip joint for the evaluation of X-rays in children and adults. *Clin Orthop Relat Res.* 1976;119:39-47. doi: 10.1097/00003086-197609000-00007.
  35. Narayanan U1, Mulpuri K, Sankar WN, et al. Reliability of a New Radiographic Classification for Developmental Dysplasia of the Hip. *J Pediatr Orthop.* 2015;35(5):478-84. doi: 10.1097/BPO.0000000000000318.
  36. Kalamchi A, McEwen GD. Avascular necrosis following treatment of congenital dislocation of the hip. *J Bone and Joint Surg.* 1980;62(6):876-888. doi: 10.2106/00004623-198062060-00002.
  37. Бовтунов А.З. Пострепозиционный ишемический некроз головки бедренной кости у детей (диагностика, лечение): автореф. дис. ... канд. мед. наук. – СПб., 2000. – 19 с. [Bovtunov AZ. Postrepozicionnyj ishemicheskij nekroz golovki bedrennoj kosti u detej (diagnostika, lechenie) [dissertation]. Saint Petersburg; 2000. 19 p. (In Russ.)]
  38. Nakamura J, Kamegaya M, Saisu T, et al. Treatment for developmental dysplasia of the hip using the Pavlik harness: long-term results. *J Bone Joint Surg Br.* 2007;89-B(2):230-5. doi: 10.1302/0301-620x.89b2.18057.
  39. Schur MD, Lee C, Arkader A, et al. Risk factors for avascular necrosis after closed reduction for developmental dysplasia of the hip. *Journal of Children's Orthopaedics.* 2016;10(3):185-192. doi: 10.1007/s11832-016-0743-7.
  40. Малахов О.А., Кралина С.Э. Врожденный вывих бедра. – М.: Медицина, 2006. – 127 с. [Malahov OA, Kralina SE. Vrozhdenyj vyvih bedra, Moscow: Medicina; 2006. 127 p. (In Russ.)]
  41. Johnson AH, Aadalen RJ, Eilers VE, Winter RB. Treatment of congenital hip dislocation and dysplasia with the Pavlik harness. *Clin Orthop Relat Res.* 1981;155:25-9. doi:10.1097/00003086-198103000-00004.
  42. Николаев А.И. Профилактика и раннее комплексное лечение детей с патологическим вывихом бедра: автореф. дис. ... канд. мед. наук. – СПб., 2005. – 16 с. [Nikolaev AI. Profilaktika i ranee kompleksnoe lechenie detei s patologicheskim vyvihom bedra [dissertation]. Saint Petersburg; 2005. 16 p. (In Russ.)]
  43. Поздникин И.Ю., Басков В.Е., Барсуков Д.Б., Бортулев П.И. О причинах неудач консервативного

лечения детей с вывихом бедра: тезисы V Евразийского конгресса травматологов-ортопедов и III Съезда травматологов-ортопедов Кыргызстана, посвященного 80-летию профессора С.К. Кожоматова «Современная травматология и ортопедия – перспективы, проблемы и пути решения». 26–28 августа 2016 года, Ыссык-Куль, Кыргызстан // Травматология и ортопедия Центральной Азии. – 2016. – № 2. – С. 116–117. [Pozdnikin IYu, Baskov VE, Barsukov D B, Bortulev PI. O prichinah neudach konservativnogo lecheniya detej s vyvihom bedra: tezisy V Evrazijskogo Kongressa travmatologov-ortopedov i III S'ezda travmatologov-ortopedov Kyrgyzstana, posvyashchennogo 80-letiyu professora Kozhokmatova SK. "Sovremennaya travmatologiya i ortopediya – perspektivy, problemy i puti resheniya". 26-28.08.2016, Yssyk-Kul'. *Travmatologiya i ortopediya Central'noj Azii*. 2016;2:116-117 (In Russ.)]

44. Мирзоева И.И., Никифорова Т.К. О формировании тазобедренных суставов при артрогрипозе // Вывихи бедра у детей: Сборник научных работ. – Л., 1972. – С. 115–118. [Mirzoeva II, Nikiforova TK. O formirovanii tazobedrennyh sustavov pri artrogripoze. In: Vyvichi bedra u detej: Sbornik nauchnyh rabot. Leningrad; 1972. 115–118 p. (In Russ.)]
45. Баткин С.Ф., Агранович О.Е., Барсуков Д.Б. Тактика лечения вывиха бедра у больных с артрогрипозом (обзор литературы) // Ортопедия, травматология и восстановительная хирургия детского возраста. – 2014. – Т. 2. – № 2. – С. 55–62. [Bat'kin SF, Agranovich OE, Barsukov DB. Management of hip dislocation in patients with arthrogryposis (review). *Pediatric Traumatology, Orthopaedics, and Reconstructive Surgery*. 2014;2(2):55-62. (In Russ.)] doi: 10.17816/PTORS2255-62.

### Information about the authors

**Ivan Y. Pozdnikin** — MD, PhD, research associate of the department of hip pathology. The Turner Scientific and Research Institute for Children's Orthopedics. E-mail: pozdnikin@gmail.com.

**Vladimir E. Baskov** — MD, PhD, head of the department of hip pathology. The Turner Scientific and Research Institute for Children's Orthopedics. E-mail: dr.baskov@mail.ru.

**Sergei Y. Voloshin** — MD, PhD, chief of the department of hip pathology. The Turner Scientific and Research Institute for Children's Orthopedics. E-mail: volochin\_ortoped@mail.ru.

**Dmitry B. Barsukov** — MD, PhD, senior research associate of the department of hip pathology. The Turner Scientific and Research Institute for Children's Orthopedics. E-mail: dbbarsukov@gmail.com.

**Andrey I. Krasnov** — MD, PhD, orthopedic and trauma surgeon. The Turner Scientific and Research Institute for Children's Orthopedics.

**Mahmoud S. Poznovich** — MD, PhD student of the Turner Scientific and Research Institute for Children's Orthopedics.

**Pavel I. Bortulev** — MD, research associate of the department of hip pathology. The Turner Scientific and Research Institute for Children's Orthopedics. E-mail: pavel.bortulev@yandex.ru.

**Tamila V. Baskaeva** — MD, orthopedic surgeon of the Turner Scientific and Research Institute for Children's Orthopedics. E-mail: tamila-baskaeva@mail.ru.

**Oksana V. Bortuleva** — MD, PhD student of the department of hip pathology. The Turner Scientific and Research Institute for Children's Orthopedics.

**Иван Юрьевич Поздникин** — канд. мед. наук, научный сотрудник отделения патологии тазобедренного сустава ФГБУ «НИДОИ им. Г.И. Турнера» Минздрава России. E-mail: pozdnikin@gmail.com.

**Владимир Евгеньевич Басков** — канд. мед. наук, руководитель отделения патологии тазобедренного сустава ФГБУ «НИДОИ им. Г.И. Турнера» Минздрава России. E-mail: dr.baskov@mail.ru.

**Сергей Юрьевич Волошин** — канд. мед. наук, заведующий отделением патологии тазобедренного сустава ФГБУ «НИДОИ им. Г.И. Турнера» Минздрава России. E-mail: volochin\_ortoped@mail.ru.

**Дмитрий Борисович Барсуков** — канд. мед. наук, старший научный сотрудник отделения патологии тазобедренного сустава ФГБУ «НИДОИ им. Г.И. Турнера» Минздрава России. E-mail: dbbarsukov@gmail.com.

**Андрей Иванович Краснов** — канд. мед. наук, врач травматолог-ортопед ФГБУ «НИДОИ им. Г.И. Турнера» Минздрава России.

**Махмуд Станиславович Познович** — аспирант ФГБУ «НИДОИ им. Г.И. Турнера» Минздрава России.

**Павел Игоревич Бортулёв** — научный сотрудник отделения патологии тазобедренного сустава ФГБУ «НИДОИ им. Г.И. Турнера» Минздрава России. E-mail: pavel.bortulev@yandex.ru.

**Тамила Владимировна Баскаева** — врач травматолог-ортопед отделения патологии тазобедренного сустава ФГБУ «НИДОИ им. Г.И. Турнера» Минздрава России. E-mail: tamila-baskaeva@mail.ru.

**Оксана Вячеславовна Бортулёва** — аспирант отделения патологии тазобедренного сустава ФГБУ «НИДОИ им. Г.И. Турнера» Минздрава России.