

BRIEF CONCEPT OF HIP PRESERVATION

© *S.S. Madan, S.K. Chilbule*

Sheffield Children's Hospital, Sheffield, UK

Received: 22.07.17

Accepted: 23.11.2017

Restoration of the anatomy of the hip joint and biomechanics across it, carry the immense importance to prevent future osteoarthritis of the joint. The aim of this review is to provide the brief concept of the methods to preserve the hip, especially in young adults.

Attempts to preserve the hips start with the intense preoperative planning of the corrective procedure. Different parameters regarding the femur and acetabulum in all 3 dimensions need to be assessed. Especially, measurement of the anteversion of the femur and acetabulum is a significant step to avoid osteoarthritis. In addition, the suprapelvic and infrapelvic (spine and lower limb lengths) alignment needs to be considered in the planning.

Correction of the femoral side of the hip needs the understanding of the blood supply of the proximal femur which carries the risk of avascular necrosis more so with intracapsular osteotomies. Acetabular reorientation, to re-distribute the forces over the weight bearing part, can be carried out with re-directional osteotomy such as periacetabular osteotomy. It needs the understanding of the acetabular anatomy and the force distribution in it.

To conclude, correction of both femoral and acetabular side parameters need to be considered in decision making depending on the alterations due to various etiologies causing the hip disorders.

Keywords: young adults; PAO; femoral osteotomy; hip dysplasia; instability index.

КРАТКИЙ ОБЗОР МЕТОДИК СОХРАНЕНИЯ ТАЗОБЕДРЕННОГО СУСТАВА

© *С.С. Мадан, С.К. Чилбул*

Детская больница Шеффилда, Шеффилд, Великобритания

Статья поступила в редакцию: 22.07.17

Статья принята к печати: 23.11.2017

Восстановление анатомии тазобедренного сустава и его биомеханики имеет огромное значение для предотвращения развития остеоартроза в будущем. Целью данного обзора было рассмотрение методик, используемых для сохранения тазобедренного сустава, особенно у молодых людей.

Попытки сохранения тазобедренного сустава должны начинаться с тщательного предоперационного планирования корректирующей процедуры. Следует провести оценку различных параметров, касающихся бедренной кости и вертлужной впадины, во всех трех измерениях. Расчет угла антеверсии бедренной кости и вертлужной впадины — важный шаг на пути предотвращения остеоартроза. Кроме того, при планировании необходимо учитывать выравнивание органов над и под тазобедренным суставом (позвоночник, длина нижних конечностей).

При коррекции бедренной кости важно понимать особенности кровоснабжения ее проксимального отдела, поскольку он наиболее подвержен риску асептического некроза при проведении интракапсулярной остеотомии. Переориентация вертлужной впадины с целью перераспределения нагрузки в суставе может проводиться при периацетабулярной остеотомии. В данном случае необходимо хорошее знание анатомии вертлужной впадины и распределения силы в ней.

В заключение следует отметить, что при принятии решения необходимо рассматривать коррекцию как бедренной кости, так и вертлужной впадины в зависимости от типа изменений и вызвавших их причин.

Ключевые слова: молодые взрослые; ПАО; остеотомия бедренной кости; дисплазия тазобедренного сустава; индекс нестабильности.

Why Do Hips Fail?

Hip Joint is a ball and socket type of synovial joint, which has been adapted for bipedal motion having a very complex combination of forces acting on it in different phases of the gait cycle [1, 2]. Any anatomical or mechanical deficiency in the proximal femur and acetabulum lead to altered biomechanics, fatigue, pain and eventually osteoarthritis [2]. It is worth remembering that the aim of corrective intervention is to attain soft tissue biomechanical balance, in other words, get the bone and musculo-ligamentous structures to optimal length and function so that there are physiological forces passing through the hip during ambulation. The hip joint is a couple and modern methods of hip reconstruction recommend to simultaneously correct the deformities the femur and the acetabulum to the optimal level.

The sum of the femoral anteversion and acetabular anteversion is called the version of the hip [3]. This was first described by McKibbin and then stressed by Tönnis, for its importance in the optimal transverse biomechanical realignment of the hip [3, 4]. This sum, normally, should be between 20 to 50 degrees. Lower than 20 degrees is considered to be a low McKibbin instability index hip (retroverted) and higher than 50 degrees is considered to be a high instability index (anteverted) hip. Tönnis et al. showed that retroverted hips were more likely to get osteoarthritis (OA) [4].

Altered lower limb alignment in the coronal and sagittal planes can have implications overloading of other joints of the lower limb. Therefore it is prudent to understand the lower limb alignment the before any major osteotomy is done on the hip. Similarly, scoliosis, kyphosis, fixed suprapelvic and infrapelvic tilt will lead to abnormal biomechanics, as will limb length discrepancy [5, 6].

Hips can fail due to

1. Acetabular dysplasia
2. Femero-acetabular Impingement (FAI)
3. Excessive retroversion or anteversion of the hip
4. Incongruency of the hip

5. Altered proximal femur anatomy, viz. short neck high trochanter and coxa magna
6. Trauma
7. Inflammatory Arthropathy
8. Avascular Necrosis
9. Skeletal Dysplasia viz. Epiphyseal Dysplasias, Mucopolysaccharidosis etc.
10. Infection

Proximal femoral intracapsular and extracapsular osteotomy

A deformed or a crooked femur may have an apex of deformity in an oblique plane, which manifests the maximum magnitude of the deformity [5–7]. Also, with translation, rotation, and angulation, the apex of the deformity will be at a different level [6]. It is most important, wherever possible, to perform an osteotomy at the biomechanical apex of the deformity. Therefore pre-operative planning with clinical examination and radiological imaging is mandatory to understand the magnitude and direction of the deformity [5, 6, 8].

Femoral osteotomy can be intracapsular and extracapsular [5, 9, 10].

Examples of intracapsular osteotomies are

- true femoral neck lengthening osteotomy;
- femur head reduction osteotomy;
- transcervical femoral neck lengthening osteotomy;
- Dunn's and Modified Dunn's osteotomy.

Intracapsular (transcervical and subcapital) femoral neck osteotomies can address severe deformities seen in slipped upper femoral epiphysis (SUFE), proximal femoral growth arrests and avascular necrosis [5, 10, 11]. The risk of avascular necrosis of the femoral head with intracapsular osteotomies have has been significantly reduced by Ganz's safe surgical dislocation technique which is based on the detailed understanding of the blood supply of the femoral head [10, 11]. Circular anastomosis formed by branches from medial circumflex femoral and lateral circumflex

femoral arteries from near the base of the femoral neck gives rise to ascending retinacular arteries that traverse the femoral neck and then at the subcapital area they form another incomplete arterial anastomosis, (the ring of Chung) [12, 13]. The lateral cervical artery at the femoral head-neck junction is most vulnerable to trauma or stress. This supplies the lateral and anterior part of the femoral head. Therefore AVN most often affects this part of the femoral head [13]. The dissection in surgical dislocation should extend from the below the lesser trochanter [9]. It is important to free the sleeve of periosteum all around the femoral neck so that the sleeve is attached to the femoral head and free around the neck all around to allow osteotomy of the femoral neck [2, 9]. Though an adult femoral head has got an intra-osseous and retinacular blood supply, this is not the case in children due to the barrier of the growth plate. Therefore, in the latter, the only predominant blood supply is from the retinaculum [14]. The ligamentum teres provides negligible blood supply. Therefore, children are more susceptible to AVN as seen in SUFE, Perthes, and iatrogenic DDH [9, 14].

There are several intertrochanteric/pertrochanteric osteotomies, such as [5, 15–17]:

- varus/valgus/derotation;
- Morscher's osteotomy;
- Wagner osteotomy;
- Southwick's osteotomy;
- femoral shortening/lengthening, extension/flexion.

These osteotomies can be done at pertrochanteric/intertrochanteric level. The advantage is that it is less likely to cause AVN, but does lead to secondary deformities, which can be difficult years later for total hip replacement (THR) [18]. A normal neck shaft angle should be restored. If the hip station is

high, excessive varus should be avoided. Although the literature is replete with varus osteotomies for Perthes, it tends to create the secondary intertrochanteric deformities. One needs to shorten the femur rather than do excessive angular change. The length lost in so doing can be gained by doing an acetabular osteotomy if further femoral coverage is needed (Fig. 1).

Pelvic osteotomy

Single cut osteotomies such as Salter's or Pemberton's are recommended for children and not for young adults due to limited mobility of symphysis pubis and triradiate cartilage respectively [19]. Sutherland's (1977) double osteotomy had an addition of a pubic osteotomy to a Salter osteotomy to obtain correction [20]. Pubic osteotomy with aim of medial displacement was placed medial to the obturator foramen in the interval between the pubic tubercle and the symphysis pubis [20].

Triple pelvic osteotomies potentially provide 3-dimensional correction of acetabular orientation to restore the anatomy. Steel described triple osteotomy of innominate bone in 1973 for older children in which the ischium, superior pubic ramus, and ileum superior to the acetabulum were divided. In this type, the acetabular fragment is quite big and has the attached soft tissues, especially the sacropelvic ligaments which limit the amount of correction [21]. Tönnis described the results of his modification of the triple pelvic osteotomy in young adults even with open triradiate cartilage which provides better acetabular coverage of the femoral head and particularly the translation movement in all 3 planes [22]. The procedure differs from other triple innominate bone techniques mainly

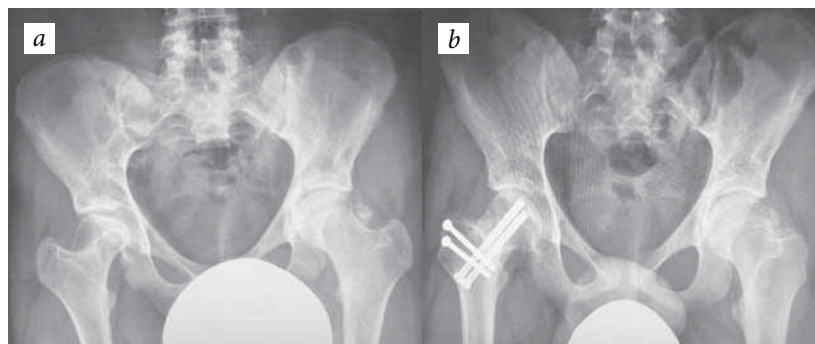


Fig. 1. The preoperative image of an adolescent patient with right hip coxa breva and elliptical femoral head (a); the postoperative radiograph following neck length osteotomy with the improved anatomy of the femur head and neck (b)

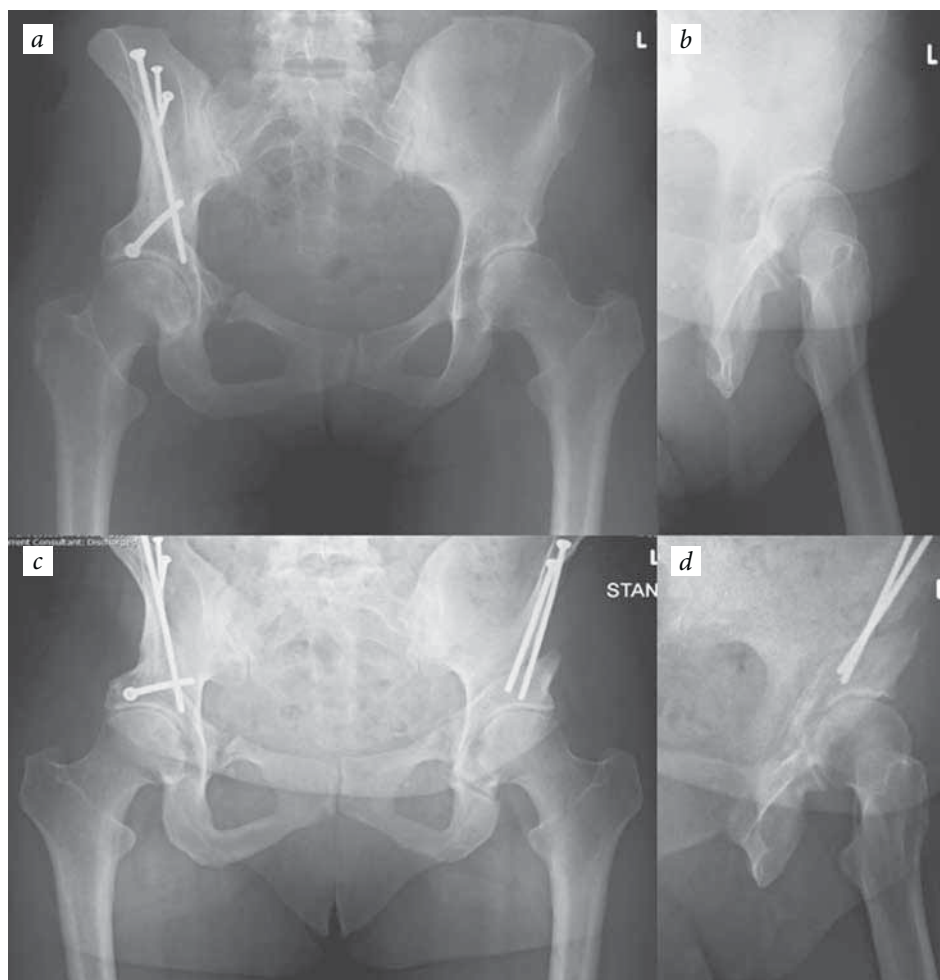


Fig. 2. The hip radiographs of a patient with bilateral hip dysplasia: *a* — the periacetabular osteotomy of the right hip carried out using the traditional approach; *b* — the false profile image of the left hip with anterior deficiency. Later on, the left hip periacetabular osteotomy was carried out using the minimally invasive technique (*c* and *d*)

in the ischeal osteotomy; the cut is closer to the acetabulum skipping the strong ligaments over ischeal tuberosity allowing greater mobility for the acetabular fragment [19, 22]. In contrast to above osteotomies which are described for congruent hips, incongruent hips need salvage or augmentation procedures such as Chiari osteotomy and Shelf procedures [19].

Periacetabular osteotomy

Periacetabular osteotomy has been used in the management of residual acetabular dysplasia to correct the coverage of the femoral head and improve the weight-bearing surface of the acetabulum [23]. Ideally, the acetabulum has to be reoriented to decrease the slope of the weight bearing surface to less than 11 degrees, and to correct the anterior center-edge angle to 30 degrees. By reorienting the acetabulum, the joint surface is prevented from eccentric loading and more even

weight distribution will be achieved, reducing the joint reaction forces [24].

PAO, in turn, will reduce the load per unit area of the cartilage delaying the wear and tear of the cartilage [24, 25]. At the same time studies have been conducted which show that shifting the joint center of rotation has little influence on the forces across the joint in the superoinferior direction [25]. But there is a lot of change in the force when the movement happens in the mediolateral direction. It has been shown by Srakar et al. that lateral shift of the joint center increases and medial shift decreases, the joint reaction forces [25]. It has been hence traditional to shift the fragment medially to medialise the joint center of rotation to reduce the reaction forces in the joint.

But in the actual clinical situation, the movement takes place in all the three planes, and it varies from patient to patient based on the individual requirements. It becomes difficult to be sure how much the joint center has been moved and how

much will be the resultant forces across the joint because of the newly positioned joint center, as there is movement in the flexion/extension, abduction/adduction, and internal/external rotation planes.

With the increase in the need for periacetabular osteotomy, we need to clearly identify the impact of fragment positioning on the load distribution across the cartilage surface. It has been shown that 10% of primary hip replacements are due to hip dysplasia [26]. PAO can really reduce or delay this primary hip replacement if we can have a better understanding of the load distributed across the joint surface per unit area which will determine the cartilage wear across the joint [25, 27].

Currently available data suggest that finite element analysis with an assessment of Von Mises stress distribution is a possible way to assess the force distribution across the joint surface [28]. It has been used for analysis of force distribution across the acetabulum following two different PAO methods by Tai et al. [29]. Discrete element analysis or rigid body spring modeling technique had been used by Chao et al. to calculate joint pressure and ligament tension [30]. They found out that, patients in whom the joint contact forces were increased based on the simulated biomechanical modeling, ended with a poor clinical outcome [30]. The recommendations of this study include CT scan and Gait Analysis preoperative planning to improve the fragment positioning and get the best clinical result (Fig. 2, a, b).

Minimally invasive peri-acetabular osteotomy (MIS PAO). With the primary aim of reducing the morbidity related to soft tissue injury and blood loss in PAO, new minimally invasive PAO has been devised [31, 32].

With an approach through 7-cm skin incision across the anterior superior iliac spine and cutting the inguinal ligament, sartorius muscle is split in the direction of its fibers [33]. After retracting the iliopsoas muscle and the medial part of the sartorius medially, all three osteotomies can be performed using liberal use of fluoroscopy in anteroposterior and 45-degree oblique views [33]. MISPAO is known to cause significantly less intraoperative blood loss and postoperative haemoglobin reduction requiring transfusion [31]. With the similar correction of center-edge and acetabular index

angles, MISPAO has a significantly shorter duration of surgery and less number of moderate or severe complications [31] (Fig. 2, c, d).

Funding and conflict of interest

Hereby, the authors declare that there is no conflict of interest related to this manuscript.

References

- Hogervorst T, Vereecke EE. Evolution of the human hip. Part 1: the osseous framework. *J Hip Preserv Surg.* 2014;1(2):39-45. doi: 10.1093/jhps/hnu013.
- Ganz R, Leunig M, Leunig-Ganz K, Harris WH. The etiology of osteoarthritis of the hip. *Clin Orthop Relat Res.* 2008;466(2):264-72. doi: 10.1007/s11999-007-0060-z.
- McKibbin B. Anatomical factors in the stability of the hip joint in the newborn. *J Bone Joint Surg Br.* 1970;52:148-59.
- Tönnis D, Heinecke A. Decreased acetabular anteversion and femur neck antetorsion cause pain and arthrosis. 1: Statistics and clinical sequelae. *Z Orthop Ihre Grenzgeb.* 1998;137:153-9.
- Paley D. Surgery for residual femoral deformity in adolescents. *Orthop Clin North Am.* 2012;43(3):317-28. doi: 10.1016/j.ocl.2012.05.009.
- Pafilas D, Nayagam S. The pelvic support osteotomy: indications and preoperative planning. *Strategies Trauma Limb Reconstr.* 2008;3(2):83-92. doi: 10.1007/s11751-008-0039-7.
- Cooper AP, Salih S, Geddis C, et al. The oblique plane deformity in slipped capital femoral epiphysis. *J Childs Orthop.* 2014;8(2):121-7. doi: 10.1007/s11832-014-0559-2.
- Barksfield RC, Monsell FP. Predicting translational deformity following opening-wedge osteotomy for lower limb realignment. *Strategies Trauma Limb Reconstr.* 2015;10(3):167-73. doi: 10.1007/s11751-015-0232-4.
- Leunig M, Ganz R. Relative neck lengthening and intracapsular osteotomy for severe Perthes and Perthes-like deformities. *Bull NYU Hosp Jt Dis.* 2011;69:S62.
- Balakumar B, Madan S. Late correction of neck deformity in healed severe slipped capital femoral epiphysis: short-term clinical outcomes. *Hip Int.* 2016;26(4):344-9. doi: 10.5301/hipint.5000347.
- Siebenrock KA, Anwander H, Zurmühle CA, et al. Head reduction osteotomy with additional containment surgery improves sphericity and containment and reduces pain in Legg-Calvé-Perthes disease. *Clin Orthop Relat Res.* 2014;473(4):1274-83. doi: 10.1007/s11999-014-4048-1.
- Chung S. The arterial supply of the developing proximal end of the human femur. *J Bone Joint Surg.* 1976;58(7):961-70. doi: 10.2106/00004623-197658070-00011.
- Zlotorowicz M, Czubak J. Vascular anatomy and blood supply to the femoral head. *Osteonecrosis.* Springer; 2014:19-25. doi: 10.1007/978-3-642-35767-1_2.

14. Lauritzen J. The arterial supply to the femoral head in children. *Acta Orthop Scand.* 1974;45(5):724-36. doi: 10.3109/17453677408989681.
15. Hasler CC, Morscher EW. Femoral neck lengthening osteotomy after growth disturbance of the proximal femur. *J Pediatr Orthop B.* 1999;8(4):271-275. doi: 10.1097/00009957-199910000-00008.
16. Akgul T, Şen C, Balci HI, Polat G. Double intertrochanteric osteotomy for trochanteric overgrowth and a short femoral neck in adolescents. *J Orthop Surg.* 2016;24(3):387-391. doi: 10.1177/1602400324.
17. Southwick WO. Osteotomy through the lesser trochanter for slipped capital femoral epiphysis. *J Bone Joint Surg Am.* 1967;49(5):807-835. doi: 10.2106/00004623-196749050-00001.
18. Boos N, Krushell R, Ganz R, Müller M. Total hip arthroplasty after previous proximal femoral osteotomy. *J Bone Joint Surg Br.* 1997;79(2):247-253. doi: 10.1302/0301-620x.79b2.6982.
19. Maheshwari R, Madan SS. Pelvic osteotomy techniques and comparative effects on biomechanics of the hip: a kinematic study. *Orthopedics.* 2011;34:e821-e6. doi: 10.3928/01477447-20111021-12.
20. Sutherland DH, Greenfield R. Double innominate osteotomy. *J Bone Joint Surg Am.* 1977;59(8):1082-91. doi: 10.2106/00004623-197759080-00014.
21. Steel HH. Triple osteotomy of the innominate bone. *J Bone Joint Surg Am.* 1973;55(2):343-50. doi: 10.2106/00004623-197355020-00010.
22. Tönnis D, Behrens K, Tscharani F. A modified technique of the triple pelvic osteotomy: early results. *J Pediatr Orthop.* 1981;1(3):241-9. doi: 10.1097/01241398-198111000-00001.
23. McKinley TO. The Bernese Periacetabular Osteotomy: Review of reported outcomes and the early experience at the University of Iowa. *Iowa Orthop J.* 2003;23:23.
24. Armand M, Lepistö J, Tallroth K, et al. Outcome of periacetabular osteotomy: joint contact pressure calculation using standing AP radiographs, 12 patients followed for average 2 years. *Acta Orthop.* 2005;76:303-13.
25. Srakar F, Igljic A, Antolic V, Herman S. Computer simulation of periacetabular osteotomy. *Acta Orthop Scand.* 1992;63(4):411-2. doi: 10.3109/17453679209154756.
26. Kurtz S, Ong K, Lau E, et al. Projections of primary and revision hip and knee arthroplasty in the United States from 2005 to 2030. *J Bone Joint Surg Am.* 2007;89(4):780. doi: 10.2106/jbjs.f.00222.
27. Troelsen A, Elmengaard B, Søballe K. Medium-term outcome of periacetabular osteotomy and predictors of conversion to total hip replacement. *J Bone Joint Surg Am.* 2009;91(9):2169-79. doi: 10.2106/jbjs.h.00994.
28. Xu M, Qu W, Wang Y, et al. Theoretical Implications of Periacetabular Osteotomy in Various Dysplastic Acetabular Cartilage Defects as Determined by Finite Element Analysis. *Med Sci Monit.* 2016;22:5124-30. doi: 10.12659/msm.902724.
29. Lin C-LTC-L, Lee H-WWD-M, Hsieh P-H. Stress Distribution of a Modified Periacetabular Osteotomy for Treatment of Dysplastic Acetabulum. *J Med Bio Engineering.* 2010;31:53-8.
30. Chao E, Armand M, Nakamura M, et al. Computer-aided hip osteotomy preoperative planning. 46th Annual Meeting, Orthopaedic Research Society, Orlando; 2000; 2000.
31. Troelsen A, Elmengaard B, Søballe K. Comparison of the minimally invasive and ilioinguinal approaches for periacetabular osteotomy 263 single-surgeon procedures in well-defined study groups. *Acta Orthop.* 2008;79(6):777-84. doi: 10.1080/17453670810016849.
32. Khan O, Malviya A, Subramanian P, et al. Minimally invasive periacetabular osteotomy using a modified Smith-Petersen approach. *Bone Joint J.* 2017;99-B(1):22-8. doi: 10.1302/0301-620x.99b1.bjj-2016-0439.r1.
33. Troelsen A, Elmengaard B, Søballe K. A new minimally invasive transartorial approach for periacetabular osteotomy. *J Bone Joint Surg.* 2008;90(3):493-8. doi: 10.2106/jbjs.f.01399.

Information about the authors

Sanjeev Madan — MS, FRCS (T and O), Clinical Lead, Trauma and Orthopaedics department, Sheffield Children's Hospital. Research Lead, T&O, Doncaster & Bassetlaw teaching hospitals, Honorary Senior Lecturer, University of Sheffield, UK. Email: Sanjeev.madan@sch.nhs.uk

Sanjay Chilbule — MBBS, MS (ortho), Paediatric orthopaedics fellow, Trauma and Orthopaedics department, Sheffield Children's Hospital, Sheffield, UK. Email: sanjay.chilbule@sch.nhs.uk

Санжив Мадан — магистр наук, член Королевского хирургического колледжа. Отделение травмы и ортопедии, Детская больница Шеффилда; почетный преподаватель, учебные больницы Донкастер и Бассетло, Университет Шеффилда, Великобритания. Email: Sanjeev.madan@sch.nhs.uk

Санжай Чилбул — бакалавр медицины и хирургии, магистр наук, детский ортопед. Отделение травмы и ортопедии, Детская больница Шеффилда, Великобритания. Email: sanjay.chilbule@sch.nhs.uk