

TREATMENT APPROACH TO SHOULDER INTERNAL ROTATION DEFORMITY IN CHILDREN WITH OBSTETRIC BRACHIAL PLEXUS PALSY

© O.E. Agranovich, A.B. Oreshkov, E.F. Mikiashvili

The Turner Scientific Research Institute for Children's Orthopedics, Saint Petersburg, Russia

Received: 12.02.2018

Accepted: 09.04.2018

Introduction. Shoulder internal rotation contracture is the most common deformity affecting the shoulder in patients with obstetric brachial plexus palsy because of the subsequent imbalance of the musculature and the abnormal deforming forces that cause dysplasia of the glenohumeral joint.

Aim. To assess the effects of tendon transfers in children with shoulder internal rotation deformity due to obstetric brachial plexus palsy.

Materials and methods. From 2015 to 2017, we examined and treated 15 patients with shoulder internal rotation deformity caused by obstetric brachial plexus palsy. The children ranged in age from 4 to 17 years. We used clinical and radiographic examination methods, including magnetic resonance imaging, electromyography, and electroneuromyography, of the upper limbs.

Results. According to the level of plexus brachialis injury, the patients were divided into 3 groups: level C5–C6 (9 patients), level C5–C7 (5 children), level C5–Th1 (1 patient). All children had secondary shoulder deformities: glenohumeral dysplasia type II, 6 (40%); type III, 5 (34%); type IV, 1 (6%); and type V, 3 (20%). The Mallet score was used for estimation of upper limb function. Surgical treatment was performed in 15 children. After treatment, all patients showed improvement in activities of daily living.

Conclusion. Tendon transfers in patients with shoulder internal rotation deformities due to obstetric brachial plexus palsy improved upper limb function and provided satisfactory cosmetic treatment results without of remodeling of the glenohumeral joint.

Keywords: brachial plexus palsy; Erb's palsy; glenohumeral dysplasia; tendon transfers.

ИСПОЛЬЗОВАНИЕ СУХОЖИЛЬНО-МЫШЕЧНЫХ ПЛАСТИК ПРИ ЛЕЧЕНИИ ВНУТРИРОТАЦИОННОЙ КОНТРАКТУРЫ ПЛЕЧЕВОГО СУСТАВА У ДЕТЕЙ С ПОСЛЕДСТВИЯМИ РОДОВОГО ПОВРЕЖДЕНИЯ ПЛЕЧЕВОГО СПЛЕТЕНИЯ

© O.E. Агранович, А.Б. Орешков, Е.Ф. Микиашвили

ФГБУ «НИДОИ им. Г.И. Турнера» Минздрава России, Санкт-Петербург

Статья поступила в редакцию: 12.02.2018

Статья принята к печати: 09.04.2018

Введение. Вторичные деформации плечевого сустава — наиболее частая проблема у пациентов с родовыми повреждениями плечевого сплетения. По данным А.Ф. Ноекса et al. (2000), контрактуры плечевого сустава формируются у $\frac{1}{3}$ детей с акушерскими параличами с отсроченным неврологическим восстановлением (более 3 недель после травмы) и у $\frac{2}{3}$ пациентов с неполным восстановлением. При данном виде травмы наиболее часто наблюдается внутривротационная контрактура плечевого сустава, что обусловлено дисбалансом мышц, формированием дисплазии плечевого сустава.

Цель — изучить результаты сухожильно-мышечных пластик при лечении внутривротационной контрактуры плечевого сустава у детей с последствиями родового повреждения плечевого сплетения.

Материалы и методы. С 2015 по 2017 г. находились на обследовании и лечении 15 пациентов в возрасте от 4 до 17 лет с внутривротационной контрактурой плечевого сустава вследствие родового повреждения плечевого сплетения. Проводили клиническое, рентгенологическое, физиологическое исследование (ЭМГ и ЭНМГ верхних конечностей), МРТ плечевых суставов.

Результаты. По протяженности повреждения плечевого сплетения выделяли три группы пациентов: группа I (уровень C5–C6) — 9 человек, группа II (уровень C5–C7) — 5 человек и группа III (уровень C5–Th1) — 1 пациент. У всех пациентов выявлены вторичные деформации плечевого сустава: II типа по Waters — у 6 пациентов (40 %), III типа — у 5 больных (34 %), IV типа — у 1 ребенка (6 %) и V типа — у 3 больных (20 %). Функциональные возможности верхней конечности оценивали по шкале Mallet. При II–III типах гленоумеральной дисплазии функция плечевого сустава оценивалась преимущественно как хорошая, при IV–V типах — как плохая. Оперативное лечение было выполнено 15 пациентам в двух основных вариантах. После проведенного лечения во всех наблюдениях улучшилось самообслуживание пациентов.

Заключение. Выполнение сухожильно-мышечной пластики у пациентов с внутривротационными контрактурами плечевого сустава вследствие родового повреждения плечевого сплетения позволяет улучшить косметический вид конечности, а также ее функцию, однако ремоделирования плечевого сустава у детей старше 4 лет не происходит.

Ключевые слова: родовая травма плечевого сплетения; парез Эрба; гленоумеральная дисплазия; сухожильно-мышечные пластики.

Introduction

The frequency of damage to the brachial plexus during childbirth is approximately 0.4–4/1000 newborns [1–5]. About 70%–92% of patients have mild injuries, which they spontaneously recover from within 2 months after birth [4,5]. In the majority of patients with damage to the upper trunk and partial restoration of muscle strength in the first 2 months of life, complete neurological recovery occurs within 1–2 years of life before the ability to overcome the gravity of the limb. In cases where the function of the biceps is restored after 3 months of age, the limb rarely functions completely, without loss of muscle strength or joint movement. Clinical manifestations of injury to the brachial plexus during childbirth correlate with the type and level of damage, as well as the nature of treatment.

According to the classification given by Seddon and Sunderland, five types of peripheral nerve injuries are distinguished: neuropraxia (type I), axonotmesis (types II–IV), and neurotmesis (type V), or avulsion. In the case of preganglionic avulsion, the motor function of the limb is never restored, and this type of injury has a poor prognosis. Narakas et al. classified all injuries of the brachial plexus by length into four groups. Group I (or Erb's classic paresis) involves damage to C5–C6. Patients in this group make up 46% of all cases and have a good prognosis for restoring limb function. Group II involves damage to C5–C7 (30%). In patients in this group, the recovery prognosis is worse compared with group I. Group III is total plexopathy clinically represented by a dangling limb (20%). Group IV is total plexopathy in combination with Horner's syndrome [6].

If the brachial plexus is damaged at the level of C5–C6, in 80% of patients, there is an almost complete restoration of movement in the shoulder and elbow joints. The results of treatment of patients with trauma at the C5–C7 level are somewhat worse than in the patients in group I; however, as a result of rehabilitation, it is possible to achieve acceptable limb function (spontaneous recovery was noted in 60% of patients). With total damage to the brachial plexus (C5–Th1 level), a severe lesion of the extremity is observed, especially if the patient has Horner's syndrome, which is characterized by the involvement of the sympathetic nervous system and possibly nerve damage by avulsion [7].

Secondary deformities of the shoulder joint are the most common problem in patients with birth brachial plexus injuries. According to Hoeksma et al. (2000), shoulder joint contractures are formed in one-third of children with obstetric paralysis with delayed neurological recovery (more than 3 weeks after injury) and in two-thirds of patients with incomplete recovery [8]. In this type of injury, the intrarotation contracture of the shoulder joint is most common, which is combined with pronation contracture of the forearm, with varying degrees of manifestation [9, 10]. In patients with severe birth trauma of the brachial plexus, who do not achieve spontaneous recovery, in one-third of the cases, removal of the intrarotation contracture of the shoulder joint is required [11].

The methods of surgical treatment of this pathology described in the literature can be divided into the following five groups:

- 1) Muscular grafting and muscle release aimed at restoring the muscular balance between the external and internal shoulder rotators.

- 2) Restoration of anatomical relationships in the shoulder joint by performing different variants of osteotomy of the scapula and clavicle and repositioning of the humeral head.
- 3) Elimination of the vicious position of the limb without changing the ratio in the shoulder joint (de-rotation osteotomy of the humerus).
- 4) Muscular grafting in combination with de-rotation osteotomy of the humerus.
- 5) Muscular grafting in combination with osteotomy of the scapula [2, 6, 11–16].

In the case of fixed intrarotation contractures of the shoulder, Muhlig et al. (2001) recommend adhering to the following treatment algorithm:

- 1) Surgical treatment is indicated with passive external rotation less than 30°.
- 2) In the absence of posterior displacement of the humeral head, it is necessary to perform release of the subscapularis (the so-called slide).
- 3) In the case of posterior displacement of the humeral head, elongation of the subscapularis from the anterior approach is indicated, in combination with resection of the coracoid process of the scapula in the case of its elongation.
- 4) If, in the case of elongation of the subscapularis, there is a relapse of the intrarotation contracture, this intervention must be supplemented by transposition of the muscles to create active external rotation of the shoulder.
- 5) In the absence of signs of re-innervation of the infraspinatus muscle in children aged 2 years or older, elongation of the subscapularis with simultaneous restoration of active external rotation of the shoulder is indicated by muscle transplantation.
- 6) With fixed intrarotation contractures in the shoulder joint, in combination with posterior shoulder dislocation and deformity of the glenoid, elongation of the subscapularis in combination with de-rotation osteotomy of the humerus is indicated [13].

According to Waters and Bae (2005), tendinous muscular grafting (transposition of the broadest muscle of the back and the teres major to the external shoulder rotators with or without simultaneous elongation of the muscles) enables significant improvement of the function of the shoulder joint and impedes the progression of dysplasia of the shoulder joint; however, the joint

is not remodeled, even if surgery is performed in a patient at an early age [12]. Dodwell et al. (2012) recommend osteotomy of the neck of the scapula with installation of an autograft from the scapular spine or the acromion, in conjunction with sliding of the subscapularis and transpositioning of the broadest muscle of the back and the teres major to the external shoulder rotators [16]. This surgery, in most cases, enables changing of the position of the articular surface of the scapula in space without remodeling its joint surface. De-rotation osteotomy of the humerus only leads the limb to a more functional position, but it does not change the condition of the shoulder joint. According to Dodwell et al. (2012), de-rotation osteotomy of the humerus leads to further retroversion of the glenoid and progression of posterior displacement of the humeral head and is therefore indicated only in older children with severe dysplasia of the shoulder joint [16]. Progression of humeral head displacement, caused by the abnormal position and shape of the scapula and clavicle, requires a different correction. In the presence of hypoplasia, high position and rotation of the scapula (the so-called scapular hypoplasia, elevation, and rotation deformity), it is necessary to perform internal rotation of the acromion, osteotomy of the clavicle, resection of the upper-median scapula margin, and posterior capsulorrhaphia [11, 17].

A review of the literature demonstrates a lack of a unified therapeutic approach to intrarotation contracture of the shoulder joint in children because of a birth injury of the brachial plexus, which makes our research topic relevant.

This study analyzed the results of tendinous muscular grafting in treatment of intrarotation contracture of the shoulder joint in children because of a birth injury of the brachial plexus.

Material and methods

During 2015 to 2017, 15 pediatric patients aged 4 to 17 years (mean age: 11.4 ± 1.51 years) with intrarotation contracture of the shoulder joint because of a birth injury of the brachial plexus were examined and treated; seven of them were boys, and eight were girls. A right-sided lesion was noted in eight cases and a left-sided lesion in seven cases. Clinical, neurological, and radiologic studies (including computed tomography [CT] and magnetic

resonance imaging (MRI) of the shoulder joint) and physiological examination (electromyography and electroneuromyography of the upper extremities) were performed. The location of the glenoid was assessed by the method of Friedman et al. (1992), and the position of the humeral head was evaluated by the method of Waters et al. (1998) [18, 19]. The degree of dysplasia of the shoulder joint was determined on the basis of criteria proposed by Waters et al. (1998) [19]. All patients and/or their legal representatives voluntarily signed informed consent to participate in the study and to allow us to perform surgical intervention and publish personal data.

Results

In terms of the extent of damage to the brachial plexus (according to electroneuromyography and clinical and neurological examination), we divided the patients into three groups: group I (C5–C6 level, or classical Erb's palsy) included nine patients, group II (C5–C7 level, extensive variant of Erb's palsy) included five patients, and group III (C5–Th1 level, total plexopathy) included one patient. All patients received conservative treatment from the first day of life, and neurosurgical surgeries were not performed in any case.

When assessing the degree of dysplasia of the shoulder joint by CT and MRI, we found that in children under the age of 12 years, there were mainly minor changes in the glenoid, without a change in the position of the humeral head. However, patients aged 13–17 years had marked changes in the glenoid, in combination with changes in the position

of the humeral head (Waters types IV–V dysplasia). Waters type II dysplasia was found in six patients (40%), type III was noted in five patients (34%), type IV was seen in one patient (6%), and type V was registered in three patients (20%). Glenoid retroversion amounted to 14.33 ± 2.72 .

In clinical studies, we noted the intrarotation position of the upper limb, a marked restriction (no more than 20°) or complete absence of external rotation of the shoulder and impossibility of placing the arm behind the head. When the patient attempted to raise a hand to the mouth, we observed shoulder abduction (the so-called trumpeter symptom), which was due to a pathological co-contraction between the biceps and the deltoid muscle (Figure 1). Internal rotation of the shoulder joint was more often preserved, less often restricted (mainly in Waters types IV–V dysplasia). Functionality of the upper limb was assessed on the Mallet scale. In Waters types II–III dysplasia, despite the vicious position of the limb, the function of the shoulder joint was assessed mainly as good (9–11 points); with Waters types IV–V dysplasia, the joint's function was assessed as poor (7–8 points). Adduction intrarotation contracture in the shoulder joint was noted in five patients, whereas isolated intrarotation contracture was revealed in ten patients.

Surgical treatment was performed in 15 patients in two main variants. In the case of passive or the absence of active external rotation of the shoulder joint, the broadest muscle of the back was transposed to the external shoulder rotators (four patients). When passive correction of the shoulder to the middle position was impossible, release of

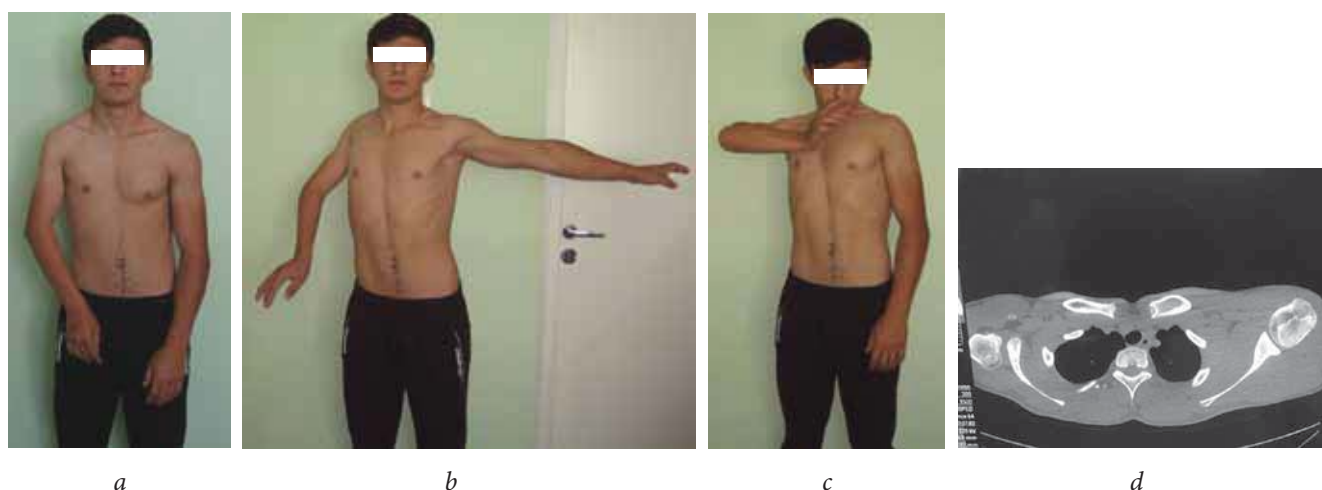


Fig. 1. Adduction intrarotation contracture of the right shoulder joint in patient B, 17 years old, because of a birth injury of the brachial plexus before treatment: (a) appearance of the patient, (b) abduction in the shoulder joints, (c) positive trumpeter symptom on the right, and (d) CT of shoulder joints

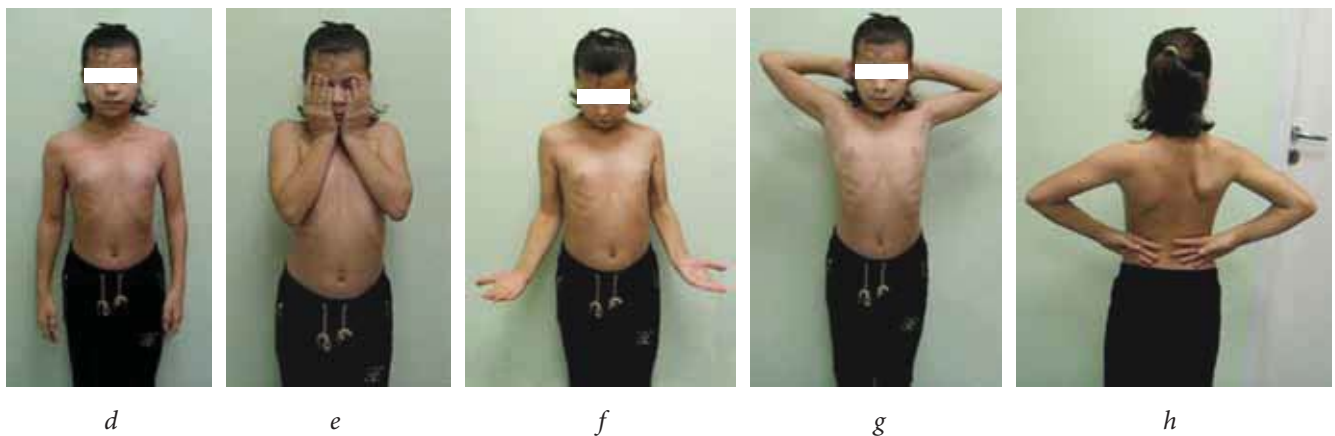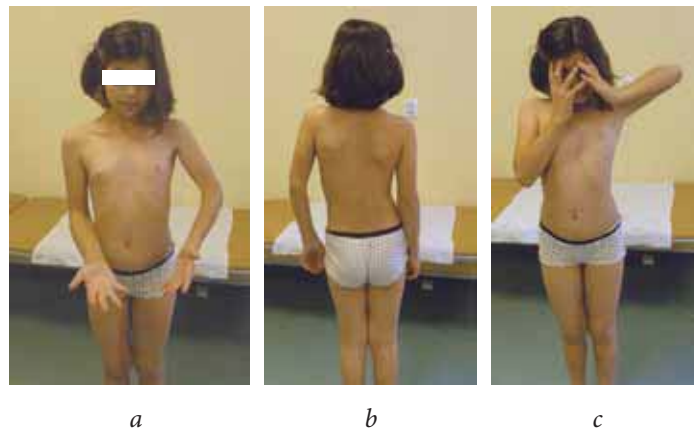


Fig. 2. Result of eliminating intrarotation contracture of the left shoulder joint in patient B, 12 years old, because of a birth injury of the brachial plexus before treatment: (a–c) before surgery and (d–h) after surgery (transposition of the broadest muscle of the back to the outer shoulder rotators and dissection of the *coracohumeral ligament*)

the subscapularis (slide) was performed together with transposition of the broadest muscle of the back to the external shoulder rotators. In cases where there was tension in the *musculus pectoralis major* and restriction of abduction in the shoulder joint, tenotomy was performed. In the postoperative period, the limb was immobilized with a plaster cast with a thoracobrachial bandage for 5 weeks. At the end of immobilization, restorative treatment was prescribed to the patients, which included exercise therapy, massage, mechanotherapy, and muscle electrostimulation.

The patients' follow-up period was from 2 months to 1 year after surgery. In all cases, it was possible to eliminate the vicious position of the limb and improve limb functionality for all types of glenohumeral dysplasia by an average of 2 points on the Mallet scale. The trumpeter symptom was less pronounced when the patients tried to raise a hand to the mouth (Figure 2). Transposition of the broadest muscle of the back to the external shoulder rotators led to improvement of external rotation without worsening internal rotation of the shoulder joint. In the same cases, when the subscapularis was released,

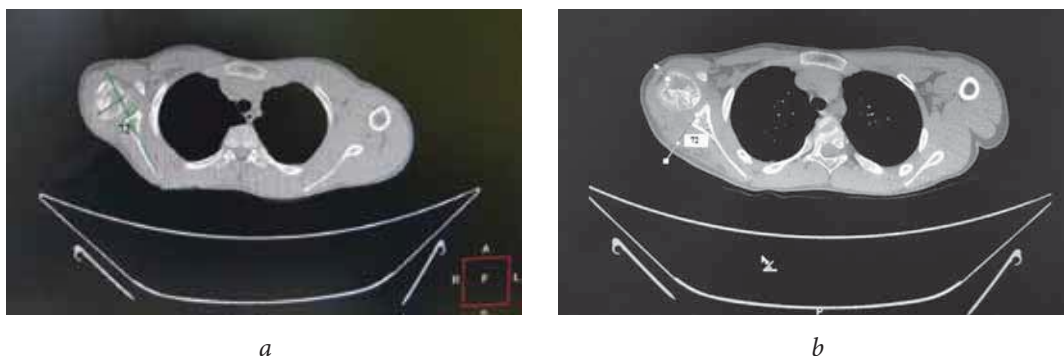


Fig. 3. Results of a CT examination of patient M, 12 years old, with a birth injury of the brachial plexus with intrarotational contracture of the right shoulder joint: (a) before surgery and (b) 3 months after surgery

the restriction of internal rotation of the shoulder joint was noted, which required a more prolonged restorative treatment to achieve postoperative values.

The correlation between the degree of glenohumeral dysplasia and the results of treatment was revealed: at Waters type II dysplasia after surgery, limb functionalities improved by 3–5 points; at type III, they improved by 2–4 points; and at types IV–V, they improved by 1–2 points. In patients with adduction intrarotation contracture after surgery, improvement in abduction in the shoulder joint was noted in all cases. Examination revealed that the ratios in the shoulder joint improved or remained unchanged; however, there was no remodeling of the joint surfaces (Figure 3).

Discussion

Intrarotation contracture of the shoulder joint is one of the most frequent secondary deformities because of a birth injury of the brachial plexus and results in severe restriction or impossibility of performing basic self-care actions: using the hand while eating, combing hair, dressing, washing, etc. The cause of intrarotation contracture is shortening of the *subscapularis* because of disruption of its growth caused by loss of cyclic stretching due to paralysis of external shoulder rotators. The intrarotation position of the limb leads to displacement of the head of the humerus posteriorly, and movement in the joint deteriorates. In the absence of treatment in children with a birth injury of the brachial plexus, severe anatomical changes in the head of the humerus and scapula occur with age. The loss of passive external rotation of the shoulder joint indicates posterior dislocation of the humeral head [5, 14]. At that, the first changes in the shoulder joint are found at the age of 3–5 months, whereas the expressed ones are revealed already at the second or third year of life. Primary deformities of the shoulder joint are due to imbalance of the muscles of the shoulder girdle caused by paralysis of the external rotators and abductor muscles of the shoulder, in combination with relative hyperactivity of the internal rotators and adductor muscles of the shoulder because of neurological disorders [20–22]. In the future, secondary deformities are formed, including progression of retroversion of the glenoid, thinning or absence of the posterior edge of the glenoid, posterior subluxation or dislocation of the humeral

head, hypoplasia of the scapula, flattening or absence of the glenoid cavity of the scapula, retrodeviation and an increase in the size of the coracoid process of the scapula, acromion deformity, deformity and hypoplasia of the humeral head, delay in ossification of the proximal humerus, and shortening of the clavicle on the side of the lesion [5, 21, 23]. The humeral head eventually turns into a retroversion position, which was described by both E.A. Zancolli and E.E. Zancolli (2000) as posterior epiphysiolysis of the humeral head [24]. The vicious position of the humeral head rises for the second time, rotates the scapula, and lengthens the acromion, which leads to severe functional disorders in the shoulder joint [11]. According to Pearl and Edgerton (1998), in 70% of patients with intrarotation contracture, dysplasia of the shoulder joint occurs [25].

Our examination of 15 children with a birth injury of the brachial plexus and intrarotation contracture in the shoulder joint revealed that children aged 12 years and older develop severe anatomical changes in the shoulder joint with the occurrence of Waters types IV–V dysplasia. Due to the implementation of tendinous muscular grafting in patients with intrarotation contracture in the shoulder joint, caused by a birth injury of the brachial plexus, it is possible to eliminate the vicious position of the limb and improve the possibility of self-service by patients.

Conclusions

Tendon and muscle grafting in patients with intrarotational contracture in the shoulder joint because of intranatal damage to the brachial plexus enables elimination of the vicious position of the limb and improvement of the possibility of self-service without significant loss of internal rotation. These interventions improve the ratio in the shoulder joint; however, no joint remodeling occurs in children over 4 years. In the same cases, when these surgeries do not provide a proper result, the second stage should be performed as a de-rotation osteotomy of the humerus.

Funding and conflict of interest

The work was performed in the Turner Scientific Research Institute for Children's Orthopedics. The authors declare no obvious and potential conflicts of interest related to the publication of this article.

References

1. Laurent JP, Lee R, Shenaq S, et al. Neurosurgical correction of upper brachial plexus birth injuries. *J Neurosurg.* 1993;79(2):197-203. doi: 10.3171/jns.1993.79.2.0197.
2. Waters PM. Obstetric Brachial Plexus Injuries: Evaluation and Management. *J Am Acad Orthop Surg.* 1997;5(4):205-214.
3. Hoeksma AF, ter Steeg AM, Nelissen RG, et al. Neurological recovery in obstetric brachial plexus injuries: an historical cohort study. *Dev Med Child Neurol.* 2004;46(2):76-83. doi: 10.1017/S0012162204000179.
4. Foad SL, Mehlman CT, Ying J. The epidemiology of neonatal brachial plexus palsy in the United States. *J Bone Joint Surg Am.* 2008;90(6):1258-1264. doi: 10.2106/JBJS.G.00853.
5. Chagas-Neto FA, Dalto VF, Crema MD, et al. Imaging assessment of glenohumeral dysplasia secondary to brachial plexus birth palsy. *Radiol Bras.* 2016;49(3):144-149. doi: 10.1590/0100-3984.2015.0039.
6. Hale HB, Bae DS, Waters PM. Current concepts in the management of brachial plexus birth palsy. *J Hand Surg.* 2010;35(2):322-331. doi: 10.1016/j.jhsa.2009.11.026.
7. Buterbaugh KL, Shah AS. The natural history and management of brachial plexus birth palsy. *Curr Rev Musculoskelet Med.* 2016;9(4):418-426. doi: 10.1007/s12178-016-9374-3.
8. Hoeksma AF, Wolf H, Oei SL. Obstetrical brachial plexus injuries: incidence, natural course and shoulder contracture. *Clin Rehabil.* 2000;14(5):523-526. doi: 10.1191/0269215500cr341oa.
9. Birch R. Obstetric brachial plexus palsy. In: The growing hand. Ed by A. Gupta, S.P.J. Kay, L.R. Schecker. Philadelphia: Mosby; 2000. P. 461-474.
10. Birch R. Medial rotation contracture, posterior dislocation of the shoulder. In: Brachial plexus injuries. Ed by A. Gilbert. Hampshire (UK): Taylor & Francis; 2001. P. 249-259.
11. Nath RK, Melcher SE, Paizi M. Surgical correction of unsuccessful derotational humeral osteotomy in obstetric brachial plexus palsy: evidence of the significance of scapular deformity in the pathophysiology of the medial rotation contracture. *J Brachial Plex Peripher Nerve Inj.* 2006;1:9. doi: 10.1186/1749-7221-1-9.
12. Waters PM, Bae DS. Effect of tendon transfers and extra-articular soft-tissue balancing on glenohumeral development in brachial plexus birth palsy. *J Bone Joint Surg Am.* 2005;87(2):320-325. doi: 10.2106/JBJS.C.01614.
13. Muhlig RS, Blaauw G, Slooff ACJ, et al. Conservative treatment of obstetrical brachial plexus palsy (OBPP) and rehabilitation. In: Brachial Plexus Injuries. Ed by A. Gilbert. London: Martin Dunitz Ltd; 2001. P. 173-183.
14. Al-Qattan MM. Classification of secondary shoulder deformities in obstetric brachial plexus palsy. *J Hand Surg Eur Vol.* 2003;28(5):483-486. doi: 10.1016/S0266-7681(02)00399-6.
15. Nath RK, Liu X, Melcher SE, Fan J. Long-term outcomes of triangle tilt surgery for obstetric brachial plexus injury. *Pediatr Surg Int.* 2010;26(4):393-399. doi: 10.1007/s00383-010-2550-4.
16. Dodwell E, O'Callaghan J, Anthony A, et al. Combined glenoid anteversion osteotomy and tendon transfers for brachial plexus birth palsy: early outcomes. *J Bone Joint Surg Am.* 2012;94(23):2145-2152. doi: 10.2106/JBJS.K.01256.
17. Nath RK, Somasundaram C. Improvements after modified Quad and triangle tilt revision surgical procedures in obstetric brachial plexus palsy. *World J Orthop.* 2016;7(11):752-757. doi: 10.5312/wjo.v7.i11.752.
18. Friedman RJ, Hawthorne KB, Genes BM. The use of computerized tomography in the measurement of glenoid version. *J Bone Joint Surg Am.* 1992;74(7):1032-1037.
19. Waters PM, Smith GR, Jaramillo D. Glenohumeral deformity secondary to brachial plexus birth palsy. *J Bone Joint Surg Am.* 1998;80(5):668-677.
20. Ruchelsman DE, Grossman JA, Price AE. Glenohumeral deformity in children with brachial plexus birth injuries. *Bull NYU Hosp Jt Dis.* 2011;69(1):36-43.
21. van der Sluijs JA, van Ouwerkerk WJ, de Gast A, et al. Deformities of the shoulder in infants younger than 12 months with an obstetric lesion of the brachial plexus. *J Bone Joint Surg Br.* 2001;83(4):551-555. doi: 10.1302/0301-620X.83B4.11205.
22. Soldado F, Benito-Castillo D, Fontecha CG, et al. Muscular and glenohumeral changes in the shoulder after brachial plexus birth palsy: an MRI study in a rat model. *J Brachial Plex Peripher Nerve Inj.* 2012;7(1):9. doi: 10.1186/1749-7221-7-9.
23. Kozin SH. Correlation between external rotation of the glenohumeral joint and deformity after brachial plexus birth palsy. *J Pediatr Orthop.* 2004;24(2):189-193. doi: 10.1097/00004694-200403000-00011.
24. Zancolli EA, Zancolli ER. Reconstructive surgery in brachial plexus sequelae. In: The growing hand. Ed by A. Gupta, S.P.J. Kay, L.R. Schecker. London: UK: Mosby; 2000. P. 805-823.
25. Pearl ML, Edgerton BW. Glenoid deformity secondary to brachial plexus birth palsy. *J Bone Joint Surg Am.* 1998;80(5):659-667.

Information about the authors

Olga E. Agranovich — MD, PhD, Professor, Head of the Department of Arthrogyposis. The Turner Scientific Research Institute for Children's Orthopedics, Saint Petersburg, Russia. E-mail: olga_agranovich@yahoo.com. ORCID: <https://orcid.org/0000-0002-6655-4108>.

Anatoly B. Oreshkov — MD, PhD, Orthopedic and Trauma Surgeon of the Department of Arthrogyposis. The Turner Scientific Research Institute for Children's Orthopedics, Saint Petersburg, Russia. ORCID: <https://orcid.org/0000-0002-2946-1850>.

Evgeniya F. Mikiashvili — MD, Orthopedic and Trauma Surgeon of the Department of Arthrogyposis. The Turner Scientific Research Institute for Children's Orthopedics, Saint Petersburg, Russia.

Ольга Евгеньевна Агранович — д-р мед. наук, руководитель отделения артрогрипоза ФГБУ «НИДОИ им. Г.И. Турнера» Минздрава России, Санкт-Петербург. E-mail: olga_agranovich@yahoo.com. ORCID: <https://orcid.org/0000-0002-6655-4108>.

Анатолий Борисович Орешков — д-р мед. наук, врач травматолог-ортопед отделения артрогрипоза ФГБУ «НИДОИ им. Г.И. Турнера» Минздрава России, Санкт-Петербург. ORCID: <https://orcid.org/0000-0002-2946-1850>.

Евгения Федоровна Микиашвили — врач травматолог-ортопед отделения артрогрипоза ФГБУ «НИДОИ им. Г.И. Турнера» Минздрава России, Санкт-Петербург.