

DOI: <https://doi.org/10.17816/uroved115220>

Research Article



# Multi-stage surgery for anterior urethral strictures: assessment of immediate and long-term surgical outcomes

Mikhail I. Kogan, Vladimir P. Glukhov, Anna V. Ilyash, Valeriy V. Mitusov, Oleg N. Vasiliev

Rostov State Medical University, Rostov-on-Don, Russia

**BACKGROUND:** The progress made in reconstructive urethral surgery over the past 20 years has shown the effectiveness of one-stage repair of anterior urethral strictures. Nevertheless, multi-stage urethroplasty retains its primary role in the treatment of patients with the most complex urethral narrowing and obliterations.

**AIM:** To evaluate the immediate and long-term surgical results of multi-stage urethroplasty for penile and bulbar urethral strictures.

**MATERIALS AND METHODS:** The study included 110 men aged 18–84 years who underwent multi-stage urethroplasty for the anterior urethral structures in 2010–2019. The techniques of buccal and skin augmentation or urethral replacement plastics were applied. Before surgery, all patients underwent a standard urological examination. Early surgical complications were evaluated from medical records. Late surgical complications were determined according to examinations that included symptomatic assessment with specialized questionnaires, laboratory tests of serum and urine, physical examination, uroflowmetry, and retrograde urethrography and ureteroscopy (if urinary disorders were detected). The median follow-up was 5 years and 2 months.

**RESULTS:** Early surgical complications were detected in 27 (24.5%) patients. Surgical interventions to resolve them were required in 7 (31.8%) cases: urethrocutaneous fistulas (5), acute urinary retention (1), scrotal hematoma (1). Late surgical complications were detected in 33 (30.0%) patients, including 29 (26.7%) cases of recurrent urethral strictures. All late complications cases were classified as Clavien–Dindo IIIb, and a total of 49 additional operations were performed to eliminate them. The primary success rate for multi-stage urethroplasty was 67.3 % with a median follow-up of 62 months. Only 73 (66.4%) completed all stages of the planned surgery. Urethral integrity throughout its entire length was restored in 67 (60.9%) cases, spontaneous urination in 106 (96.4%) cases.

**CONCLUSIONS:** Multi-stage surgery for anterior urethral strictures is associated with relatively high risks of surgical complications at each stage of treatment. The probability of surgical revision of complications can reach 31.8%. Patients should be informed about the risks of developing surgical complications and the potential for more than two surgeries to achieve treatment goals when planning multi-stage urethroplasty.

**Keywords:** urethral stricture; anterior urethra; multi-stage urethroplasty; treatment success; surgical complications; recurrence.

**To cite this article:**

Kogan MI, Glukhov VP, Ilyash AV, Mitusov VV, Vasiliev ON. Multi-stage surgery for anterior urethral strictures: assessment of immediate and long-term surgical outcomes. *Urology reports (St. Petersburg)*. 2022;12(4):277–286. DOI: <https://doi.org/10.17816/uroved115220>

Received: 07.12.2022

Accepted: 12.12.2022

Published: 29.12.2022

DOI: <https://doi.org/10.17816/uroved115220>

Научная статья

## Многоэтапные операции при стриктурах передней уретры: оценка непосредственных и долгосрочных хирургических результатов

М.И. Коган, В.П. Глухов, А.В. Ильяш, В.В. Митусов, О.Н. Васильев

Ростовский государственный медицинский университет, Ростов-на-Дону, Россия

**Актуальность.** Несмотря на прогресс, достигнутый в реконструктивной хирургии уретры за последние 20 лет, и принимая во внимание тот факт, что значительная часть стриктур передней уретры может быть успешно восстановлена в один этап, многоэтапная уретропластика сохраняет свою первостепенную роль в лечении пациентов с наиболее сложными сужениями и облитерациями мочеиспускательного канала.

**Цель исследования** — оценить непосредственные и долгосрочные хирургические результаты многоэтапных уретропластик при пенильных и бульбарных стриктурах уретры.

**Материалы и методы.** В исследование включено 110 мужчин в возрасте 18–84 лет, которым в 2010–2019 гг. выполнена многоэтапная уретропластика по поводу стриктур передней уретры. Применены техники буккальных и кожных аугментационных или заместительных пластик уретры. Перед операцией все пациенты были подвергнуты стандартному урологическому обследованию. О развитии ранних хирургических осложнений судили по записям медицинских карт, о развитии поздних хирургических осложнений — по данным обследований, включавших мониторинг симптомов с помощью специализированных опросников, лабораторные тесты крови и мочи, физикальный осмотр, урофлоуметрию и при выявлении нарушений мочеиспускания — ретроградную уретрографию и уретроскопию. Медиана наблюдения составила — 5 лет 2 мес.

**Результаты.** Ранние хирургические осложнения выявлены у 27 (24,5 %) пациентов. Хирургические вмешательства по их разрешению потребовались в 7 (31,8 %) случаях — уретро-кожные свищи (5), острая задержка мочи (1), гематома мошонки (1). Поздние хирургические осложнения выявлены у 33 (30,0 %) пациентов, включая 29 (26,7 %) случаев рецидивов стриктур уретры. Все случаи поздних осложнений отнесены к IIIb классу по системе Clavien – Dindo, в общей сложности проведено 49 дополнительных операций по их устранению. Первичный успех многоэтапных уретропластик составил 67,3 % при медиане наблюдения 62 мес. Только 73 (66,4 %) пациента прошли все этапы планируемой хирургии. Целостность уретры на всем протяжении удалось восстановить в 67 (60,9 %) случаях, самостоятельное мочеиспускание — в 106 (96,4 %).

**Заключение.** Многоэтапная хирургия стриктур передней уретры сопряжена с относительно высокими рисками хирургических осложнений на каждом из этапов лечения. Вероятность хирургических ревизий осложнений может достигать 31,8 %. При планировании многоэтапной уретропластики следует информировать пациентов о рисках развития хирургических осложнений и потенциальной возможности проведения более двух операций для достижения цели.

**Ключевые слова:** стриктура уретры; передняя уретра; многоэтапная уретропластика; эффективность лечения; хирургические осложнения; рецидив стриктур.

### Как цитировать:

Коган М.И., Глухов В.П., Ильяш А.В., Митусов В.В., Васильев О.Н. Многоэтапные операции при стриктурах передней уретры: оценка непосредственных и долгосрочных хирургических результатов // Урологические ведомости. 2022. Т. 12. № 4. С. 277–286. DOI: <https://doi.org/10.17816/uroved115220>

## BACKGROUND

Strictures of the anterior urethra may be subject to resection, augmentation, or replacement techniques for urethroplasty, whereas single-stage surgical treatment is preferable [1–3]. However, in several patients with the most complex stricture and obliteration of the urethra, single-stage techniques have a high risk of failure or are not applicable at all [4, 5]. Mehra et al. [6] revealed that every tenth patient has at least one complicating factor detrimental to surgical outcomes and disallowing the implementation of a one-stage approach. Primarily, this includes the presence of pronounced changes in local tissues, such as massive spongiofibrosis caused by balanitis xerotica obliterans; cicatricial change of surrounding tissues after failed surgeries, including for hypospadias in children; extended obliteration of the urethra; urethrocutaneous fistulas; and abscess and infection of para-urethral tissues. In such cases, reconstructive urologists choose multi-stage surgery [7–9].

The efficiency rates of multi-stage urethroplasty vary between 20% and 100% [10–12]. Such a wide range of data is quite possibly due to differences in patient characteristics, plastic materials and techniques used, and criteria for evaluating efficiency. In this article, we present our 10-year experience of staged surgical treatment of patients with spongy urethral strictures.

*The study aimed* to evaluate the immediate and long-term surgical results of multi-stage urethroplasty for penile and bulbar urethral strictures.

## MATERIALS AND METHODS

This single-center, retrospective, observational, uncontrolled study included patients who underwent surgery in 2010–2019. The study was approved by the local independent ethics committee of the Rostov State Medical University (Protocol No. 13/21 dated September 09, 2021).

*The inclusion criteria* were as follows: age  $\leq 18$  years, strictures located in the spongy part of the urethra, and multi-stage urethroplasty surgery. *The exclusion criteria* were as follows: strictures of the proximal urethra (membranous and prostatic), stenoses of the urethrovesical anastomosis and bladder neck, previously untreated congenital anomalies (hypospadias and epispadias), and any other urethral surgery that does not meet the inclusion criteria. The primary endpoint of the study was the early occurrence of surgical complications at various stages of treatment, and the secondary endpoint was the detection of late surgical complications, including stricture recurrence, which was defined as the urethra stricture that developed after the final stage of urethroplasty and characterized by a decrease in the maximum urine flow rate of  $<10$  mL/s, with an increase in the volume

of residual urine of  $>50$  mL, which were confirmed by radiological and/or endoscopic methods of evaluation and required repeated intervention (bougieurage, catheterization, and surgery).

*Perioperative evaluation of the patients.* Before surgery, all patients underwent a standard urological examination, which included a detailed analysis of complaints and case history, physical examination, laboratory blood and urine tests, ultrasound examination of the urinary system, and uroflowmetry. The extent, localization, and degree of stricture narrowing were assessed by urethro-cystography and/or urethrocystoscopy.

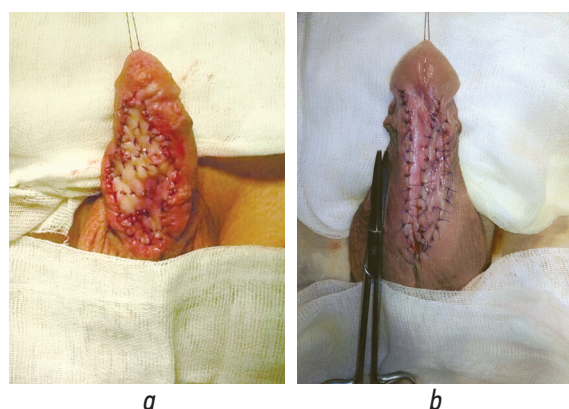
The development of early surgical complications was determined based on the medical records, and that of late surgical complications, including disease recurrence, was determined according to examinations performed 3, 6, and 12 months after surgery during the first year of monitoring and then annually. When necessary, patients contacted the clinic beyond the scheduled visits. Follow-up included monitoring of symptoms using specialized questionnaires, laboratory blood and urine tests, physical examination, uroflowmetry, and, if urinary disorders were detected, retrograde urethrography and ureteroscopy to assess the causes of obstructive micturition. The average follow-up period was  $63.6 \pm 33.11$  (9–131) months, with a median of 5 years 2 months.

*Surgical techniques.* The study used staged techniques for dermal and buccal urethroplasty. In multifocal lesions of the urethra, multi-stage surgery could combine dermal and buccal techniques and was also supplemented by the use of the vaginal tunic of the testis or resection techniques.

During surgery using skin flaps, at stage 1, marsupialization of the urethra was performed; at stage 2, either a longitudinal islet ventral flap on the feeding *dartos fascia* (Orandi) or the Johanson technique was used. In some cases, with bulbous strictures or bulbopenile strictures, the scrotum skin was used at stage 2 according to the modified methods of Orandi–Kogan, Duplay, or Denis Broun.

In surgery using a graft of the oral mucosa, replacement or augmentation plasty was performed through the ventral sagittal urethrotomy approach (Fig. 1). Variants of stages and their combinations (1, marsupialization of the urethra or excision of the modified urethra; 2, graft fixation; and 3, tubularization of the urethra) depended on the severity of inflammatory changes in the urethra, state of the paraurethral tissues, presence or absence of the urethral platform, and degree of the narrowing and length of the stricture.

*Statistical analysis.* Data processing was performed using the SPSS Statistics version 26.0 (IBM Corp., Armonk, NY, USA). The descriptive characteristics of the indicators were calculated, and the subordination of the indicators to the normal distribution law was tested.



**Fig. 1.** Fixation of the buccal graft in multi-stage surgery: *a* — substitution technique; *b* — augmentation technique

**Рис. 1.** Фиксация буккального графта при многоэтапной хирургии: *a* — заместительная техника; *b* — аугментационная техника

For quantitative indicators with a normal distribution, the arithmetic means, root-mean-square deviation ( $M \pm SD$ ), and range of maximum and minimum values (min–max) were calculated; in other cases, medians and interquartile range ( $Me [Q_1; Q_3]$ ) were calculated. For qualitative indicators, absolute ( $n$ ) and relative frequencies (%) were estimated. The functions of the relapse-free course and the calculation of the cumulative probability of developing a relapse were examined using the Kaplan–Meier test.

## RESULTS

The study included 110 patients who underwent staged augmentation or replacement urethroplasty for anterior urethral strictures in the Urology Clinic of the Rostov State Medical University in 2010–2019.

**Table 1.** Patient characteristics ( $n = 110$ )

**Таблица 1.** Характеристики пациентов ( $n = 110$ )

Indicators		Values
Age, Years, $M \pm SD$ (min–max)		44.15 $\pm$ 14.64 (18–84)
Length of the urethral stricture, cm, $Me [Q_1; Q_3]$		6.5 [4.8; 9.1]
Disease duration, years, $Me [Q_1; Q_3]$		5.5 [1; 12.5]
Previous surgery for urethral stricture, $n$		62 (56.4%)
Cystostomy, $n$		36 (32.7%)
Etiology of the urethral stricture, $n$	traumatic	18 (16.4%)
	inflammatory	38 (34.5%)
	iatrogenic	39 (35.5%)
	idiopathic	15 (13.6%)
Localization of the urethral stricture, $n$	penile	51 (46.4%)
	penile bulbous	25 (22.7%)
	bulbous	11 (10.0%)
	multifocal	23 (20.9%)

The clinical characteristics of the patients are presented in Table 1.

In this study, 73 (66.4%) of 110 patients completed all stages of the planned surgery to restore the urethra, and 37 (33.6%) completed treatment at stage 1 or intermediate stages. Urethroplasty was not completed because the patient refused to continue treatment due to satisfaction with the quality of urination achieved at the stage of formation of a temporary urethrostomy (83.8%) or high risks of complications and poor outcomes of subsequent surgery (10.8%). The development of life-threatening complications of concomitant diseases caused incomplete urethroplasty in 5.4% of the cases.

As regards early surgical complications, urethrocutaneous fistulas were common, and they were registered in 21 (19.1%) patients (21/27%–77.8%), whereas only 5 (4.5%) required excision and suturing of the fistula with Clavien–Dindo class IIIb of complications. The Clavien–Dindo class III of complications was registered in 1 (0.9%) case (1/27%–3.7%) of encysted hematoma of the scrotum, which required revision with drainage, and 1 (0.9%) case (1/27%–3.7%) of acute urinary retention after stage 1 of urethroplasty, which required surgical correction of the neomeatus. Other complications (pollakiuria, acute urethritis, and infectious and inflammatory changes in the postoperative wound) did not require additional measures to eliminate them or were stopped conservatively with Clavien–Dindo classes I–II (Table 2).

The majority (21/27%–77.8%) of early surgical complications were registered in patients who had completed multi-stage urethroplasty after urethral tubularization (17/27%–63.0%) or urethral tubularization with simultaneous buccal graft fixation (4/27%–14.8%).

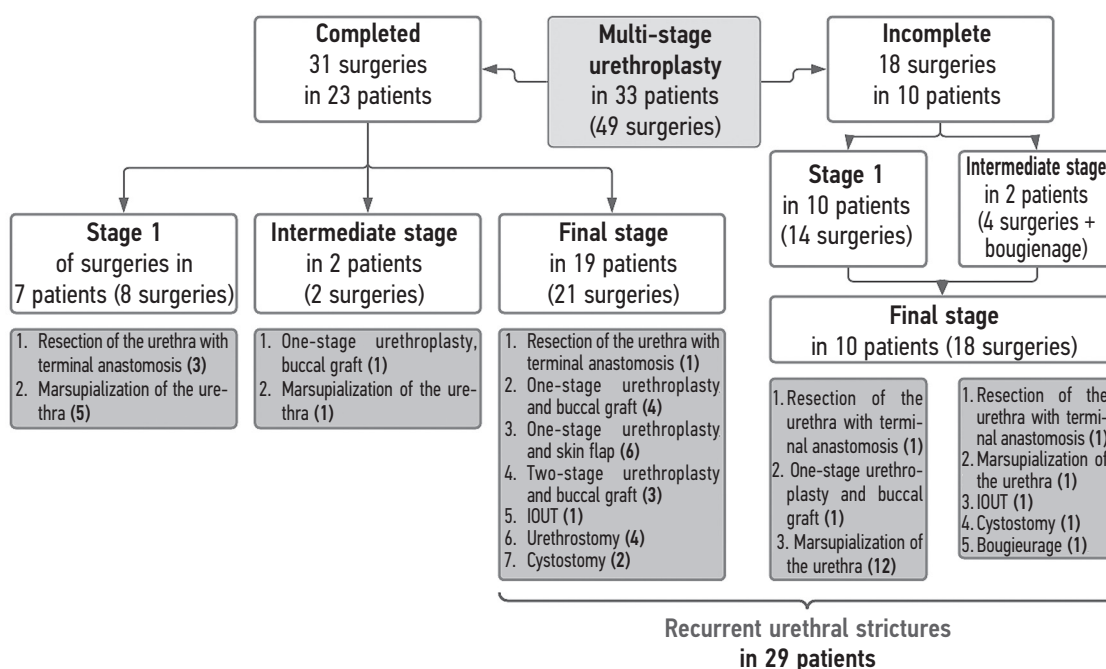
**Table 2.** Early surgical complications in multi-stage urethroplasty according to Clavien–Dindo**Таблица 2.** Оценка ранних хирургических осложнений при многоэтапной уретропластике по классификации Clavien – Dindo

Complications		Treatment measures	n
I	Pollakiuria	Preservation of the cystostome	1 (0.9%)
	Urethral–cutaneous fistula	Prolongation of bladder drainage	9 (8.2%)
II	Acute urethritis	Antibacterial therapy. Prolongation of the preservation of cystostomy drainage	1 (0.9%)
	Wound infection	Antibacterial therapy	2 (1.8%)
	Urethral-cutaneous fistula	Antibacterial therapy, instillation of the urethra with an antiseptic solution, and prolongation of the terms of preservation of the urethral catheter	7 (6.4%)
IIIa	Hematoma of the scrotum	Revision and drainage of the scrotum	1 (0.9%)
IIIb	Urethral-cutaneous fistula	Excision and suturing of the fistula	5 (4.5%)
	Acute urinary retention	Neomeatus correction	1 (0.9%)

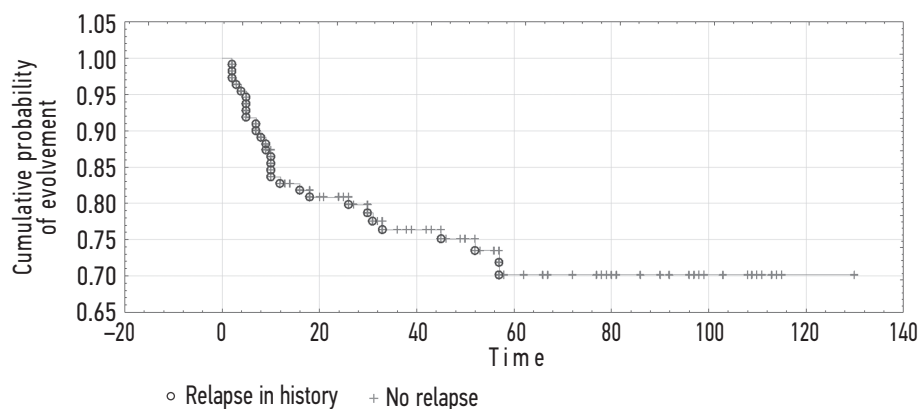
**Long-term results.** With further monitoring at various stages of urethroplasty, 33 (30.0%) patients who had ankylourethria were subjected to repeated surgical interventions. In addition, in 5 (4.5%) of these cases, the disease course was complicated by partial fibrosis of the buccal graft, formation of urethral–cutaneous fistulas, infectious and inflammatory infiltrates of paraurethral tissues, and urethral stones, which occurred in both isolation and combination. All late complications were classified as Clavien–Dindo class IIIb, and a total of 49 additional surgeries were performed to eliminate them (Fig. 2). Moreover, ankylourethria was diagnosed in 22.6% (7/31)

of patients who received only one-stage of treatment, 27.0% (15/63) of patients who underwent two stages, and 56.3% (9/16) of patients who underwent three or more stages. Urethral narrowing was detected in 40.7% (11/27) of patients in multi-stage urethroplasties using skin flaps and 28.1% (16/57) of cases when using buccal grafts.

Ankylourethria that developed after the final stage of urethroplasty was regarded as a recurrence of urethral strictures, and ankylourethria that occurred after stage 1 or intermediate stages of surgery was considered disease progression associated with the inadequate intraoperative assessment of the fibrous zone.

**Fig. 2.** A flowchart showing the correlation of the urethral narrowing formation with urethroplasty stages and surgical interventions types aimed at their elimination

**Рис. 2.** Блок-схема соотношения развития сужений уретры с этапами уретропластик и виды хирургических вмешательств, направленных на их разрешение. БОУТ — внутренняя оптическая уретротомия



**Fig. 3.** Kaplan–Mayer multiplier score for patients undergoing multi-stage urethroplasty

**Рис. 3.** Оценка сроков развития рецидивов уретры по кривой Каплана – Мейера для пациентов подвергнутых многоэтапной уретропластике

**Table 3.** Surgical outcomes of multi-stage urethroplasty for spongy urethral strictures

**Таблица 3.** Хирургические результаты многоэтапной уретропластики при стриктурах спонгиозной уретры

Indicators	Values
Complications including:	48 (43.6%)
• early	27 (24.5%)
• late	33 (30.0%)
Relapses	29 (26.7%)
Primary efficiency	74 (67.3%)
Reconstruction of the urethra	67 (60.9%)
Recovery of urination	106 (96.4%)

Based on this definition, stricture recurrence was diagnosed in 29 (26.7%) patients. The greatest risk of disease recurrence was noted during the first months of the follow-up. The minimum cumulative probability of recurrence was 0.7 and remains constant after 60 months of follow-up (Fig. 3).

In general, surgical complications were registered in 48 (43.6%) patients. Moreover, both early and late complications were noted in 12 (10.9%) cases, and surgical interventions were required in 35 (31.8%) cases. However, 4 (3.6%) patients failed to restore natural urination. The primary success rate of multi-stage urethroplasty, defined as the absence of surgical complications requiring repeated surgeries on the urethra and/or permanent bougieunage, was 67.3% of successful urinary restorations at a median follow-up of 62 months. The main indicators of the surgical efficiency of multi-stage urethroplasty for spongy urethral strictures are presented in Table 3.

## DISCUSSION

Nowadays, almost every case of multi-stage urethral surgery is based on the original Johanson technique, developed back in the 1950s. The general principle of this

technique consists of the fact that the affected urethra is dissected first in the longitudinal direction, and the created edges of the urethra are then sutured to the skin of the penis or scrotum, depending on the stricture location. Thus, the narrowed urethra remains open, and the neomeatus is displaced proximally in a hypospadias position. This is considered stage 1 of the Johanson surgery. Stage 2 of the Johanson surgery mainly consists of urethra retubularization around the urethral catheter and is performed no earlier than 3 months after stage 1 [13]. After Johanson, surgeons Turner-Warwick (1968), Gil-Vernet (1966), and Blandy (1968) improved the technique of staged urethroplasty, but the same idea is always followed [14–16].

In some patients, the urethral plate may be of poor quality even several months after marsupialization. In these cases, it is necessary to dissect dorsally the fibrous or ischemic plate and enlarge the urethra using a free graft placed on the surface of the cavernous bodies [17–20]. The original technique of Bracka (1995) includes the excision of the scar tissue of the urethra and fixation of the graft at stage 1 of treatment [19], whereas modified techniques involve the use of a graft at stage 2 of surgery with simultaneous tubularization of the urethra [8, 21]. Proponents of modified techniques believe

that the use of the oral mucosa as dorsal “overlays” at stage 2 of treatment enables us to avoid the risks of graft contracture and retraction, which are often noted when using it at stage 1, explaining this by the physiological characteristics of the mucous membrane and requiring the presence of a moist environment, which cannot be ensured during graft fixation without its synchronous closure inside the urethral canal [8].

Although classically referred to as “two-stage” urethroplasty, this surgery may include more stages, because of its main techniques (1, marsupialization of the urethra; 2, excision of the altered urethra; 3, graft fixation; 4, tubularization of the urethra), depending on the clinical characteristics of cases, can be performed at different time intervals and theoretically require more than two stages. In addition, the rates of revisions necessary to eliminate complications occurring at different stages indicate that the two-stage urethroplasty may become multi-stage. For example, in a series of cases, the frequency of revisions due to graft shrinkage or any other causes reached 50% [22–24]. Given these circumstances, the term “staged urethroplasty” or “multi-stage urethroplasty” was suggested [22, 25]. The use of this terminology will also contribute to the formation of more realistic expectations in patients regarding the treatment duration. Furthermore, only half (according to some data, only a third) of the respondents undergo stage 2 of surgery [26].

## CONCLUSION

Multi-stage surgery for anterior urethral strictures is associated with relatively high risks of surgical complications at each stage of treatment, with rates of early and late surgical complications of 24.5% and 30.0%,

respectively, including recurrence of strictures diagnosed in 26.7% of cases. The primary efficacy of multi-stage urethral surgery at a median follow-up of 62 months was 67.3%.

Only 66.4% of patients completed all stages of treatment, spontaneous urination was restored in 96.4% of cases, and urethral integrity was restored in 60.9%. When planning for multi-stage urethroplasty, patients should be informed about the risks of surgical complications and the high probability of additional stages of surgery to correct possible complications.

## ADDITIONAL INFORMATION

**Author contribution.** Thereby, all authors made a substantial contribution to the conception of the study, acquisition, analysis, interpretation of data for the work, drafting and revising the article, final approval of the version to be published and agree to be accountable for all aspects of the study. Contribution of each author: M.I. Kogan — research concept, research design development, scientific guidance, critical review, scientific editing; V.P. Glukhov — research design development, analysis and interpretation of the data obtained, text writing, surgical treatment, diagnostic studies; A.V. Ilyash — collection and processing of materials, literature review, writing text; V.V. Mitusov — analysis of the data obtained, critical review, surgical treatment, diagnostic studies; O.N. Vasiliev — critical review, surgical treatment, diagnostic studies.

**Competing interests.** The authors declare that they have no competing interests.

**Funding source.** This study was not supported by any external sources of funding.

**Ethics approval.** The study participants were informed about the objectives and methodology of the study and voluntarily provided written consent for their participation.

## REFERENCES

1. Goncharov NA, Kuznetsov AA, Morozov EA, Kiseleva AA. Results of surgical treatment on short-length bulbous urethral strictures. *Urology Herald*. 2021;9(1):32–38. (In Russ.) DOI: 10.21886/2308-6424-2021-9-1-32-38
2. Katibov MI, Alibekov MM, Magomedov ZM, et al. One-stage buccal two-flap urethroplasty using the Kulkarni technique for extended anterior urethral strictures. *Urology Herald*. 2020;8(4):44–52. (In Russ.) DOI: 10.21886/2308-6424-2020-8-4-44-52
3. Strotsky AK, Obrazkov KO, Raguzin AA. Extended urethral strictures — the experience of urethroplasty replacement. *Reproductive health. Eastern Europe*. 2019;9(5):628–636. (In Russ.)
4. Furr JR, Wisenbaugh ES, Gelman J. Long-term outcomes for 2-stage urethroplasty: an analysis of risk factors for urethral stricture recurrence. *World J Urol*. 2021;39(10):3903–3911. DOI: 10.1007/s00345-021-03676-8
5. Kogan MI, Glukhov VP, Ilyash AV, et al. Complex spongy urethral strictures with multi-stage treatment: predicting the recurrence risk. *Experimental and clinical urology*. 2022;15(1):136–141. (In Russ.) DOI: 10.29188/2222-8543-2022-15-1-136-141
6. Mehra A, Djaladat H, Salem S, et al. Outcome of buccal mucosal graft urethroplasty for long and repeated stricture repair. *Urology*. 2007;69(1):17–21. DOI: 10.1016/j.urology.2006.09.069
7. Kotov SV. Outcomes of multistage (substitutions) urethroplasty. *Experimental and clinical urology*. 2015;8(4):60–66. (In Russ.)
8. Joshi PM, Barbagli G, Batra V, et al. A novel composite two-stage urethroplasty for complex penile strictures: A multicenter experience. *Indian J Urol*. 2017;33(2):155–158. DOI: 10.4103/0970-1591.203426

9. Glukhov VP, Ilyash AV, Mitusov VV, et al. Clinical features of spongy urethral strictures requiring multi-stage urethroplasty or permanent urethrostomy. *Experimental and clinical urology*. 2021;14(3): 156–163. (In Russ.) DOI: 10.29188/2222-8543-2021-14-3-156-163
10. Kogan MI, Glukhov VP, Mitusov VV, et al. Comparative analysis of one- and two-stage augmentation urethroplasty with dorsal INLAY buccal graft for extended strictures of spongy urethra. *Urologia*. 2018;(1):84–90. (In Russ.) DOI: 10.18565/urology.2018.1.84-90
11. Selim M, Salem S, Elsherif E, et al. Outcome of staged buccal mucosal graft for repair of long segment anterior urethral stricture. *BMC Urol*. 2019;19(1):38. DOI: 10.1186/s12894-019-0466-4
12. Jasionowska S, Brunckhorst O, Rees RW, et al. Redo-urethroplasty for the management of recurrent urethral strictures in males: a systematic review. *World J Urol*. 2019;37(9):1801–1815. DOI: 10.1007/s00345-019-02709-7
13. Johanson B. The reconstruction in stenosis of the male urethra. *Z Urol*. 1953;46(6):361–375.
14. Turner-Warwick R. The repair of urethral strictures in the region of the membranous urethra. *J Urol*. 1968;100(3):303–314. DOI: 10.1016/s0022-5347(17)62525-4
15. Gil-Vernet JM. A treatment of traumatic and inflammatory stenoses of the posterior urethra. New method of urethroplasty. *J Urol Nephrol (Paris)*. 1966;72(1):97–108. (In French).
16. Blandy JP, Singh M, Tresidder GC. Urethroplasty by scrotal flap for long urethral strictures. *Br J Urol*. 1968;40(3):261–267. DOI: 10.1111/j.1464-410x.1968.tb09886.x
17. Schreiter F. Mesh-graft urethroplasty: our experience with a new procedure. *Eur Urol*. 1984;10(5):338–344. DOI: 10.1159/000463824
18. Carr LK, MacDiarmid SA, Webster GD. Treatment of complex anterior urethral stricture disease with mesh graft urethroplasty. *J Urol*. 1997;157(1):104–108. DOI: 10.1016/S0022-5347(01)65298-4
19. Bracka A. A versatile two-stage hypospadias repair. *Br J Plast Surg*. 1995;48(6):345–352. DOI: 10.1016/s0007-1226(95)90023-3
20. Palminteri E, Lazzeri M, Guazzoni G, et al. New 2-stage buccal mucosal graft urethroplasty. *J Urol*. 2002;167(1):130–132. DOI: 10.1016/S0022-5347(05)65397-9
21. Kulkarni SB, Joglekar OV, Alkandari M, Joshi PM. Algorithm for the management of anterior urethral strictures. *Turk J Urol*. 2018;44(3):195–197. DOI: 10.5152/tud.2018.76429
22. Andrich DE, Greenwell TJ, Mundy AR. The problems of penile urethroplasty with particular reference to 2-stage reconstructions. *J Urol*. 2003;170(1):87–89. DOI: 10.1097/01.ju.0000069721.20193.fd
23. Barbagli G, De Angelis M, Palminteri E, Lazzeri M. Failed hypospadias repair presenting in adults. *Eur Urol*. 2006;49(5):887–894. DOI: 10.1016/j.eururo.2006.01.027
24. Kozinn SI, Harty NJ, Zinman L, Buckley JC. Management of complex anterior urethral strictures with multistage buccal mucosa graft reconstruction. *Urology*. 2013;82(3):718–722. DOI: 10.1016/j.urology.2013.03.081
25. Mori RL, Angermeier KW. Staged urethroplasty in the management of complex anterior urethral stricture disease. *Transl Androl Urol*. 2015;4(1):29–34. DOI: 10.3978/j.issn.2223-4683.2015.01.10
26. Glukhov VP, Ilyash AV, Mitusov VV, et al. Treatment of patients with anterior urethral strictures: the role of perineal urethrostomy. *Urology Herald*. 2022;10(2):87–98. (In Russ.) DOI: 10.21886/2308-6424-2022-10-2-87-98

## СПИСОК ЛИТЕРАТУРЫ

1. Гончаров Н.А., Кузнецов А.А., Морозов Е.А., Киселева А.А. Результаты хирургического лечения непротяженных стриктур бульбозного отдела уретры // Вестник урологии. 2021. Т. 9, № 1. С. 32–38. DOI: 10.21886/2308-6424-2021-9-1-32-38
2. Катиров М.И., Алибеков М.М., Магомедов З.М., и др. Одноэтапная буккальная двухлоскутная уретропластика по технике Kulkarni при протяженных стриктурах передней уретры // Вестник урологии. 2020. Т. 8, № 4. С. 44–52. DOI: 10.21886/2308-6424-2020-8-4-44-52
3. Строчкин А.В., Образцов К.О., Рагузин А.А. Протяженные стриктуры уретры — опыт заместительных уретропластик // Репродуктивное здоровье. Восточная Европа. 2019. Т. 9, № 5. С. 628–636.
4. Furr J.R., Wisenbaugh E.S., Gelman J. Long-term outcomes for 2-stage urethroplasty: an analysis of risk factors for urethral stricture recurrence // *World J Urol*. 2021. Vol. 39, No. 10. P. 3903–3911. DOI: 10.1007/s00345-021-03676-8
5. Коган М.И., Глухов В.П., Ильяш А.В., и др. Сложные стриктуры спонгиозной уретры с многоэтапным лечением: прогнозирование риска рецидива // Экспериментальная и клиническая урология. 2022. Т. 15, № 1. С. 136–141. DOI: 10.29188/2222-8543-2022-15-1-136-141
6. Mehra A., Djaladat H., Salem S., et al. Outcome of buccal mucosal graft urethroplasty for long and repeated stricture repair // *Urology*. 2007. Vol. 69, No. 1. P. 17–21; discussion 21. DOI: 10.1016/j.urology.2006.09.069
7. Котов С.В. Результаты многоэтапной (заместительной) уретропластики // Экспериментальная и клиническая урология. 2015. Т. 8, № 4. С. 60–66.
8. Joshi P.M., Barbagli G., Batra V., et al. A novel composite two-stage urethroplasty for complex penile strictures: A multicenter experience // *Indian J Urol*. 2017. Vol. 33, No. 2. P. 155–158. DOI: 10.4103/0970-1591.203426
9. Глухов В.П., Ильяш А.В., Митусов В.В., и др. Клинические особенности стриктур спонгиозного сегмента уретры, подлежащих многоэтапной уретропластике или постоянной уретростомии // Экспериментальная и клиническая урология. 2021. Т. 14, № 3. С. 156–163. DOI: 10.29188/2222-8543-2021-14-3-156-163



10. Коган М.И., Глухов В.П., Митусов В.В., и др. Сравнительный анализ одно- и двухэтапной аугментационной дорсальной inlay-пластики буккальным графтом протяженных стриктур спонгиозной уретры // Урология. 2018. № 1. С. 84–90. DOI: 10.18565/urology.2018.1.84-90
11. Selim M., Salem S., Elsherif E., et al. Outcome of staged buccal mucosal graft for repair of long segment anterior urethral stricture // BMC Urol. 2019. Vol. 19, No. 1. ID38. DOI: 10.1186/s12894-019-0466-4
12. Jasionowska S., Brunckhorst O., Rees R.W., et al. Redo-urethroplasty for the management of recurrent urethral strictures in males: a systematic review // World J Urol. 2019. Vol. 37, No. 9. P. 1801–1815. DOI: 10.1007/s00345-019-02709-7
13. Johanson B. Die Rekonstruktion der männlichen Urethra bei Strikturen // Z Urol. 1953. Vol. 46, No. 6. P. 361–375.
14. Turner-Warwick R. The repair of urethral strictures in the region of the membranous urethra // J Urol. 1968. Vol. 100, No. 3. P. 303–314. DOI: 10.1016/s0022-5347(17)62525-4
15. Gil-Vernet J.M. Un traitement des sténoses traumatiques et inflammatoires de l'urètre postérieur. Nouvelle méthode d'urétroplastie // J Urol Nephrol (Paris). 1966. Vol. 72, No. 1. P. 97–108.
16. Blandy J.P., Singh M., Tresidder G.C. Urethroplasty by scrotal flap for long urethral strictures // Br J Urol. 1968. Vol. 40, No. 3. P. 261–267. DOI: 10.1111/j.1464-410x.1968.tb09886.x
17. Schreiter F. Mesh-graft urethroplasty: our experience with a new procedure // Eur Urol. 1984. Vol. 10, No. 5. P. 338–344. DOI: 10.1159/000463824
18. Carr L.K., MacDiarmid S.A., Webster G.D. Treatment of complex anterior urethral stricture disease with mesh graft urethroplasty // J Urol. 1997. Vol. 157, No. 1. P. 104–108. DOI: 10.1016/S0022-5347(01)65298-4
19. Bracka A. A versatile two-stage hypospadias repair // Br J Plast Surg. 1995. Vol. 48, No. 6. P. 345–352. DOI: 10.1016/s0007-1226(95)90023-3
20. Palminteri E., Lazzeri M., Guazzoni G., et al. New 2-stage buccal mucosal graft urethroplasty // J Urol. 2002. Vol. 167, No. 1. P. 130–132. DOI: 10.1016/S0022-5347(05)65397-9
21. Kulkarni S.B., Joglekar O.V., Alkandari M., Joshi P.M. Algorithm for the management of anterior urethral strictures // Turk J Urol. 2018. Vol. 44, No. 3. P. 195–197. DOI: 10.5152/tud.2018.76429
22. Andrich D.E., Greenwell T.J., Mundy A.R. The problems of penile urethroplasty with particular reference to 2-stage reconstructions // J Urol. 2003. Vol. 170, No. 1. P. 87–89. DOI: 10.1097/01.ju.0000069721.20193.fd
23. Barbagli G., De Angelis M., Palminteri E., Lazzeri M. Failed hypospadias repair presenting in adults // Eur Urol. 2006. Vol. 49, No. 5. P. 887–894; discussion 895. DOI: 10.1016/j.eururo.2006.01.027
24. Kozinn S.I., Harty N.J., Zinman L., Buckley J.C. Management of complex anterior urethral strictures with multistage buccal mucosa graft reconstruction // Urology. 2013. Vol. 82, No. 3. P. 718–722. DOI: 10.1016/j.urology.2013.03.081
25. Mori R.L., Angermeier K.W. Staged urethroplasty in the management of complex anterior urethral stricture disease // Transl Androl Urol. 2015. Vol. 4, No. 1. P. 29–34. DOI: 10.3978/j.issn.2223-4683.2015.01.10
26. Глухов В.П., Ильяш А.В., Митусов В.В. и др. Роль перинеальной уретростомии в лечении пациентов со стриктурами спонгиозной уретры // Вестник урологии. 2022. Т. 10, № 2. С. 87–98. DOI: 10.21886/2308-6424-2022-10-2-87-98

## AUTHORS' INFO

**Mikhail I. Kogan**, Dr. Sci. (Med.), Professor, Honored Scientist of the Russian Federation, Head of the Department of Urology and Human Reproductive Health (with Pediatric Urology and Andrology Course); ORCID: <https://orcid.org/0000-0002-1710-0169>; eLibrarySPIN: 6300-3241; Scopus: 7102617447; e-mail: dept\_kogan@mail.ru

**\*Vladimir P. Glukhov**, Cand. Sci. (Med.), Associate Professor of the Department of Urology and Human Reproductive Health (with the Pediatric Urology and Andrology Course); address: 29, Nakhichevansky Lane, Rostov-on-Don, 344022, Russia; ORCID <https://orcid.org/0000-0002-8486-9357>; eLibrarySPIN: 5702-6243; SCOPUS: 7005476242; e-mail: docc.gvp@yandex.ru

\* Corresponding author / Автор, ответственный за переписку

## ОБ АВТОРАХ

**Михаил Иосифович Коган**, д-р мед. наук, профессор, заслуженный деятель науки РФ, заведующий кафедрой урологии и репродуктивного здоровья человека (с курсом детской урологии-андрологии); ORCID: <https://orcid.org/0000-0002-1710-0169>; eLibrary SPIN: 6300-3241; Scopus: 7102617447; e-mail: dept\_kogan@mail.ru

**\*Владимир Павлович Глухов**, канд. мед. наук, доцент кафедры урологии и репродуктивного здоровья человека (с курсом детской урологии-андрологии); адрес: Россия, 344022, Ростов-на-Дону, Нахичеванский пер., д. 29; ORCID: <https://orcid.org/0000-0002-8486-9357>; eLibrary SPIN: 5702-6243; Scopus: 7005476242; e-mail: docc.gvp@yandex.ru

## AUTHORS' INFO

**Anna V. Ilyash**, Cand. Sci. (Med.),

Assistant of the Department of Urology and Human Reproductive Health (with the Pediatric Urology and Andrology Course);  
ORCID: <https://orcid.org/0000-0001-8433-8567>;  
eLibrary SPIN: 2327-3900; Scopus: 57202621468;  
e-mail: [annailyash@yandex.ru](mailto:annailyash@yandex.ru)

**Valeriy V. Mitusov**, Dr. Sci. (Med.),

Professor of the Department of Urology and Human Reproductive Health (with the Pediatric Urology and Andrology Course);  
ORCID: <https://orcid.org/0000-0001-7706-8925>;  
eLibrary SPIN: 6666-2648; Scopus: 6505987316;  
e-mail: [mvv55@list.ru](mailto:mvv55@list.ru)

**Oleg N. Vasilyev**, Dr. Sci. (Med.),

Associate Professor of the Department of Urology and Human Reproductive Health (with the Pediatric Urology and Andrology Course), Head of the Urological Division of the Clinic;  
ORCID: <https://orcid.org/0000-0001-5642-4521>;  
eLibrary SPIN: 8565-4276; Scopus: 57192809448;  
e-mail: [vasilyev\\_on@mail.ru](mailto:vasilyev_on@mail.ru)

## ОБ АВТОРАХ

**Анна Владимировна Ильяш**, канд. мед. наук, ассистент кафедры урологии и репродуктивного здоровья человека (с курсом детской урологии-андрологии);  
ORCID: <https://orcid.org/0000-0001-8433-8567>;  
eLibrary SPIN: 2327-3900; Scopus: 57202621468;  
e-mail: [annailyash@yandex.ru](mailto:annailyash@yandex.ru)

**Валерий Викторович Митусов**, д-р мед. наук, профессор кафедры урологии и репродуктивного здоровья человека (с курсом детской урологии-андрологии);  
ORCID: <https://orcid.org/0000-0001-7706-8925>;  
eLibrary SPIN: 6666-2648; Scopus: 6505987316;  
e-mail: [mvv55@list.ru](mailto:mvv55@list.ru)

**Олег Николаевич Васильев**, д-р мед. наук, доцент кафедры урологии и репродуктивного здоровья человека (с курсом детской урологии-андрологии), заведующий урологическим отделением клиники;  
ORCID: <https://orcid.org/0000-0001-5642-4521>;  
eLibrary SPIN: 8565-4276; Scopus: 57192809448;  
e-mail: [vasilyev\\_on@mail.ru](mailto:vasilyev_on@mail.ru)