

## MORPHOLOGIC FEATURES OF BENIGN PROSTATIC HYPERPLASIA DEPENDING ON THE SIZE OF INTRAVESICAL PROSTATIC PROTRUSION

© G.G. Krivoborodov<sup>1,2</sup>, A.P. Raksha<sup>1,3</sup>, N.S. Efremov<sup>1,2</sup>, A.D. Bolotov<sup>1,2</sup>, T.N. Sotnikova<sup>1,3</sup>

<sup>1</sup>Pirogov Russian National Research Medical University, Moscow, Russia;

<sup>2</sup>Russian Gerontology Clinical Research Center, Moscow, Russia;

<sup>3</sup>City Clinical Hospital No 1 named after N.I. Pirogov, Moscow, Russia

For citation: Krivoborodov GG, Raksha AP, Efremov NS, et al. Morphologic features of benign prostatic hyperplasia depending on the size of intravesical prostatic protrusion. *Urologicheskie vedomosti*. 2017;7(4):17-23. doi: 10.17816/uroved7417-23

Received: 11.10.2017

Accepted: 09.12.2017

⊗ **Relevance.** Benign prostatic hyperplasia (BPH) is characterized by the presence of stromal and glandular hyperplasia in the periurethral and transitional zones. To describe the nature of intravesical growth of prostate tissue, an index of intravesical prostatic protrusion (IPP) was proposed. Clinically, men with an IPP measuring 10 mm or more are less likely to respond to  $\alpha$ 1-blocker therapy and 5 $\alpha$ -reductase inhibitors. Thus, the description of the morphological features of the prostate depending on IPP grade is an actual issue. **Purpose:** to identify features of the morphological structure of the IPP in men with BPH. **Materials and methods.** Surgical treatment of the clinical form of BPH was performed to 30 men. Patients were divided into 2 groups: 1st group had IPP less than 10 mm ( $n = 12$ ) and the 2nd group had IPP 10 mm or more ( $n = 18$ ). In this study we evaluated the age, prostate volume and the value of IPP. The material for morphological investigation was obtained with transurethral resection of the prostate from the IPP zone. For light-optical examination, the preparations were stained with hematoxylin-eosin for routine evaluation of the structure of the prostate gland and for Van Gieson to estimate the proportion of the muscular and fibrous components of the stroma. The quantification of structural indicators was carried out by means of the television image analyzer MEKOS-TS2 in an automatic mode. **Results:** The groups were similar in age and prostate volume. In the group with IPP value of 10 mm or more, the proportion of the stromal component in the IPP zone was  $77.5 \pm 11.0\%$ , the proportion of the glandular component was  $22.5 \pm 11.0\%$ , respectively. In the group of men with IPP less than 10 mm, the proportion of the stromal component in the IPP zone was  $96.0 \pm 1.5\%$ , the proportion of the glandular component was  $4.0 \pm 1.5\%$ , respectively ( $p < 0.05$ ). It was also found that with an increase in IPP there is a tendency to decrease the proportion of the muscular component of the stroma. **Conclusion:** In men with BPH, with an increase in the value of intravesical prostatic protrusion in this zone, a relative increase in the proportion of the glandular component and a decrease in the proportion of the stromal component is proved, as well as a tendency to reduce the proportion of the muscular component of the stroma.

⊗ **Keywords:** benign prostatic hyperplasia; intravesical prostatic protrusion; morphological examination; stroma; muscular component; morphometry.

## МОРФОЛОГИЧЕСКИЕ ОСОБЕННОСТИ ДОБРОКАЧЕСТВЕННОЙ ГИПЕРПЛАЗИИ ПРЕДСТАТЕЛЬНОЙ ЖЕЛЕЗЫ В ЗАВИСИМОСТИ ОТ ВЕЛИЧИНЫ ИНТРАВЕЗИКАЛЬНОЙ ПРОСТАТИЧЕСКОЙ ПРОТРУЗИИ

© Г.Г. Кривобородов<sup>1,2</sup>, А.П. Ракша<sup>1,3</sup>, Н.С. Ефремов<sup>1,2</sup>, А.Д. Болотов<sup>1,2</sup>, Т.Н. Сотникова<sup>1,3</sup>

<sup>1</sup>ФГБОУ ВО «Российский национальный исследовательский медицинский университет им. Н.И. Пирогова» Минздрава России, Москва;

<sup>2</sup>Российский геронтологический научно-клинический центр, Москва;

<sup>3</sup>ГБУЗ «Городская клиническая больница № 1 им. Н.И. Пирогова Департамента здравоохранения г. Москвы»

Для цитирования: Кривобородов Г.Г., Ракша А.П., Ефремов Н.С., и др. Морфологические особенности доброкачественной гиперплазии предстательной железы в зависимости от величины интравезикальной простатической протрузии // Урологические ведомости. – 2017. – Т. 7. – № 4. – С. 17–23. doi: 10.17816/uroved7417-23

Дата поступления: 11.10.2017

Статья принята к печати: 09.12.2017

⊗ **Актуальность.** Доброкачественная гиперплазия предстательной железы (ДГПЖ) характеризуется наличием стромальной и железистой гиперплазии в периуретральных и транзиторных зонах. Для описания характера внутрипузырного роста ткани предстательной железы (ПЖ) был предложен показатель интравезикаль-

ной простатической протрузии (ИПП). Клинически отмечено, что при наличии ИПП размером 10 мм и более пациенты в меньшей степени отвечают на терапию  $\alpha$ 1-адреноблокаторами и ингибиторами 5 $\alpha$ -редуктазы. Таким образом, актуальным вопросом является описание морфологических особенностей предстательной железы при различных клинических показателях ИПП. **Цель:** выявление и оценка особенностей морфологического строения зоны ИПП у мужчин с ДГПЖ. **Материалы и методы.** Оперативное лечение клинической формы ДГПЖ проведено 30 мужчинам. Больные были разделены на две группы: имеющие ИПП менее 10 мм ( $n = 12$ ) и имеющие ИПП 10 мм и более ( $n = 18$ ). В настоящей работе оценивали возраст, объем предстательной железы (ОПЖ) и величину ИПП. Материал для морфологического исследования получали при трансуретральной резекции ПЖ из зоны ИПП. Для светооптического изучения препараты окрашивали гематоксилином и эозином для рутинной оценки структуры ПЖ и по Ван-Гизону для оценки доли мышечного и фиброзного компонентов стромы. Квантификацию структурных показателей осуществляли посредством телевизионного анализатора изображения МЕКОС-Ц2 в автоматическом режиме. **Результаты.** Группы были схожими по возрасту пациентов и ОПЖ. В группе с величиной ИПП 10 мм и более доля стромального компонента в зоне ИПП составила  $77,5 \pm 11,0$  %, доля железистого компонента —  $22,5 \pm 11,0$  %. В группе мужчин с ИПП менее 10 мм доля стромального компонента в зоне ИПП оказалась равной  $96,0 \pm 1,5$  %, доля железистого компонента —  $4,0 \pm 1,5$  % ( $p < 0,05$ ). Также установлено, что с увеличением ИПП имеется тенденция к уменьшению доли мышечного компонента стромы. **Выводы.** У мужчин с ДГПЖ при увеличении показателя интравезикальной простатической протрузии в этой зоне доказано относительное увеличение доли железистого компонента и уменьшение доли стромального компонента, а также тенденция к уменьшению доли мышечного компонента стромы.

🔑 **Ключевые слова:** доброкачественная гиперплазия предстательной железы; интравезикальная простатическая протрузия; морфологическое исследование; строма; мышечный компонент; морфометрия.

## INTRODUCTION

A healthy prostate is composed of approximately 70% glandular tissue and 30% fibromuscular stroma. Accordingly, several men over the age 40 develop benign prostatic hyperplasia (BPH), with the same being observed in approximately 50% and 90% of men by the age of 60 and 85, respectively [1]. Structural changes within the periurethral and transient zones of the prostate have been characterized by hyperplasia of stromal and glandular tissues [2–4]. Moreover, BPH causes bladder outlet obstruction (BOO), which leads to urinary disorders. Subsequently, obstructive lower urinary tract symptoms (LUTS) during BPH have been associated with the so-called static and dynamic components of BOO. The static component is related to mechanical compression of the prostatic urethra by the hyperplastic tissue, whereas the dynamic component is related to smooth muscle spasm in the vesicourethral segment. The first treatment option for LUTS in patients with BPH includes  $\alpha$ 1-adrenergic blockers, because they mediate relaxation of smooth muscles in the prostate and bladder neck, thus decreasing the dynamic component. Moreover, reducing the static component involves the use of 5 $\alpha$ -reductase inhibitors considering that the enzyme 5 $\alpha$ -reductase catalyzes the conversion of testosterone to dihydrotestosterone, which is responsible for stromal growth. In 1985, Japanese researchers introduced a new prostatic ultrasound parameter – in-

travesical prostatic protrusion (IPP) – to evaluate the type of intravesical growth during BPH [5]. Further studies have demonstrated that men with an IPP of 10 mm or greater develop more frequent BOO [6]. Furthermore, patients with high-grade IPP are less likely to respond to conservative therapy with  $\alpha$ 1-adrenergic blockers [7, 8]. Meanwhile, no significant decrease in the IPP grade was observed after a course of 5 $\alpha$ -reductase inhibitors (dutasteride) despite a reduction in prostate volume [9]. Thus, to identify possible reasons underlying the inadequate efficacy of pharmacotherapy for LUTS in patients with an IPP over 10 mm, morphological examination of the prostate tissue is recommended.

The present study *aims* to identify and evaluate morphological characteristics within the IPP zone in men with BPH.

## MATERIALS AND METHODS

Tissue samples for morphological examination were obtained from 30 patients who underwent transurethral resection for BPH between 2015 and 2017. Prior to surgery, the patients received only  $\alpha$ 1-adrenergic blockers and underwent standard urological examination according to the approved clinical guidelines of the Russian Society of Urology [10]. The examination included laboratory testing, a questionnaire (I-PSS), ultrasound examination of the urinary tract (including IPP mea-

surement), and uroflowmetry. All 30 men were diagnosed with a clinical form of BPH that required surgical treatment. Study participants were divided into two groups according to their IPP grade. Group 1 included 12 patients with an IPP of less than 10 mm, whereas group 2 comprised 18 patients with an IPP of 10 mm or greater. Tissue samples for morphological examination were obtained from the IPP zone during transurethral resection of the prostate. The IPP zone was defined as a protrusion of the prostate located within the bladder neck area. Histological slides were stained using hematoxylin and eosin and Van Gieson's staining and then assessed using light microscopy. Light microscopy and densitometry were performed using the MECOS-C2 TV image analyzer and MECOS-VA software. Pathomorphological examination included evaluation of the stromal and glandular components, fibrous tissue, and muscle fibers of the stroma within the IPP zone. Statistical analysis of quantitative results included calculation of mean values, standard deviations, and minimum and maximum values (for normally distributed data). Student's *t*-test was used to determine significant differences among results with the significance level set at  $P < 0.05$ .

## RESULTS

Participants in Groups 1 and 2 had a mean age of  $69.5 \pm 7.7$  years (range: 54–81 years) and  $70 \pm 9.5$  years (range: 56–90 years), respectively.

The mean prostate volume and IPP grade were  $65.3 \pm 19.4$  cm<sup>3</sup> (range: 36.6–98 cm<sup>3</sup>) and  $6.3 \pm 2.1$  mm (range: 2.5–9.1 mm) in Group 1 and  $74.6 \pm 19.6$  cm<sup>3</sup> (range: 46.3–107 cm<sup>3</sup>) and  $15.4 \pm 4.9$  mm (range: 10.3–28 mm) in Group 2, respectively (Table 1).

Morphological examination of prostate tissue samples (hematoxylin and eosin-stained slides) demonstrated the following results. The proportion of the stromal component within the IPP zone was  $96.0\% \pm 1.5\%$  (range: 90%–100%) and  $77.5\% \pm 11.0\%$  (range: 25%–100%) in Groups 1 and 2, respectively (Figure 1). The proportion of the glandular component was  $4.0\% \pm 1.5\%$  (range: 0%–10%) in patients with an IPP of less than 10 mm and  $22.5\% \pm 11.0\%$  (range: 0%–75%) in those with an IPP of 10 mm or greater. Statistical analysis indicated significant differences in the proportion of stromal and glandular components between both groups ( $p = 0.044$ ).

The distribution of muscle and fibrous tissues in the stroma was analyzed in Van Gieson-stained slides. The proportion of muscle tissue within the IPP zone was  $65.5\% \pm 16.9\%$  (range: 1%–90%) and  $56.7 \pm 16.4\%$  (range: 30%–90%) in Groups 1 and 2, respectively (Table 2; Figure 2). However, the difference between both groups was not statistically significant ( $p = 0.45$ ).

## DISCUSSION

BOO, which gradually develops along with prostate enlargement, can lead to LUTS in men. BPH has been known to develop within the periurethral and transient zones of the prostate, appearing as epithelial (glandular) and stromal proliferation due to impaired apoptosis [11]. BPH development requires testicular androgens. The enzyme steroid 5 $\alpha$ -reductase, located on the nuclear membrane, catalyzes the conversion of testosterone to dihydrotestosterone in prostate cells. Dihydrotestosterone binds to specific DNA sites causing increased transcription of androgen-dependent

Table 1

### Mean age, prostate volume, and IPP in patients with BPH

Таблица 1

### Средние значения возраста, объема предстательной железы и интравезикальной простатической протрузии у больных доброкачественной гиперплазией предстательной железы

| Parameter                        | IPP less than 10 mm<br>( <i>n</i> = 12) | IPP of 10 mm or greater<br>( <i>n</i> = 18) |
|----------------------------------|---|---|
| Age, years                       | $69.5 \pm 7.7$<br>(54–81)               | $70 \pm 9.5$<br>(56–90)                     |
| Prostate volume, cm <sup>3</sup> | $65.3 \pm 19.4$<br>(36.6–98)            | $74.6 \pm 19.6$<br>(46.3–107)               |
| IPP, mm                          | $6.3 \pm 2.1$<br>(2.5–9.1)              | $15.4 \pm 4.9$ *<br>(10.3–28)               |

Note: \* significant difference at  $p < 0.05$ .  
BPH, benign prostatic hyperplasia; IPP, intravesical prostatic protrusion

Table 2

## Morphological parameters within the IPP area in patients with BPH

Таблица 2

## Морфологические показатели в зоне интравезикальной простатической протрузии у больных доброкачественной гиперплазией предстательной железы

| Parameter                                  | IPP less than 10 mm<br>(n = 12) | IPP of 10 mm or greater<br>(n = 18) |
|--|---------------------------------|-------------------------------------|
| Stromal component within the IPP area, %   | 96.0 ± 1.5<br>(90–100)          | 77.5 ± 11.0 *<br>(25–100)           |
| Glandular component within the IPP area, % | 4.0 ± 1.5<br>(0–10)             | 22.5 ± 11.0 *<br>(0–75)             |
| Muscle tissue within the IPP area, %       | 65.5 ± 16.9<br>(1–90)           | 56.7 ± 16.4<br>(30–90)              |

Note: \* significant difference at  $p < 0.05$ .  
BPH, benign prostatic hyperplasia; IPP, intravesical prostatic protrusion

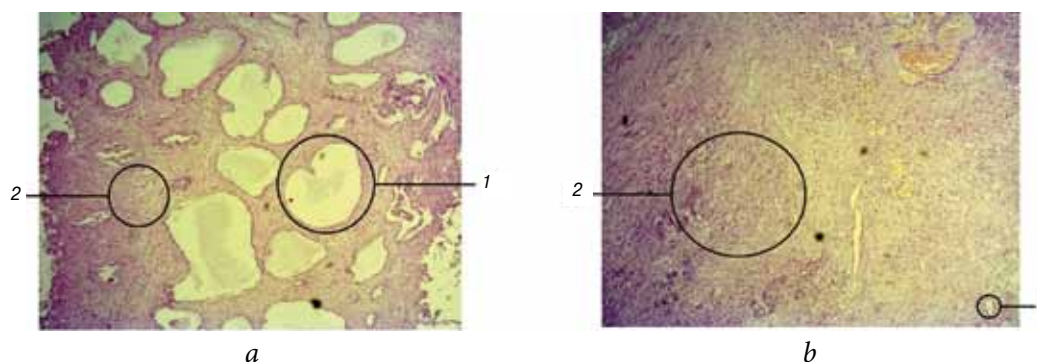


Fig. 1. Morphological image of benign prostatic hyperplasia within the intravesical prostatic protrusion area: *a* – prevalence of the glandular component; *b* – prevalence of the stromal component. 1 – glands, 2 – stroma (hematoxylin and eosin staining, 40× magnification)

Рис. 1. Морфологическая картина доброкачественной гиперплазии предстательной железы в зоне интравезикальной простатической протрузии: *a* — преобладание железистого компонента; *b* — преобладание стромального компонента. 1 — железы, 2 — строма (окраска гематоксилином и эозином, увеличение ×40)

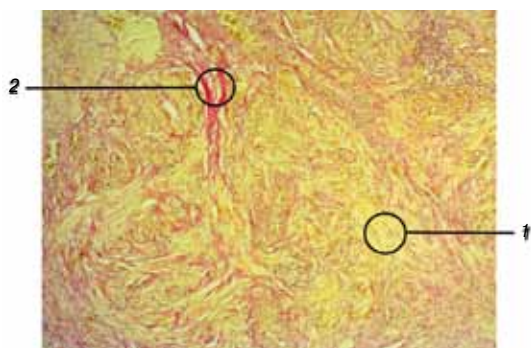


Fig. 2. Morphological image of the stroma within the intravesical prostatic protrusion area (Van Gieson's staining, 40× magnification): 1 – fibrous tissue (yellow), 2 – muscle fibers (red)

Рис. 2. Морфологическая картина стромы в зоне интравезикальной простатической протрузии при окрашивании по Ван-Гизону (увеличение ×40): 1 — фиброзные волокна (окрашены в желтый цвет), 2 — мышечные волокна (окрашены в красный цвет)

genes and, consequently, increased protein synthesis [12]. There are two types of steroid 5 $\alpha$ -reductases encoded by two different genes [13]. The type I isozyme is extraprostatic and is detected primarily in the skin and liver, whereas the type II isozyme is primarily prostatic but can be found in extraprostatic tissues as well. The type II isozyme plays a key role in the growth and development of the prostate, as well as its subsequent progression toward benign hyperplasia [14]. Immunohistochemical studies have shown predominantly stromal expression of 5 $\alpha$ -reductase type II [15]. Thus, stromal cells play a vital role in androgen-dependent prostate enlargement. McNeal et al. demonstrated that the stromal component predominates in the periurethral area during the early stages of BPH. Several authors believe that as BPH progresses, the proportion of stromal tissue decreases, whereas that

of glandular tissue increases. The ratio between such changes, however, varies from one patient to another. Nonetheless, such results are of considerable importance when selecting an optimal treatment strategy for LUTS in patients with BPH.

Pharmacotherapy using uroselective  $\alpha$ 1-blockers (eliminating the dynamic component of BOO by relaxing smooth muscles in the vesicourethral segment) and  $5\alpha$ -reductase inhibitors (decreasing the static component of BOO by reducing adenomatous nodes) has been the first-line therapy for LUTS in patients with BPH. However, treatment outcomes remain difficult to predict. Several researchers suppose that treatment efficacy largely depends on the presence of BOO and bladder contractility. Moreover, we cannot ignore the fact that structural changes in the prostatic tissue at different stages of BPH can predetermine pharmacotherapeutic efficacy. Thus, the present study had been undertaken to assess histological characteristics during BPH. Patients were divided into two groups according to their IPP grade. Group 1 included 12 men with an IPP less than 10 mm, whereas Group 2 comprised 18 men with an IPP of 10 mm or greater. Although participants in Group 2 were older and had slightly greater prostatic volume than those in Group 1, no significant difference in such parameters was observed between both groups. Morphological examination revealed a statistically significant decrease in the proportion of stromal components within the IPP zone of participants from Group 2. Further evaluation of the stromal component (proportion of muscle and fibrous tissues) showed no significant differences between both groups, although a clear downward trend in the number of muscle fibers within the IPP zone was observed in patients with an IPP of 10 mm or greater. Our results are consistent with those of Hirayama et al., who observed a relative increase in the glandular component and a decrease in the stromal component of resected prostate samples as IPP increased [16]. We should also take into account that specimens in the present study were collected after a 6-month course of  $\alpha$ 1-adrenergic blockers. Moreover, men included in the present study did not receive  $5\alpha$ -reductase inhibitors, which may explain the difference in the parameters assessed.

Our findings suggest that patients with an IPP of 10 mm or greater develop expansion of glandular structures and reduction of muscle tissue in the stroma. Moreover, our results can help explain one

of the mechanisms underlying the low pharmacotherapeutic efficiency of  $\alpha$ 1-adrenergic blockers and  $5\alpha$ -reductase inhibitors. The reduction of muscle tissue in the stroma of individuals with an IPP of 10 mm or greater can definitely determine low therapeutic efficacy of  $\alpha$ 1-adrenergic blockers. However, the anatomical features of the intravesical prostatic component could likely be the most significant contributor to urinary disorders in men with an IPP of 10 mm or greater is likely to be made. Several authors believe that the emergence of BOO as BPH progresses largely depends on the elasticity of the prostate pseudocapsule and the fascia surrounding it. High elasticity is often associated with lateral prostate enlargement, whereas low elasticity causes prostate enlargement toward the bladder. The absence of fascia surrounding the bladder neck area facilitates prostate base prolapse and pronounced IPP development. In patients with high-grade IPP, the intravesical portion of the prostate has been suggested to experience radial compression due to the intravesical pressure generated during urination. This leads to the narrowing of the prostatic urethra and emergence of the ball valve effect, which leads to the development of BOO [17].

We also note that the efficacy of conservative therapy in patients with various IPP grades depends on multiple anatomical and morphological factors, both dynamic and functional. Consequently, explaining all BPH-associated urinary disorders through a single mechanism may seem impossible. Nonetheless, exploring individual components that play a significant role in these disorders may provide a better understanding of the overall picture, which should ultimately lead to improved treatment of men with BPH.

## CONCLUSION

Our findings indicated that among patients with BPH, those who had high-grade IPP showed a significant decrease in the proportion of the stromal component and an increase in the proportion of the glandular component. Moreover, a tendency toward decreased muscle tissue in the stroma had been observed. The results support clinical data suggesting the low therapeutic efficacy of  $\alpha$ 1-blockers, as well as controversial data regarding the possibility of IPP reduction in response to  $5\alpha$ -reductase inhibitors in men with an IPP of 10 mm or greater.

## REFERENCES

1. Berry SJ, Coffey DS, Walsh PC, Ewing LL. The development of human benign prostatic hyperplasia with age.

- J Urol.* 1984;132(3):474-479. doi: 10.1016/s0022-5347(17)49698-4.
2. McNeal JE. Origin and evolution of benign prostatic enlargement. *Invest Urol.* 1978;15(4):340-345 (<https://www.ncbi.nlm.nih.gov/pubmed/75197>).
  3. McNeal J. Pathology of benign prostatic hyperplasia. Insight into etiology. *Urol Clin North Am.* 1990;17(3):477-486.
  4. Roehrborn CG. Pathology of benign prostatic hyperplasia. *Int J Impot Res.* 2008;20(Suppl. 3): S11-S18. doi: 10.1038/ijir.2008.55.
  5. Ohnuki T, Kurokawa K, Katoh N, et al. Transrectal longitudinal ultrasonography of the prostate by electronic linear scanning. *Hinyokika Kyo.* 1987;33(9):1385-1388 (In Japanese).
  6. Кривобородов Г.Г., Ефремов Н.С., Болотов А.Д. Ультразвуковые показатели предстательной железы, мочевого пузыря и данные урофлоуметрии в диагностике инфравезикальной обструкции у мужчин с доброкачественной гиперплазией предстательной железы // Урология. – 2017. – № 5. – С. 9–14. [Krivoborodov GG, Efremov NS, Bolotov AD. Ultrasound indicators of the prostate, urinary bladder and uroflowmetry parameters in the diagnosis of infravesical obstruction in men with benign prostatic hyperplasia. *Urologija.* 2017;(5):9-14. (In Russ.)]. doi: <https://dx.doi.org/10.18565/urology.2017.5.9-14>.
  7. Kalkanli A, Tandogdu Z, Aydin M, et al. Intravesical Prostatic Protrusion: A Potential Marker of Alpha-blocker Treatment Success in Patients With Benign Prostatic Enlargement. *Urology.* 2016;88:161-165. doi: 10.1016/j.urology.2015.11.029.
  8. Park HY, Lee JY, Park SY, et al. Efficacy of alpha blocker treatment according to the degree of intravesical prostatic protrusion detected by transrectal ultrasonography in patients with benign prostatic hyperplasia. *Korean J Urol.* 2012;53(2):92-97. doi: 10.4111/kju.2012.53.2.92.
  9. Yoshida T, Kinoshita H, Yoshida K, et al. Intravesical Prostatic Protrusion as a Predicting Factor for the Adverse Clinical Outcome in Patients With Symptomatic Benign Prostatic Enlargement Treated With Dutasteride. *Urology.* 2016;91:154-157. doi: 10.1016/j.urology.2016.01.009.
  10. Урология. Российские клинические рекомендации / Под ред. Ю.Г. Аляева, П.В. Глыбочко, Д.Ю. Пушкаря. – М.: ГЭОТАР-Медиа, 2016. – 496 с. [Urologija. Rossijskie klinicheskie rekomendacii. Ed by Ju.G. Aljaev, P.V. Glybochko, D.Ju. Pushkar'. Moscow: GEOTAR-Media; 2016. 496 p. (In Russ.)]
  11. Isaacs J. Antagonistic effect of androgen on prostatic cell death. *Prostate.* 1984;5(5):545-557. doi: 10.1002/pros.2990050510.
  12. Andriole G, Bruchofsky N, Chung LW, et al. Dihydrotestosterone and the prostate: the scientific rationale for 5alpha-reductase inhibitors in the treatment of benign prostatic hyperplasia. *J Urol.* 2004;172(4 Pt 1):1399-1403. doi: 10.1097/01.ju.0000139539.94828.29.
  13. Russell DW, Wilson JD. Steroid 5 alpha-reductase: two genes/two enzymes. *Ann Rev Biochem.* 1994;63(1):25-61. doi: 10.1146/annurev.biochem.63.1.25.
  14. Carson C, Rittmaster RR. The role of dihydrotestosterone in benign prostatic hyperplasia. *Urology.* 2003;61(4 Suppl. 1):2-7. doi: 10.1016/s0090-4295(03)00045-1.
  15. Thigpen AE, Silver RI, Guileyardo JM, et al. Tissue distribution and ontogeny of steroid 5 alpha-reductase isozyme expression. *J Clin Invest.* 1993;92(2):903-910. doi: 10.1172/JCI116665.
  16. Hirayama K, Masui K, Hamada A, et al. Evaluation of Intravesical Prostatic Protrusion as a Predictor of Dutasteride-Resistant Lower Urinary Tract Symptoms/Benign Prostatic Enlargement With a High Likelihood of Surgical Intervention. *Urology.* 2015;86(3):565-569. doi: 10.1016/j.urology.2015.05.021.
  17. Zheng J, Pan J, Qin Y, et al. Role for intravesical prostatic protrusion in lower urinary tract symptom: a fluid structural interaction analysis study. *BMC Urol.* 2015;15(1):86. doi: 10.1186/s12894-015-0081-y.

#### Information about the authors:

**Grigorij G. Krivoborodov** – doctor of medical science, professor of Department of urology and andrology, Pirogov Russian National Research Medical University; head of urological unit, Russian Gerontology Clinical Research Center, Moscow, Russia. E-mail: dr.krivoborodov@yandex.ru.

**Aleksandr P. Raksha** – doctor of medical science, professor of department of pathological anatomy and clinical pathological anatomy, Pirogov Russian National Research Medical University; head of pathoanatomical unit, City Clinical Hospital No 1 named after N.I. Pirogov, Moscow, Russia. E-mail: rakshadoc@yandex.ru.

#### Сведения об авторах:

**Григорий Георгиевич Кривобородов** – д-р мед. наук, профессор, кафедра урологии и андрологии, ФГБОУ ВО «Российский национальный исследовательский медицинский университет им. Н.И. Пирогова» Минздрава России; заведующий, отделение урологии, ОСП «Российский геронтологический научно-клинический центр», Москва. E-mail: dr.krivoborodov@yandex.ru.

**Александр Петрович Ракша** – д-р мед. наук, профессор, кафедра патологической анатомии и клинической патологической анатомии, ФГБОУ ВО «Российский национальный исследовательский медицинский университет им. Н.И. Пирогова» Минздрава России; заведующий, патологоанатомическое отделение, ГБУЗ «Городская клиническая больница № 1 им. Н.И. Пирогова Департамента здравоохранения города Москвы», Москва. E-mail: rakshadoc@yandex.ru.

*Information about the authors:*

**Nikolaj S. Efremov** – candidate of medical science, associate professor of department of urology and andrology, Pirogov Russian National Research Medical University; urologist, Russian Gerontology Clinical Research Center, Moscow, Russia. E-mail: nefr@yandex.ru.

**Andrej D. Bolotov** – postgraduate of department of urology and andrology, Pirogov Russian National Research Medical University; urologist, Russian Gerontology Clinical Research Center, Moscow. E-mail: adbolotov@gmail.com.

**Tat'jana N. Sotnikova** – assistant professor of department of pathological anatomy and clinical pathological anatomy, Pirogov Russian National Research Medical University; pathologist, City Clinical Hospital No 1 named after N.I. Pirogov, Moscow. E-mail: docsotnikova@mail.ru.

*Сведения об авторах:*

**Николай Сергеевич Ефремов** – канд. мед. наук, доцент, кафедра урологии и андрологии, ФГБОУ ВО «Российский национальный исследовательский медицинский университет им. Н.И. Пирогова» Минздрава России; врач-уролог, ОСП «Российский геронтологический научно-клинический центр», Москва. E-mail: nefr@yandex.ru.

**Андрей Дмитриевич Болотов** – аспирант, кафедра урологии и андрологии, ФГБОУ ВО «Российский национальный исследовательский медицинский университет им. Н.И. Пирогова» Минздрава России; врач-уролог, ОСП «Российский геронтологический научно-клинический центр», Москва. E-mail: adbolotov@gmail.com.

**Татьяна Николаевна Сотникова** – ассистент, кафедра патологической анатомии и клинической патологической анатомии, ФГБОУ ВО «Российский национальный исследовательский медицинский университет им. Н.И. Пирогова» Минздрава России; врач-патологоанатом, ГБУЗ «Городская клиническая больница № 1 им. Н.И. Пирогова Департамента здравоохранения города Москвы», Москва. E-mail: docsotnikova@mail.ru.